



A continuing medical education activity provided by Evolve Medical Education LLC.
This activity is supported by an unrestricted educational grant from Bausch + Lomb.

A large, abstract graphic on the left side of the page consists of numerous overlapping, sharp, triangular shapes in shades of purple, magenta, and orange, radiating from the left edge towards the center.

The Expanding Armamentarium: The Latest in MGD-DED Diagnostics and Treatment

Distributed with

CRST
Cataract & Refractive Surgery Today

CRST GLOBAL
Cataract & Refractive Surgery Today | EUROPE EDITION

FACULTY

Alice T. Epitropoulos, MD, FACS, Program Chair | Michael Greenwood, MD | John D. Sheppard, MD, MMSc, FACS

YoungMD>Connect

The Expanding Armamentarium: The Latest in MGD-DED Diagnostics and Treatment

Faculty

Alice T. Epitropoulos, MD, FACS

Program Chair
Private Practice, Ophthalmic Surgeons &
Consultants of Ohio
The Eye Center of Columbus
Clinical Associate Professor
The Ohio State University
Wexner Medical Center
Columbus, OH

Michael Greenwood, MD

Cataract, Refractive, Corneal, and
Glaucoma Surgeon
Vance Thompson Vision
Fargo, ND

John D. Sheppard, MD, MMSc, FACS

Founding Partner, Virginia Eye Consultants
Professor of Ophthalmology, Microbiology,
Molecular Biology, Ophthalmology
Residency Research Director
Eastern Virginia Medical School
Division Medical Director, EyeCare Partners
Medical Director
Lions Medical Eye Bank of Eastern Virginia
Norfolk, VA

Content Source

This continuing medical education (CME) activity captures content from a live satellite symposium.

Activity Description

This supplement summarizes a live panel discussion about meibomian gland dysfunction, its interaction with dry eye disease, and the

latest data on new and emerging treatments for ocular surface disease. It was recorded prior to the approval of perfluorohexyloctane ophthalmic solution (formerly known as NOV03) and lotilaner ophthalmic solution 0.25% (formerly known as TP-03).

Target Audience

This certified CME activity is designed for ophthalmologists.

Learning Objectives

Upon completion of this activity, the participant should be able to:

- **Diagnose** dry eye disease (DED) by subtype based on signs and symptoms
- **Articulate** how meibomian gland dysfunction (MGD) interacts with DED
- **Summarize** the latest data on treatments for MGD
- **Compare** the pipeline agents nearest to regulatory approval and **explain** their mechanisms of action

Grantor Statement

This activity is supported by an unrestricted educational grant from Bausch + Lomb.

Accreditation Statement

Evolve Medical Education LLC (Evolve) is accredited by the Accreditation Council for Continuing Medical Education (ACCME) to provide continuing medical education for physicians.

Credit Designation Statement

Evolve designates this enduring material for a maximum of 1.0 AMA PRA Category

1 Credit™. Physicians should claim only the credit commensurate with the extent of their participation in the activity.

The American Medical Association has an agreement of mutual recognition of Continuing Medical Education (CME) credits with the European Union of Medical Specialists (UEMS), the accreditation body for European countries.

Physicians interested in converting AMA PRA Category 1 Credit™ to UEMS-European Accreditation Council for Continuing Medical Education CME credits (ECMEC®s) should contact the UEMS at [mutualrecognition@uems.eu](mailto:mualrecognition@uems.eu).

To Obtain Credit

To obtain credit for this activity, you must read the activity in its entirety and complete the Pretest/Posttest/Activity Evaluation/Satisfaction Measures Form, which consists of a series of multiple-choice questions. To answer these questions online and receive real-time results, go to <https://evolvemed.com/course/2313-sup>. Upon completing the activity and self-assessment test, your certificate will be available. Alternatively, please complete the Posttest/Activity Evaluation/Satisfaction Form and mail or fax to Evolve Medical Education LLC, 353 West Lancaster Avenue, Second Floor, Wayne, PA 19087; Fax: (215) 933-3950.

Disclosure Policy

It is the policy of Evolve that faculty and

other individuals who are in the position to control the content of this activity disclose any real or apparent financial relationships relating to the topics of this educational activity. Evolve has full policies in place that will identify and mitigate all financial relationships prior to this educational activity.

The following faculty/staff members have the following financial relationships with ineligible companies:

Alice T. Epitropoulos, MD, FACS, has had a financial relationship or affiliation with the following ineligible companies in the form of *Advisor*: Oyster Point Pharma. *Consultant*: Aldeyra, Allergan/AbbVie, Bausch + Lomb, BioTissue, Bruder, Dompé, EyePoint Pharmaceuticals, Imprimis, Johnson & Johnson Vision, Novartis, Ocular Therapeutix, Physician Recommended Nutraceuticals, Sight Sciences, Sun Pharma, Tarsus, and Visus. *Grant/Research Support*: AimMax Therapeutics, Bausch + Lomb, and Sylentis. *Primary Investigator*: Third phase 3 FDA clinical trial for Dextenza. *Property Right/Patent Holder*: Hilco. *Speaker's Bureau*: Allergan/AbbVie, Bausch + Lomb, Johnson & Johnson Vision, Kala Pharmaceuticals, Novartis, Ocular Therapeutix, and Sun Pharma.

Michael Greenwood, MD, has had a financial relationship or affiliation with the following ineligible companies in the form of *Consultant*: Aerie Pharmaceuticals, Allergan, BVI, Carl Zeiss Meditec, Equinox, Imprimis, Ivantis, New World Medical, Nevakar, and Ocular Therapeutix. *Grant/Research Support*: Alcon, Glaukos, Ocular Therapeutix, Sight Sciences, and STAAR. *Speaker's Bureau*: Aerie Pharmaceuticals, Alcon, Allergan, Carl Zeiss Meditec, Equinox, Glaukos, Imprimis, Johnson & Johnson Vision, New World Medical, Ocular Therapeutix, Sight Sciences, STAAR, and Valeant. *Stock/Shareholder*: Equinox.

John D. Sheppard, MD, MMSc, FACS, has had a financial relationship or affiliation with the following ineligible companies in the form of *Consultant*: Aerie Pharmaceuticals, Alcon, Aldeyra Therapeutics, Allergan, Allysta Pharmaceuticals, Avedro, Bausch + Lomb, BioTissue, Bruder Healthcare, Clementia Pharmaceuticals, Dompé, EyeGate, EyePoint Pharmaceuticals, Glaukos, Hovione, Johnson & Johnson Vision, Kala Pharmaceuticals, Laci Sciences, LayerBio, Mallinckrodt, Novaliq, Novartis, Noveome Biotherapeutics, Ocular Therapeutix, Omeros, Oyster Point Pharma, Quidel, ScienceBased Health, Shire, Sun Pharma, Takeda Pharmaceuticals USA, TearLab, Tear Solutions, and TopiVert. *Grant/Research Support*: Alcon, Bausch + Lomb, Chengdu Kanghong Biotechnology, Clearside Biomedical, EyeGate, Hovione, Kala Pharmaceuticals, Mallinckrodt, and Visus Pharmaceuticals. *Speaker's Bureau*: Alcon, Bausch + Lomb, BioTissue, Dompé, and Mallinckrodt. *Stock/Shareholder*: Claris Bio, Doctors Optimal Formula, Eyedetec Medical, EyeRxResearch, Eyevance, Lacrisciences, LayerBio, Noveome Biotherapeutics, Oyster Point Pharma, ProVision Network, Rapid Pathogen Screening, Scientifically Developed Solutions, Strathspey Crowne, and TearLab.

Editorial Support Disclosures

The Evolve and staff, planners, reviewer, and writers have no financial relationships with ineligible companies.

Off-Label Statement

This educational activity may contain discussion of published and/or investigational uses of agents that are not indicated by the FDA. The opinions expressed in the educational activity are those of the faculty. Please refer to the official prescribing information for each product for discussion of approved indications, contraindications, and warnings.

Disclaimer

The views and opinions expressed in this educational activity are those of the faculty and do not necessarily represent the views of Evolve, *Cataract & Refractive Surgery Today (CRST)*, *CRST Global: Europe Edition*, YoungMD Connect: *Bookmarked*, or Bausch + Lomb.

This activity is designed for educational purposes. Participants have a responsibility to utilize this information to enhance their professional development to improve patient outcomes. Conclusions drawn by the participants should be derived from careful consideration of all available scientific information. The participant should use his/her clinical judgment, knowledge, experience, and diagnostic decision-making before applying any information, whether provided here or by others, for any professional use.

Digital Edition

To view the online version of the material, log in to your Evolve account and go to <https://evolvedmed.com/course/2313-supp> or scan the QR code with your smartphone's camera.

To view the videos associated with this supplement, log in to your Evolve account and go to: https://www.evolvedmed.com/course-collection/2313_ded-origin-story-mgd



PRETEST QUESTIONS

Please complete prior to accessing the material and submit with Posttest/Activity Evaluation/Satisfaction Measures for credit.

- 1. Please rate your confidence in your ability to diagnose and treat dry eye disease (DED) associated with meibomian gland dysfunction (MGD; based on a scale of 1 to 5, with 1 being not at all confident and 5 being extremely confident).**
 - A. 1
 - B. 2
 - C. 3
 - D. 4
 - E. 5
- 2. All of the following represent signs and symptoms of DED EXCEPT:**
 - A. Redness/itching/watery eyes
 - B. Low tear osmolarity
 - C. High tear osmolarity
 - D. Elevated MMP-9 tear level
- 3. A 65-year-old man presents to your clinic for cataract evaluation. He notes blurry vision bilaterally that fluctuates daily as well as increased matting on his eyelids in the morning. Slit lamp exam reveals diffuse corneal staining and meibography shows gland duct dilation and dropout. All of the following statements are true about this patient EXCEPT:**
 - A. This patient has DED that should be optimized before cataract surgery
 - B. This patient has MGD
 - C. Most precataract surgical patients do not have MGD, so this patient likely has aqueous deficiency DED
 - D. Lens calculations obtained on this patient are likely erroneous due to his DED
- 4. Which of the following MGD treatment option modulates the immune response to alleviate DED?**
 - A. Preservative-free artificial tear drops
 - B. Lifitegrast
 - C. Thermal pulsation
 - D. Meibomian gland expression
- 5. A 65-year-old woman presents to your office for evaluation of eye discomfort. She notes frequent red/itchy eyes, with increased tearing daily. In-office testing reveals high tear osmolarity and significant meibomian gland inspissation. All of the following represent evidence-based treatment options for this patient's MGD EXCEPT:**
 - A. Azithromycin treatment
 - B. In-office treatment with thermal pulsation, microblepharoexfoliation, or intense pulsed light therapy
 - C. Immunomodulator therapy with topical cyclosporine A
 - D. IV steroid therapy
- 6. Which of the following MGD therapeutics can treat *Demodex* mites?**
 - A. AZR-MD-001
 - B. TP-03
 - C. Reproxalap
 - D. NOV03

Dry Eye Disease: Epidemiology and Diagnostics

MICHAEL GREENWOOD, MD

Despite the number of innovations that have occurred over the past several years, dry eye disease (DED) remains one of the most undertreated and underdiagnosed ophthalmic conditions.¹ Approximately 6.8% (16.4 million) of US adults were diagnosed with DED in 2013, and 2.5% (6 million) of US patients were undiagnosed with DED but reported experience with it.² Per these estimates, more than 25% of patients with DED in the United States were undiagnosed in 2013.

Global and regional rates of DED are sometimes higher than US rates. A 2021 study estimated a global prevalence of DED of 11.6%, with the highest prevalence found in Africa (47.9%) and the lowest found in North America (4.6%).³ DED prevalence rates in adult populations have been estimated at 11.0% in Spain,⁴ 18.3% in Iran,⁵ 20.0% in the United Kingdom,⁶ and 20.0% in South Korea.⁷ (Prevalence rates are, in part, a function of the definition of DED used by respective researchers, as the TFOS DEWS II authors observed.⁸)

Approximately 50% of DED is exclusively evaporative in nature, with 36% of DED arising from both evaporative and aqueous-deficient sources, and the remaining 14% of DED being exclusively aqueous-deficient disease.⁹⁻¹¹ Meibomian gland dysfunction (MGD) has been identified as a major contributor to evaporative DED.¹⁰⁻¹⁴ Given that approximately 86% of DED is at least somewhat based on evaporative disease, MGD is of particular interest to eye care providers treating DED.

A 2022 meta-analysis of 13 studies found that the prevalence of DED was 7.8% in patients aged at least 68 years,¹⁵ suggesting that many of the patients we see in our clinics for age-related conditions such as cataract and glaucoma may have comorbid DED. MGD, in particular, is found at high rates among cataract patients in the presurgical period (52%)¹⁶ and among glaucoma patients on long-term drop regimens (80%).¹⁷ It has also been noted that meibum quality and abnormality of lid margins are linked with longer duration of soft contact lens wear.¹⁸

Identifying DED and/or MGD in clinical settings is difficult, especially when patients are presenting with other ocular conditions. DED symptoms range from itchy, watery eyes to ocular strain and pain. Patients with blurred or fluctuating vision (two common symptom of DED) often think a new refraction is needed, when in fact DED treatment may be more appropriate. Further complicating diagnosis and detection is that DED patients are often asymptomatic and report no issues even though they have clinical signs of DED. Moreover, signs of DED may be inconsistent: among patients with DED, only 50% of them show corneal staining despite showing other clinical signs of DED.¹⁹

Treating DED in patients who are scheduled to undergo cataract surgery is key to successful outcomes. When DED is treated effectively, presurgical measurements (ie, topography, biometry, keratometry) are more accurate, inevitably leading to a higher percentage of satisfied patients. Given the importance of treating DED in the presurgical period and the value of understanding whether MGD is a source of DED, we must seek to master various methods of detecting these conditions.

DIAGNOSTICS IN DED AND MGD

Symptoms alone are not sufficient for diagnosing DED. Clinical tests that can aid in accurate diagnosis of DED and MGD include osmolarity testing, identification of inflammatory markers in tear samples, ocular surface interferometry, and analysis of meibomian gland anatomy.

Osmolarity Testing

Osmolarity testing offers several advantages (Figure 1). Specifically, it can be done in the office, takes seconds to perform, may be executed by a technician, is relatively noninvasive, and may be performed 15 minutes after administering topical anesthetic and/or dilating drops. (Note that other drops, including artificial tears, may affect osmolarity for up to 3 hours after administration.)

To perform an osmolarity evaluation, the user places the tip of a device loaded with a testing chip onto a patient's ocular surface. A volume of 50 nL of fluid from the tear meniscus is collected, and osmolarity is measured in a couple of seconds. Tear osmolarity below 310 mOsms/L is considered healthy.²⁰ If osmolarity measurements differ between eyes by at least 10 mOsms/L, further evaluation is warranted. Patients with DED often have highly variable osmolarity scores in a single session as a result of their tear film's lack of homeostasis. If multiple osmolarity tests performed in a single exam yield inconsistent results, DED is likely present.

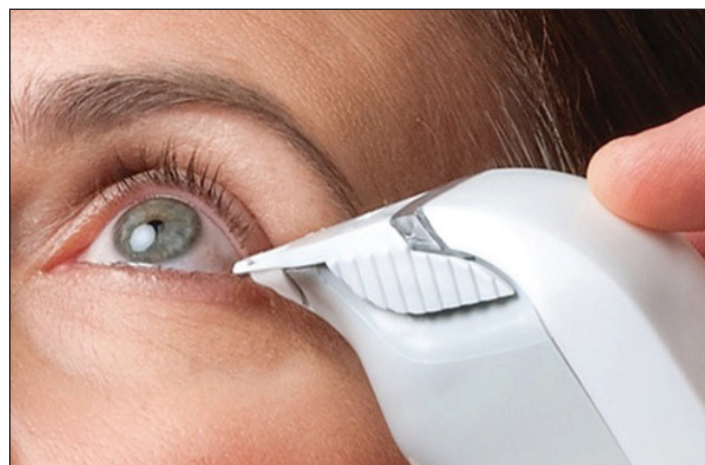

Figure 1. Osmolarity testing is easy to perform and takes only seconds to gather a small tear sample. Technicians are capable of performing this test, and the results of osmolarity testing are easy to understand.

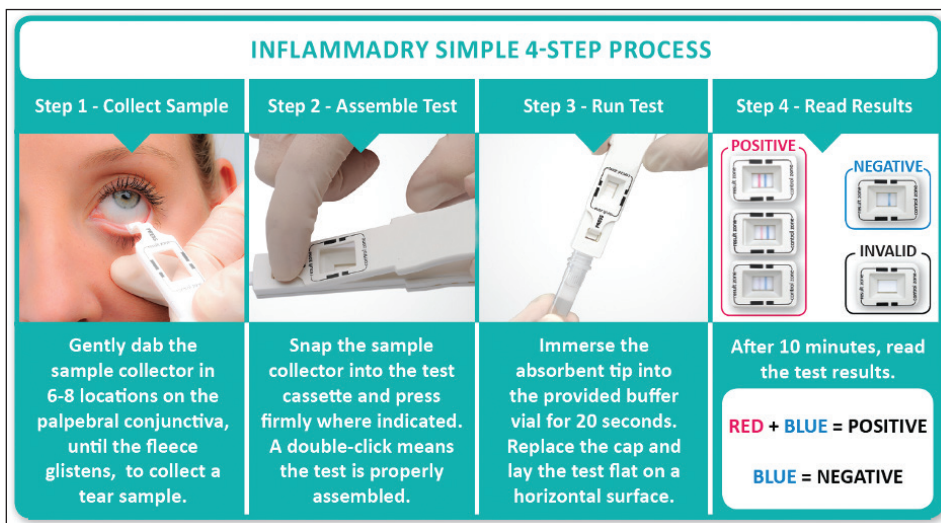


Figure 2. Like osmolarity testing, in-office evaluation of MMP-9 levels in tears is noninvasive and easy to perform. This step-by-step guide offers an overview of sample gathering, testing, and results interpretation.

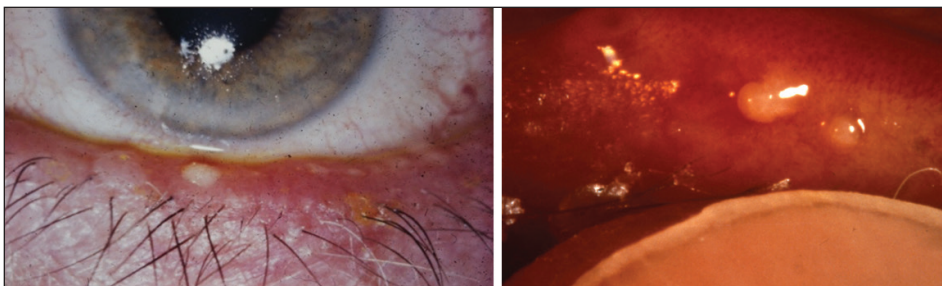


Figure 3. Meibomian gland blockage can be observed on slit-lamp examination. The raised white bumps on these lid margins are evidence of a blocked meibomian gland, and careful expression of these glands may lead to restored function.

Assessment of osmolarity prior to cataract surgery is appropriate given hyperosmolarity's link with less-than-desired outcomes. Compared with patients with average osmolarity, hyperosmolar patients experience significantly higher variability in average K readings and significantly higher percentages of 1.00-D differences in measured corneal astigmatism.²¹ Busy clinics may find that osmolarity assessments are useful differentiators in suspected DED patients. Patients with allergy, lid dysfunction, or environmental aggravations (and no DED) who present with symptoms such as watery eyes or ocular discomfort typically show healthy osmolarity scores, whereas patients with DED will have osmolarity measurements >310 mOsm/L.

Identification of Inflammatory Markers in Tear Samples

Matrix metalloproteinases (MMPs) are proteolytic enzymes that are produced by stressed epithelial cells on the ocular surface.²² Patients with ocular surface disease have demonstrated elevated levels of MMP-9 in tears.²² It has been determined that MMP-9 detection in tears is a more sensitive diagnostic marker than clinical signs, and correlates with clinical examination findings at a high rate.²²

The steps for in-office testing for MMP-9 levels resemble those of osmolarity testing (Figure 2). Collection of a tear sample takes only a few seconds, and transfer of the testing fleece into the sample collector is intuitive. Results, interpretation of which is straightforward, are reported after 10 minutes.

Like osmolarity testing, MMP-9 testing may be used in differential diagnosis of DED, allowing clinicians to eliminate other sources (ie, allergens or pollution) of DED-like symptoms. Choosing either osmolarity or MMP-9 testing for DED suspects may be appropriate for nonsurgical patients, although some surgeons preparing patients for cataract procedures may wish to perform both tests if seeking to confirm the presence of DED.

Ocular Surface Interferometry

Although osmolarity and MMP-9 testing are relatively noninvasive in that they do not require long contact with patients or serious disruption to ocular tissues, ocular surface interferometry is a truly noninvasive DED diagnostic modality. Ocular surface interferometry measures tear film lipid layer thickness and blinking patterns.²³

Lipid layer thickness measurements may be particularly useful when determining if a DED patient has MGD or aqueous-deficient disease. In 2022, Kim et al found that patients with MGD had lower lipid layer thickness measurements compared with patients who had aqueous-deficient DED.²⁴ If high rates of partial blinks are uncovered during examination with ocular surface interferometry, patients may be good candidates for blink training. In my clinic, we consider blink training if a partial blink rate of 40% is calculated on examination. Proper blinking techniques help keep meibomian glands in working order, and may prevent meibomian gland occlusion.

Analysis of Meibomian Gland Anatomy

Clinicians who examine meibomian glands in patients with DED can better understand if (and to what extent) MGD plays a role in their patient's condition. Meibography offers a chance to fully visualize meibomian glands and characterize dropout, and may be useful when educating patients with MGD-related DED.

Still, a standard slit-lamp examination is often sufficient for uncovering MGD

(Figure 3). Healthy lid margins produce oily meibum that spreads evenly upon expression, whereas patients whose expressions are pasty or uneven have MGD. Blocked meibomian glands should be cleared so that normal anatomy and function may be restored. Given that we do not have a method for restoring meibomian gland function after atrophy, we must prioritize preserving and restoring them before morphologic changes lead to permanent damage.

CONCLUSION

Identification of DED and MGD in preoperative cataract patients is foundational to their success. Given the various diagnostic tests at our disposal, clinicians should be able to find objective data that inform their diagnoses. Still, using only one test may be insufficient. In the PHACO study, Trattler et al found that the study's "results suggest that more than one diagnostic test may be necessary [for presurgical cataract patients] to identify those with undiagnosed ... [DED]."²⁵ If indeed clinicians are to use more than one methodology for diagnosing DED, they may do well to start with the modalities outlined here. ■

1. Storås AM, Strümke I, Riegler MA, et al. Artificial intelligence in dry eye disease. *Ocul Surf*. 2022;23:74-86.
2. Farrand KF, Fridman M, Stillman IO, Schaumberg DA. Prevalence of diagnosed dry eye disease in the United States among adults aged 18 years and older. *Am J Ophthalmol*. 2017;182:90-98.
3. Papas EB. The global prevalence of dry eye disease: A Bayesian view. *Ophthalmic Physiol Opt*. 2021;41(6):1254-1266.
4. Viso E, Rodriguez-Ares MT, Gude F. Prevalence of and associated factors for dry eye in a Spanish adult population (the Salnes

- Eye Study). *Ophthalmic Epidemiol*. 2009;16(1):15-21.
5. Hashemi H, Khabakzhoob M, Kheirkhah A, et al. Prevalence of dry eye syndrome in an adult population. *Clin Exp Ophthalmol*. 2014;42(3):242-248.
6. Vehof J, Kozareva D, Hysi PG, Hammond CJ. Prevalence and risk factors of dry eye disease in a British female cohort. *Br J Ophthalmol*. 2014;98(12):1712-1717.
7. Na KS, Han K, Park YG, et al. Depression, stress, quality of life, and dry eye disease in Korean women: a population-based study. *Cornea*. 2015;34(7):733-738.
8. Stapleton F, Alves M, Bunya VY, et al. TFOS DEWS II epidemiology report. *Ocul Surf*. 2017;15(3):334-365.
9. Badian RA, Utheim TP, Chen X, et al. Meibomian gland dysfunction is highly prevalent among first-time visitors at a Norwegian dry eye specialist clinic. *Sci Rep*. 2021;11(1):23412.
10. Lemp MA, Crews LA, Bron AJ, Foulks GN, Sullivan BD. Distribution of aqueous-deficient and evaporative dry eye in a clinic-based patient cohort: a retrospective study. *Cornea*. 2012;31(5):472-478.
11. Messmer EM. The pathophysiology, diagnosis, and treatment of dry eye disease. *Dtsch Arztebl Int*. 2015;112(5):71-81; quiz 82.
12. Craig JP, Nelson JD, Azar DT, et al. TFOS DEWS II report executive summary. *Ocul Surf*. 2017;15(4):802-812.
13. Craig JP, Nichols KK, Akpek EK, et al. TFOS DEWS II definition and classification report. *Ocul Surf*. 2017;15(3):276-283.
14. Rabensteiner DF, Aminfar H, Boldin I, et al. The prevalence of meibomian gland dysfunction, tear film and ocular surface parameters in an Austrian dry eye clinic population. *Acta Ophthalmol*. 2018;96(6):e707-e711.
15. McCann P, Abraham AG, Mukhopadhyay A, et al. Prevalence and incidence of dry eye and meibomian gland dysfunction in the United States: a systematic review and meta-analysis. *JAMA Ophthalmol*. 2022;140(12):1181-1192.
16. Cochener B, Cassan A, Omiel L. Prevalence of meibomian gland dysfunction at the time of cataract surgery. *J Cataract Refract Surg*. 2018;44(2):144-148.
17. Uzunosmanoglu E, Mocan MC, Kocabeyoglu S, Karakaya J, Irkeç M. Meibomian gland dysfunction in patients receiving long-term glaucoma medications. *Cornea*. 2016;35(8):1112-1116.
18. Machalińska A, Zakrzewska A, Adamek B, et al. Comparison of morphological and functional meibomian gland characteristics between daily contact lens wearers and nonwearers. *Cornea*. 2015;34(9):1098-1104.
19. Sullivan BD, Crews LA, Sönmez B, et al. Clinical utility of objective tests for dry eye disease: variability over time and implications for clinical trials and disease management. *Cornea*. 2012;31(9):1000-1008.
20. Starr CE, Gupta PK, Farid M, et al; ASCRS Cornea Clinical Committee. An algorithm for the preoperative diagnosis and treatment of ocular surface disorders. *J Cataract Refract Surg*. 2019;45(5):669-684.
21. Epitropoulos AT, Matossian C, Berdy GJ, et al. Effect of tear osmolarity on repeatability of keratometry for cataract surgery planning. *J Cataract Refract Surg*. 2015;41(8):1672-1677.
22. Chotiakanich S, de Paiva CS, Li de Duan, et al. *Invest Ophthalmol Vis Sci*. 2009;50(7):3203-3209.
23. Lee SM, Chung SJ, Lew H. Evaluation of tear film lipid layer thickness measurements obtained using an ocular surface interferometer in nasolacrimal duct obstruction patients. *Korean J Ophthalmol*. 2018;32(6):445-450.
24. Kim WJ, Ahn YJ, Kim MH. Lipid layer thickness decrease due to meibomian gland dysfunction leads to tear film instability and reflex tear secretion. *Ann Med*. 2022;54(1):893-899.
25. Trattler WB, Majmudar PA, Donnenfeld ED, et al. The prospective health assessment of cataract patients' ocular surface (PHACO) study: the effect of dry eye. *Clin Ophthalmol*. 2017;11:1423-1430.

Home-Based and In-Office Treatments for Dry Eye Disease Secondary to Meibomian Gland Dysfunction

ALICE T. EPITROPOULOS, MD, FACS

After dry eye disease (DED) and meibomian gland dysfunction (MGD) are identified, the question turns to how to best treat the patient. There are several routes to administer therapy, ranging from nutritional supplements to topical drops to in-office procedures to address obstruction of the meibomian glands. Selecting the treatment most tailored to your patient's individual disease characteristics, lifestyle, and medical history is key, and turning to algorithms such as those from DEWS II,¹ CEDARS,² and the American Society for Cataract and Refractive Surgeons³ may be useful when managing DED secondary to MGD, particularly in patients who are scheduled for cataract surgery.

Broadly speaking, treatments for DED and MGD can be grouped as home-based or in-office treatments. We will use that distinction as a framework to discuss various treatment approaches available to clinicians.

HOME-BASED TREATMENTS FOR DED SECONDARY TO MGD

Oral supplementation of omega-3 fatty acids significantly improves MGD scores in patients at 8 weeks.⁴ Consumption of a diet that includes fatty acids has been shown to reduce incidence of DED in some patients,⁵ and adjustments to a patient's diet may be warranted if a patient opts for dietary consumption of omega-3 fatty acids in lieu of supplementation. Omega-3 supplements in the proper dose, form (re-esterified), and ratio have been shown to improve both signs and symptoms of DED.⁶

Immunomodulators such as cyclosporine-A and lifitegrast (Xiidra, Novartis) have been shown to be effective therapies for patients with MGD. A 2018 study found that cyclosporin-A was effective at improving tear film stability and ocular discomfort in patients with MGD at 3 months, although it should be noted that the researchers in that study found no differences in meibomian gland secretion in cyclosporin-A patients compared with control patients.⁷ A 2020 study comparing the efficacy of lifitegrast treatment compared with thermal pulsation therapy for MGD found that, at day 42, patients who received lifitegrast therapy demonstrated significantly improved eye dryness, corneal staining, and eyelid redness compared with thermal pulsation patients, and that patients in both arms had similar lipid layer thickness.⁸ Three patients in the lifitegrast group withdrew due to lack of efficacy. The study author concluded that "lifitegrast should be included in treatment for inflammatory MGD."⁸

Prior to the approval by the US Food and Drug Administration (FDA) of loteprednol etabonate ophthalmic suspension 0.25% (Eysuvis, Kala Pharmaceuticals) clinicians used off-label topical steroids to treat DED; this is still the case in regions that have not yet seen regulatory approval. In approving the drug for the short-term (ie, up to 2 weeks) treatment of the signs and symptoms of DED, the FDA relied in part on data from the phase 3 STRIDE study, which found that treatment with loteprednol etabonate led to significant improvements at day 15 in ocular discomfort severity in both the intent-to-treat population and a predefined group with severe ocular discomfort.⁹ Safety of this treatment was confirmed in a pooled analysis of four studies (a single phase 2 study and a trio of phase 3 studies).¹⁰

Topical antibiotics with and without steroids may be helpful for some patients with chronic lid margin disease and MGD. Use of off-label topical azithromycin, utilized for its anti-inflammatory effects more than its antibiotic effects, has been shown to be successful in treating MGD when used alongside systemic azithromycin.¹¹ Topical azithromycin therapy has been shown to be as effective as oral doxycycline therapy for the treatment of MGD in terms of relieving signs and symptoms and restoring lipid properties of meibomian gland secretions, although doxycycline therapy was less effective than topical azithromycin therapy in improving foreign body sensation and signs of plugging and secretion.¹²

Systemic (ie, oral) antibiotics including tetracycline, doxycycline, minocycline, and azithromycin may be used to treat lid margin disease; like topical formulations, oral formulations of these antibiotics are used more for their anti-inflammatory properties than their antibiotic characteristics. Low doses of these drugs may be sufficient to achieve relief. One study found that 20 mg of oral doxycycline was as effective as a 200-mg dose in treating MGD.¹³

IN-OFFICE TREATMENT FOR DED SECONDARY TO MGD

For some patients, in-office treatments for DED and MGD are most effective when used in a step-wise approach. In my



Figure 1. Microphorexofoliation is key to establishing lid margin hygiene before initiating other in-office treatments for MGD. Use of a microsponge to debride biofilm at the lid margin assists in clearing obstructed meibomian glands. Screenshot of video courtesy James Rynerson, MD.

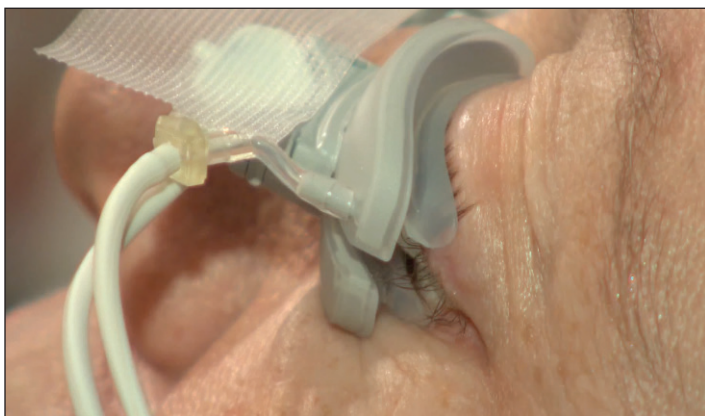

Figure 2. Thermal pulsation therapy, which takes approximately 12 minutes, relies on a combination of heat and vectored pulsation to clear obstructed meibomian glands. Screenshot of video courtesy Tauber Eye Center.

clinic, I use a combination approach that involves lid margin hygiene, addressing meibomian gland obstruction, and reducing inflammation. These three treatment categories are synergistic and are more effective when addressed early in the disease process, before patients have significant gland atrophy or dropout.

Microblepharoexfoliation (BlephEx) reduces bacteria and *Demodex* mites that contribute to inflammation and meibomian gland obstruction (Figure 1). During this procedure, a medical-grade micro sponge exfoliates a patient's eyelids and lashes. When educating patients on this procedure, I compare the biofilm removed by the sponge to dental plaque that accumulates near gumlines, thereby providing an easy from of reference for most patients.

Thermal pulsation therapy (LipiFlow, Johnson & Johnson) was first approved by the FDA in 2011 (Figure 2). When receiving a LipiFlow treatment, patients' meibomian glands are heated and vectored pulsation clears meibomian gland obstruction. The procedure is brief (ie, ~12 minutes), and a single session has been shown to have effects up to 36 months.¹⁴ A systematic review and meta-analysis of 10 randomized clinical trials incorporating 761 patients concluded thermal pulsation can improve signs and symptoms of MGD without increasing the incidence of adverse events.¹⁵

A handheld thermal device called iLux (Alcon) allows clinicians to visualize meibomian glands through a magnifier while applying heat via a light source (Figure 3). Clinicians apply pressure to the lids using the iLux device, and can monitor gland expression to identify areas that may need extra attention.

A 2020 study by Tauber et al compared 4-week outcomes in MGD patients who underwent therapy with either LipiFlow or iLux.¹⁶ The study authors concluded that no statistically significant differences were detected among the groups when measuring meibomian gland scoring, tear break-up time, or Ocular Surface Disease Index scoring. Wesley et al found similar results in 2022, and concluded that iLux was noninferior to LipiFlow for MGD at 1 year.¹⁷

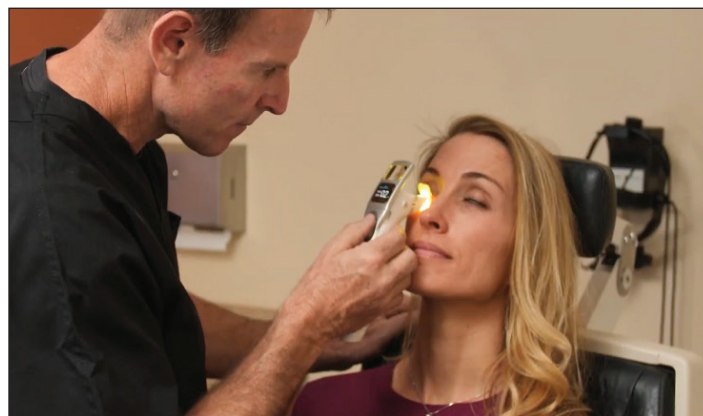

Figure 3. A handheld thermal applicator that doubles as a tool for expressing meibomian glands enables clinicians to visualize meibomian glands through a magnification mechanism. Screenshot of video courtesy Alcon.

When using TearCare (Sight Sciences), a localized thermal therapy that applies heat to a patient's eyelids via disposal adhesive patches, patients are able to blink normally. After heat is applied, manual expression is required. Gupta et al found that a single TearCare procedure was equivalent to a single LipiFlow procedure in terms of efficacy and safety at 1 month in MGD patients.¹⁸

Like the iLux, the MiBoFlo (MiBo Medical Group) is a handheld thermal applicator that allows expression of meibomian glands. A study comparing a course of therapy with MiBoFlo (ie, three 10-minute treatments every 2 weeks) to a single 12-minute LipiFlow treatment determined that improvements were found in both treatment arms at months 1 and 2.¹⁹ Insufficient number of enrolled patients and follow-up time may have caused some deviations in the results.

Intense pulsed light (IPL) therapy, which was originally developed for dermatologic conditions, targets abnormal telangiectatic vessels that contribute to inflammation; IPL also has documented antimicrobial properties and may contribute to the fluidification of clogged meibum.²⁰ An ophthalmic-specific IPL platform (OptiLight; Lumenis) was approved in 2021 for improving signs of DED due to MGD.

Intraductal probing, the most invasive in-office procedure to address MGD, may be used for patients whose condition has inadequately responded to other treatments. Use of local anesthetic and a microcannula are required, and the procedure can be uncomfortable for patients. Still, release of obstructed meibomian glands via mechanical manipulation has been shown to be effective: 96% of patients in a study evaluating intraductal probing for MGD reported immediate relief following the procedure, and 100% of patients reported relief at week 4.²¹

CONCLUSION

We are fortunate to have access to several methods of relieving DED for patients whose disease is mediated by MGD, and simultaneous use of at-home and in-office treatments

may yield good results for patients. In the following article, my colleague John D. Sheppard, MD, MMSc, offers a glimpse into the developmental pipeline for DED and MGD therapy. ■

1. Nelson JD, Craig JP, Akpek EK, et al. TFOS DEWS II introduction. *Ocul Surf*. 2017;15(3):269-275.
2. Milner MS, Beckman KA, Luchs JJ, et al. Dysfunctional tear syndrome: dry eye disease and associated tear film disorders - new strategies for diagnosis and treatment. *Curr Opin Ophthalmol*. 2017;27 Suppl 1(Suppl 1):3-47.
3. American Society of Cataract and Refractive Surgeons. ASCRS Preoperative OSD Algorithm. Available at: <https://ascrs.org/clinical-education/cornea/ascrs-preoperative-osd-algorithm>. Accessed June 16, 2023.
4. Jo YJ, Lee JS. Effects of dietary high dose DHA omega-3 supplement in dry eye with meibomian gland dysfunction. *Int J Ophthalmol*. 2021;14(11):1700-1706.
5. Miljanović B, Trivedi KA, Dana MR, et al. Relation between dietary n-3 and n-6 fatty acids and clinically diagnosed dry eye syndrome in women. *Am J Clin Nutr*. 2005;82(4):887-893.
6. Epiropoulos AT, Donnenfeld ED, et al. Effect of oral re-esterified omega-3 nutritional supplementation on dry eyes. *Cornea*. 2016;35(9):1185-1191.
7. Kim HY, Lee JE, Oh HN, et al. Clinical efficacy of combined topical 0.05% cyclosporine A and 0.1% sodium hyaluronate in the dry eyes with meibomian gland dysfunction. *Int J Ophthalmol*. 2018;11(4):593-600.
8. Tauber J. A 6-week, prospective, randomized, single-masked study of lifitegrast ophthalmic solution 5% versus thermal pulsation procedure for treatment of inflammatory meibomian gland dysfunction. *Cornea*. 2020;39(4):403-407.
9. Kala Pharmaceuticals Announces Statistically Significant Results for Primary and Key Secondary Endpoints in STRIDE 3 Clinical Trial Evaluating EYSUVIS™ for Signs and Symptoms of Dry Eye Disease [press release]. Kala Pharmaceuticals; March 9, 2020; Watertown, MA.
10. Korenfeld M, Nichols KK, Goldberg D, et al. Safety of KPI-121 ophthalmic suspension 0.25% in patients with dry eye disease: a pooled analysis of 4 multicenter, randomized, vehicle-controlled studies. *Cornea*. 2021;40(5):564-570.
11. Ciloglu E, Özcan AA, Incekalan T, Unal F. The role of topical azithromycin in the treatment of meibomian gland dysfunction. *Cornea*. 2020;39(3):321-324.
12. Foulks GN, Borchman D, Yappert M, Kakar S. Topical azithromycin and oral doxycycline therapy of meibomian gland dysfunction: a comparative clinical and spectroscopic pilot study. *Cornea*. 2013;32(1):44-53.
13. Yoo SE, Lee DC, Chang MH. The effect of low-dose doxycycline therapy in chronic meibomian gland dysfunction. *Korean J Ophthalmol*. 2005;19(4):258-263.
14. Greiner JV. Long-term (3 year) effects of a single thermal pulsation system treatment on meibomian gland function and dry eye symptoms. *Eye Contact Lens*. 2016;42(2):99-107.
15. Hu J, Zhu S, Liu X. Efficacy and safety of a vectored thermal pulsation system (Lipiflow) in the treatment of meibomian gland dysfunction: a systematic review and meta-analysis. *Graefes Arch Clin Exp Ophthalmol*. 2022;260(1):25-39.
16. Tauber J, Owen J, Bloomenstein M, Hovanesian J, Bullimore MA. Comparison of the iLux and the LipiFlow for the treatment of meibomian gland dysfunction and symptoms: a randomized clinical trial. *Clin Ophthalmol*. 2020;14:405-418.
17. Wesley G, Bickle K, Downing J, et al. Comparison of two thermal pulsation systems in the treatment of meibomian gland dysfunction: a randomized, multicenter study. *Optom Vis Sci*. 2022;99(4):323-332.
18. Gupta PK, Holland EJ, Hovanesian J, et al. TearCare for the treatment of meibomian gland dysfunction in adult patients with dry eye disease: a masked randomized controlled trial. *Cornea*. 2022;41(4):417-426.
19. Li S, Yang K, Wang J, et al. Effect of a novel thermostatic device on meibomian gland dysfunction: a randomized controlled trial in Chinese patients. *Ophthalmol Ther*. 2022;11(1):261-270.
20. Giannaccare G, Taroni L, Senni C, Scorgia V. Intense pulsed light therapy in the treatment of meibomian gland dysfunction: current perspectives. *Clin Optom (Auckl)*. 2019;11:113-126.
21. Maskin SL. Intraductal meibomian gland probing relieves symptoms of obstructive meibomian gland dysfunction. *Cornea*. 2010;29(10):1145-52.

The Future of Pharmacologic Therapy in Meibomian Gland Dysfunction

JOHN D. SHEPPARD, MD, MMSc, FACS

For nearly 20 years, pharmacologic therapy for dry eye disease (DED) and meibomian gland dysfunction (MGD) was dominated by cyclosporine ophthalmic emulsion 0.05% (Restasis, Allergan). This was because other treatments had not yet been approved by regulatory bodies, were cumbersome, were ineffective, or were impractical in real-world settings. As Alice T. Epitropoulos, MD, FACS, explained in the previous article, clinicians now have various approaches for treating DED and MGD, enabling more tailored therapy—and further options are on the way.

Because a full examination of the developmental pipeline is beyond the scope of this discussion, I will focus only on four imminent interventions. The first intervention, approved by the FDA for the signs and symptoms of DED in May 2023, is perfluorohexyloctane ophthalmic solution, formerly known as NOV03 (Miebo, Bausch + Lomb). The second intervention, approved by the FDA for the treatment of *Demodex* blepharitis in July 2023, is lotilaner ophthalmic solution 0.25%, formerly known as TP-03 (Xdemvy, Tarsus Pharmaceuticals). The other interventions I will discuss are two drug candidates that, based on the findings of their respective clinical trials, may be close to regulatory approval. These include AZR-MD-001 (Azura Ophthalmics) and reproxalap (Aldeyra Therapeutics).

NOV03

NOV03 is designed to address tear evaporation on the ocular surface, a condition often linked with MGD.^{1,2} The safety and efficacy of NOV03 for the treatment of DED were assessed in the randomized, multicenter, double-masked, pivotal phase 3 GOBI and MOJAVE studies, which enrolled more than 1,200 patients with DED and clinical signs of MGD. Patients were randomly assigned 1:1 to NOV03 or hypotonic saline. The studies' primary endpoints were changed from baseline in total corneal fluorescein staining (tCFS) and eye dryness Visual Analog Scale (VAS) score at day 57 (\pm 2 days), which may be considered a sign and a symptom, respectively.

The studies met their primary endpoints.^{3,4} Eyes in the treatment arm compared with the control arm experienced significantly greater least-squares (LS) mean change from baseline to week 8 for tCFS (-2.3 vs -1.1, respectively) and VAS scoring (-29.4 vs 19.2, respectively) in MOJAVE; statistically significant differences for both endpoints were detected starting at week 2.⁵ Similar outcomes were seen in GOBI, with NOV03 treatment

	Number of patients (%)	
	NOV03 (n=303)	Saline (n=294)
Patients with \geq 1 ocular study eye AE	25 (8.3)	15 (5.1)
Most common study eye AEs*		
-Blurred vision	9 (3.0)	1 (0.3)

Abbreviation: AE, adverse event.
Source: Tauber J, Berdy GJ, Wirta DL, et al: GOBI Study Group. NOV03 for dry eye disease associated with meibomian gland dysfunction: results of the randomized phase 3 GOBI study. *Ophthalmology*. 2023;130(5):516-524.

	Number of patients (%)	
	NOV03 (n=311)	Saline (n=309)
Patients with \geq 1 ocular study eye AE	30 (9.6)	30 (9.7)
Most common study eye AEs*		
-Blepharitis	5 (1.6)	1 (0.3)
-Blurred vision	4 (1.3)	1 (0.3)
-Conjunctival hyperemia	4 (1.3)	5 (1.6)
-Conjunctival papillae	4 (1.3)	5 (1.6)
-Eye discharge	1 (0.3)	3 (1.0)
-Eye pain	1 (0.3)	3 (1.0)

Abbreviation: AE, adverse event.
Source: Sheppard JD, Kurata F, Epitropoulos AT, et al: MOJAVE Study Group. NOV03 for signs and symptoms of dry eye disease associated with meibomian gland dysfunction: the randomized phase 3 MOJAVE study. *Am J Ophthalmol*. 2023;252:265-274.

resulting in significantly greater LS mean change from baseline to week 8 for tCFS and VAS scoring at day 573; like MOJAVE, improvements in GOBI were seen as early as 2 weeks. Safety results for GOBI and MOJAVE can be viewed in Tables 1 and 2.

The FDA approved NOV03 for the signs and symptoms of DED in May 2023.⁵ Per its label, it is dosed 4 times daily in each eye.⁶

AZR-MD-01

AZR-MD-001, a novel formulation of selenium sulfide adapted from the dermatology space, takes a three-pronged approach to treating MGD: it promotes the breakdown of disulfide bonds, slows production of keratin, and stimulates meibum production. In a phase 2b clinical study evaluating the safety and efficacy of AZR-MD-001 for the treatment of MGD, patients were required to administer the treatment to their bottom eyelid twice weekly at bedtime.

The study met its primary endpoints, with a mean increase from baseline of 1.8 meibomian glands secreting meibum ($P < .001$) and a significant improvement in Ocular Surface Disease Index (OSDI) scoring observed at 3 months.⁷ Patient-reported data showed

that AZR-MD-001 was effective at significantly improving SPEED scores, VAS scores, eye discomfort, eye dryness, and ocular itch.

Safety data were unremarkable, with a majority of adverse events (AEs) categorized as mild and transient; no serious treatment-related AEs were observed.⁷ Treatment-emergent AEs led to discontinuation of 2.4% of patients in the study.

A second pivotal study, which will be a phase 3 study, is scheduled to begin in 2023.⁷

REPROXALAP

Reproxalap is a topical formulation of a reactive aldehyde species (RASP) inhibitor designed for the treatment of DED.⁸ To most clinicians, RASP inhibition is a new approach to DED and MGD treatment. Inflammatory ocular diseases such as DED, allergic conjunctivitis, noninfectious uveitis, and Sjögren syndrome are linked with increased RASP levels.

The safety and efficacy of reproxalap for the treatment of DED were assessed in the phase 3 TRANQUILITY and TRANQUILITY-2 studies.^{9,10} In TRANQUILITY, the primary endpoint of reduction in ocular redness from baseline was not met. However, use of topical reproxalap was linked with a significant improvement in Schirmer test scoring, which was a secondary endpoint in the study; a post hoc analysis found a significantly higher rate of Schirmer test responders ≥ 10 mm.

Because Schirmer test scoring has been used by the FDA as an endpoint for other DED product approvals, the endpoint of TRANQUILITY-2 was modified to include Schirmer testing scoring improvement from baseline.⁹ In TRANQUILITY-2, both primary endpoints (ie, Schirmer test scoring and proportion of Schirmer test responders ≥ 10 mm) were met.¹⁰

A 12-month, vehicle-controlled, multicenter, parallel-group safety clinical trial that enrolled 447 patients (299 treated with reproxalap) observed no serious AEs related to treatment.¹¹ The most common AE related to treatment was mild and transient instillation site irritation.

A New Drug Application (NDA) filing was accepted by the FDA, and the agency is expected to make a decision on approval in November 2023.¹²

Reproxalap has also been studied in human cohorts for noninfectious anterior uveitis¹³ as well as allergic conjunctivitis.^{14,15} Aldeyra Therapeutics announced positive top-line results from the phase 3 INVIGORATE-2 clinical trial of 0.25% reproxalap ophthalmic solution, an investigational new drug, in patients with allergic conjunctivitis. According to a press release from the company, the clinical trial successfully achieved statistical significance for the primary endpoint and all secondary endpoints.¹⁶ An NDA for allergy was submitted in February 2023, and the FDA is expected to make a decision by November 2023.

TP-03

Treatment of *Demodex* blepharitis could meaningfully contribute to MGD resolution in some patients. TP-03 is a

formulation of lotilaner ophthalmic solution 0.25% designed to treat *Demodex* blepharitis by addressing *Demodex* infestation.

The safety and efficacy of TP-03 were assessed in the pivotal Saturn-1 and Saturn-2 studies. The phase 2b/3 Saturn-1 study was a randomized, controlled, multicenter, double-masked trial that evaluated TP-03 in 421 adults who had more than 10 collarettes on the upper lid and at least mild erythema of the upper eyelid margin.¹⁷ Patients self-administered 1 drop of TP-03 twice daily for 6 weeks, and were randomly assigned to either TP-03 or vehicle. At day 43, use of TP-03 resulting in a statistically significant complete collarette cure (defined as 0 to 2 collarettes per lid), which was the primary endpoint. Secondary endpoints of mite eradication (ie, 0 density of mites per lash) at day 43 and composite cure based on complete collarette and erythema cures at day 43 were also met.

The phase 3 Saturn-2 study was similarly designed. At day 43, 56% of patients in the treatment arm demonstrated complete collarette cure compared with 13% of patients in the control arm, which was statistically significant.¹⁸ The difference in mite eradication rates for the treatment and control groups was statistically significant (52% vs 14%, respectively), as was the difference in complete lid erythema cure (13% vs 9%, respectively).¹⁸ The drug was well tolerated in both pivotal studies, and 91% of patients reported that the drop was neutral to comfortable during application.¹⁹

The FDA approved TP-03 for the treatment of *Demodex* blepharitis in July 2023.²⁰ Per its label, it is dosed twice daily in each eye (approximately 12 hours apart) for 6 weeks.²¹

CONCLUSION

With targeted therapy comes targeted patient specific care titrated to the signs generating ocular surface disease. As more treatment options come online—and as those options become more specific in their mechanisms of action—clinicians will be better able to address and treat the root causes of a patient's MGD and DED. ■

- Nichols KK, Foulks GN, Bron AJ, et al. The international workshop on Meibomian gland dysfunction: executive summary. *Invest Ophthalmol Vis Sci*. 2011;52(4):1922-1929.
- Borchman D, Vittitow J, Ewurum A, Veligandi SR. Spectroscopic study of perfluorohexyloctane human meibum interactions. *Invest Ophthalmol Vis Sci*. 2022;63:1525.
- Tauber J, Berdy GJ, Wirta DL, et al: GOBI Study Group. NOV03 for dry eye disease associated with meibomian gland dysfunction: results of the randomized phase 3 GOBI study. *Ophthalmology*. 2023;130(5):516-524.
- Sheppard JD, Kurata F, Epitropoulos AT, et al: MOJAVE Study Group. NOV03 for signs and symptoms of dry eye disease associated with meibomian gland dysfunction: the randomized phase 3 MOJAVE study. *Am J Ophthalmol*. 2023;252:265-274.
- Bausch + Lomb and Novaliq Announce FDA Approval of Miebo (Perfluorohexyloctane Ophthalmic Solution) for the Treatment of the Signs and Symptoms of Dry Eye Disease [press release]. Bausch + Lomb/Novaliq; May 18, 2023; Vaughan, Ontario, and Heidelberg, Germany.
- Miebo prescribing information. Bausch + Lomb. Available at: <https://www.bausch.com/globalassets/pdf/packageinserts/pharma/miebo-package-insert.pdf>. Accessed June 19, 2023.
- Azura Ophthalmics announces positive results from phase 2b clinical trial of AZR-MD-001 in Meibomian Gland Dysfunction [press release]. Azura Ophthalmics; November 17, 2022; Tel Aviv, Israel, and Melbourne, Australia.
- Clark D, Sheppard J, Brady TC. A randomized double-masked phase 2a trial to evaluate activity and safety of topical ocular reproxalap, a novel RASP inhibitor, in dry eye disease. *J Ocul Pharmacol Ther*. 2021;37(4):193-199.
- Aldeyra Therapeutics announces top-line results from the phase 3 TRANQUILITY Trial in dry eye disease [press release]. Aldeyra Therapeutics; December 20, 2021; Lexington, MA.
- Aldeyra Therapeutics achieves primary endpoint in phase 3 TRANQUILITY 2 Trial in dry eye disease and intends to submit new drug application for symptoms and three sign endpoints of dry eye disease [press release]. Aldeyra Therapeutics; June 8, 2022; Lexington, MA.
- Aldeyra Therapeutics announces positive top-line results from 12-month safety clinical trial of reproxalap in patients with dry eye disease [press release]. Aldeyra Therapeutics; February 28, 2023; Lexington, MA.
- Aldeyra Therapeutics Announces FDA Acceptance of New Drug Application for Reproxalap for the Treatment of Dry Eye Disease [press release]. Aldeyra Therapeutics; February 7, 2023; Lexington, MA.
- Mandell KJ, Clark D, Chu DS, et al. Randomized phase 2 trial of reproxalap, a novel reactive aldehyde species inhibitor, in patients with noninfectious anterior uveitis: model for corticosteroid replacement. *J Ocul Pharmacol Ther*. 2020;36(10):732-739.

14. Clark D, Karpecki P, Salapatek AM, et al. Reproxalap improves signs and symptoms of allergic conjunctivitis in an allergen chamber: a real-world model of allergen exposure. *Clin Ophthalmol*. 2022;16:15-23.
 15. Clark D, Cavanagh B, Shields AL, et al. Clinically relevant activity of the novel RASP inhibitor reproxalap in allergic conjunctivitis: the phase 3 ALLEVIATE trial. *Am J Ophthalmol*. 2021;230:60-67.
 16. Aldeyra Therapeutics announces achievement of statistical significance for primary endpoint and all secondary endpoints in phase 3 INVIGORATE 2 Trial of reproxalap in allergic conjunctivitis [press release]. Aldeyra Therapeutics; June 15, 2023; Lexington, MA.
 17. Tarsus Pharmaceuticals, Inc. Announces Positive Results of Saturn-1 Pivotal Trial Evaluating TP-03 for the Treatment of Demodex Blepharitis [press release]. Tarsus Pharmaceuticals; June 21, 2021. Irvine, CA.
 18. Tarsus Announces positive topline data from Saturn-2 phase 3, the second pivotal trial of TP-03 for the treatment of

Demodex blepharitis, and expects to file a new drug application this Year [press release]. Tarsus Pharmaceuticals; May 2, 2022; Irvine, CA.
 19. Yeu E, et al. Safety & efficacy of lotilaner ophthalmic solution, 0.25% in treating Demodex blepharitis. Results of the Saturn-2, pivotal, phase III trial. Presented at: American Academy of Ophthalmology 2022; September 30-October 3, 2022; Chicago, IL.
 20. FDA Approves XDEMYV™ (lotilaner ophthalmic solution) 0.25% for the treatment of Demodex blepharitis [press release]. Tarsus; July 25, 2023; Irvine, CA.
 21. Xdemvy prescribing information. Tarsus. Available at: <https://tarsusrx.com/wp-content/uploads/XDEMYV-Prescribing-Information-24JUL23.pdf>. Accessed July 26, 2023.

MEIBOMIAN GLAND DYSFUNCTION IN A 66-YEAR-OLD SURGEON PRESENTING FOR CATARACT EVALUATION

ALICE T. EPITROPOULOS, MD, FACS

A 66-year-old man presented for a cataract evaluation. The patient is a surgeon, and has observed glare, halos, and starbursts during nighttime, as well as intermittent blurring during screen use. He reports gradual decline in vision quality during the past 5 years, that he is no longer able to drive at night or use a computer screen for more than a few minutes, and that his vision “comes and goes.” Other than contact lens wear, the patient has no significant ocular history. His SPEED score is 5.

Examination shows that the patient has bilateral collarettes, 20/40 BCVA in each eye, and decreased tear film break-up time of 5 seconds in both eyes. The patient has a history of tamsulosin use, and only dilates to 5 mm. Significant corneal staining is consistent with dry eye disease (DED; Figure 1). Meibography

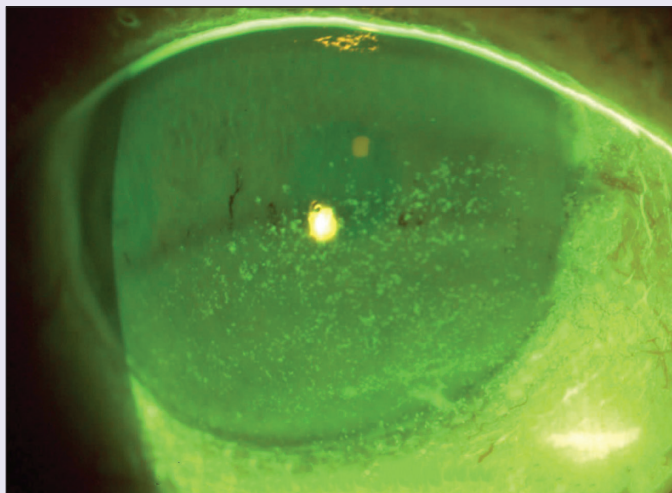


Figure 1. Examination showed that the patient has DED, based in part of corneal staining patterns. Photograph courtesy Alice T. Epitropoulos, MD, FACS.

showed that the patient’s meibomian glands had high degrees of atrophy (Figure 2), suggesting that his DED was secondary to meibomian gland dysfunction (MGD).

Before taking this patient to cataract surgery, I decided to address his underlying MGD. The patient has been directed to use omega-3 supplements and a topical anti-inflammatory drop, and is scheduled to return to the clinic for in-office treatments that will relieve obstruction of his meibomian glands. After his tear film is stabilized, I am more confident that accurate biometry readings can be obtained, thereby maximizing the potential for positive outcomes after cataract surgery.

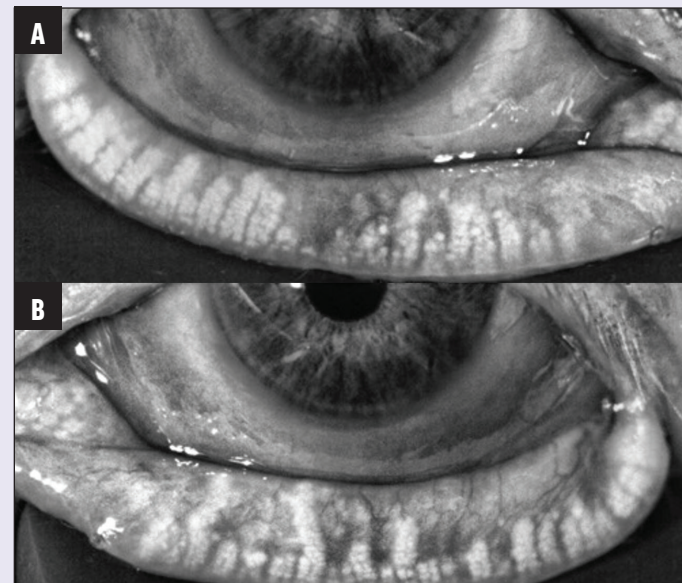


Figure 2. Examination of the right (A) and left (B) meibomian glands showed significant gland atrophy. Photographs courtesy Alice T. Epitropoulos, MD, FACS.

The Expanding Armamentarium: The Latest in MGD-DED Diagnostics and Treatment

Release Date: August 2023
Expiration Date: August 2024

INSTRUCTIONS FOR CREDIT

To receive credit, you must complete the attached **Pretest/Posttest/Activity Evaluation/Satisfaction Measures Form** and mail or fax to Evolve Medical Education LLC; 353 West Lancaster Avenue, Second Floor, Wayne, PA 19087; Fax: (215) 933-3950. To answer these questions online and receive real-time results, go to <https://evolvemed.com/course/2313-supp>. If you experience problems with the online test, email us at info@evolvemed.com. *NOTE: Certificates are issued electronically.*

Please type or print clearly, or we will be unable to issue your certificate.

Full Name _____ DOB (MM/DD): _____

Phone (required) _____ Email (required*) _____

Address/P.O. Box _____

City _____ State/Country _____ Zip _____

License Number: _____ OE Tracker Number: _____ National Provider ID: _____

*Evolve does not share email addresses with third parties.

DEMOGRAPHIC INFORMATION

Profession	Years in Practice	Patients Seen Per Week (with the disease targeted in this educational activity)	Region
<input type="checkbox"/> MD/DO	<input type="checkbox"/> >20	<input type="checkbox"/> 0	<input type="checkbox"/> Midwest
<input type="checkbox"/> OD	<input type="checkbox"/> 11-20	<input type="checkbox"/> 1-15	<input type="checkbox"/> Northeast
<input type="checkbox"/> NP	<input type="checkbox"/> 6-10	<input type="checkbox"/> 16-30	<input type="checkbox"/> Northwest
<input type="checkbox"/> Nurse/APN	<input type="checkbox"/> 1-5	<input type="checkbox"/> 31-50	<input type="checkbox"/> Southeast
<input type="checkbox"/> PA	<input type="checkbox"/> <1	<input type="checkbox"/> >50	<input type="checkbox"/> Southwest
<input type="checkbox"/> Other			

LEARNING OBJECTIVES

Did the program meet the following educational objectives?	Agree	Neutral	Disagree
Diagnose dry eye disease (DED) by subtype based on signs and symptoms	_____	_____	_____
Articulate how meibomian gland dysfunction (MGD) interacts with DED	_____	_____	_____
Summarize the latest data on treatments for MGD	_____	_____	_____
Compare the pipeline agents nearest to regulatory approval and explain their mechanisms of action	_____	_____	_____

POSTTEST QUESTIONS

Please complete at the conclusion of the program.

- 1. Based on this activity, please rate your confidence in your ability to diagnose and treat dry eye disease (DED) associated with meibomian gland dysfunction (MGD; based on a scale of 1 to 5, with 1 being not at all confident and 5 being extremely confident).**
 - A. 1
 - B. 2
 - C. 3
 - D. 4
 - E. 5
- 2. All of the following represent signs and symptoms of DED EXCEPT:**
 - A. Redness/itching/watery eyes
 - B. Low tear osmolarity
 - C. High tear osmolarity
 - D. Elevated MMP-9 tear level
- 3. A 65-year-old man presents to your clinic for cataract evaluation. He notes blurry vision bilaterally that fluctuates daily as well as increased matting on his eyelids in the morning. Slit lamp exam reveals diffuse corneal staining and meibography shows gland duct dilation and dropout. All of the following statements are true about this patient EXCEPT:**
 - A. This patient has DED that should be optimized before cataract surgery
 - B. This patient has MGD
 - C. Most precataract surgical patients do not have MGD, so this patient likely has aqueous deficiency DED
 - D. Lens calculations obtained on this patient are likely erroneous due to his DED
- 4. Which of the following MGD treatment option modulates the immune response to alleviate DED?**
 - A. Preservative-free artificial tear drops
 - B. Lifitegrast
 - C. Thermal pulsation
 - D. Meibomian gland expression
- 5. A 65-year-old woman presents to your office for evaluation of eye discomfort. She notes frequent red/itchy eyes, with increased tearing daily. In-office testing reveals high tear osmolarity and significant meibomian gland inspissation. All of the following represent evidence-based treatment options for this patient's MGD EXCEPT:**
 - A. Azithromycin treatment
 - B. In-office treatment with thermal pulsation, microblepharoexfoliation, or intense pulsed light therapy
 - C. Immunomodulator therapy with topical cyclosporine A
 - D. IV steroid therapy
- 6. Which of the following MGD therapeutics can treat *Demodex* mites?**
 - A. AZR-MD-001
 - B. TP-03
 - C. Reproxalap
 - D. NOV03

ACTIVITY EVALUATION

Your responses to the questions below will help us evaluate this activity. They will provide us with evidence that improvements were made in patient care as a result of this activity.

Rate your knowledge/skill level prior to participating in this course: 5 = High, 1 = Low _____

Rate your knowledge/skill level after participating in this course: 5 = High, 1 = Low _____

This activity improved my competence in managing patients with this disease/condition/symptom. _____ Yes _____ No

Probability of changing practice behavior based on this activity: _____ High _____ Low _____ No change needed

If you plan to change your practice behavior, what type of changes do you plan to implement? (check all that apply)

Change in pharmaceutical therapy _____ Change in nonpharmaceutical therapy _____

Change in diagnostic testing _____ Choice of treatment/management approach _____

Change in current practice for referral _____ Change in differential diagnosis _____

My practice has been reinforced _____ I do not plan to implement any new changes in practice _____

Please identify any barriers to change (check all that apply):

_____ Cost _____ Lack of consensus or professional guidelines

_____ Lack of administrative support _____ Lack of experience

_____ Lack of time to assess/counsel patients _____ Lack of opportunity (patients)

_____ Reimbursement/insurance issues _____ Lack of resources (equipment)

_____ Patient compliance issues _____ No barriers

_____ Other. Please specify: _____

The design of the program was effective for the content conveyed _____ Yes _____ No

The content supported the identified learning objectives _____ Yes _____ No

The content was free of commercial bias _____ Yes _____ No

The content was relative to your practice _____ Yes _____ No

The faculty was effective _____ Yes _____ No

You were satisfied overall with the activity _____ Yes _____ No

You would recommend this program to your colleagues _____ Yes _____ No

Please check the Core Competencies (as defined by the Accreditation Council for Graduate Medical Education) that were enhanced through your participation in this activity:

_____ Patient Care

_____ Practice-Based Learning and Improvement

_____ Professionalism

_____ Medical Knowledge

_____ Interpersonal and Communication Skills

_____ System-Based Practice

Additional comments:

This information will help evaluate this activity; may we contact you by email in 3 months to inquire if you have made changes to your practice based on this activity? If so, please provide your email address below.
