

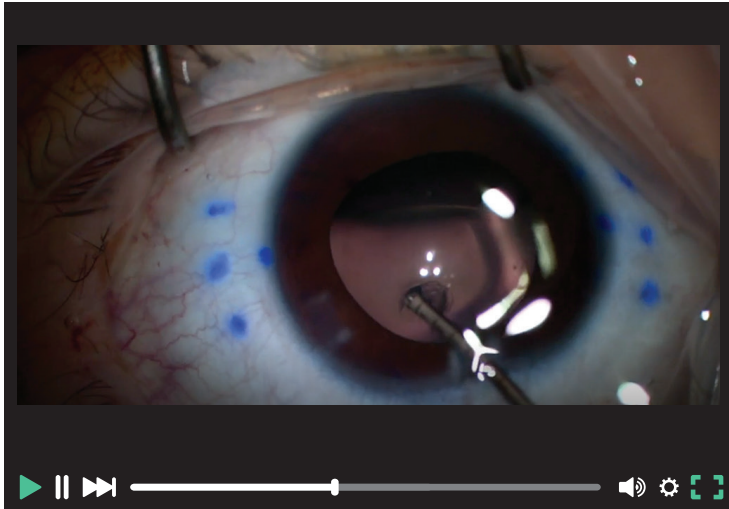


eyetube SPOTLIGHT

COMBINED SCLERAL-FIXATED IOL AND 360° TRABECULOTOMY

Kamran Ahmed, MD, and Kerri McInnis-Smith

Dr. Ahmed demonstrates cataract surgery and the scleral fixation of an IOL combined with 360° trabeculotomy and viscocanaloplasty in both eyes of a 3-year-old with bilateral congenital glaucoma and secondary lens subluxation.

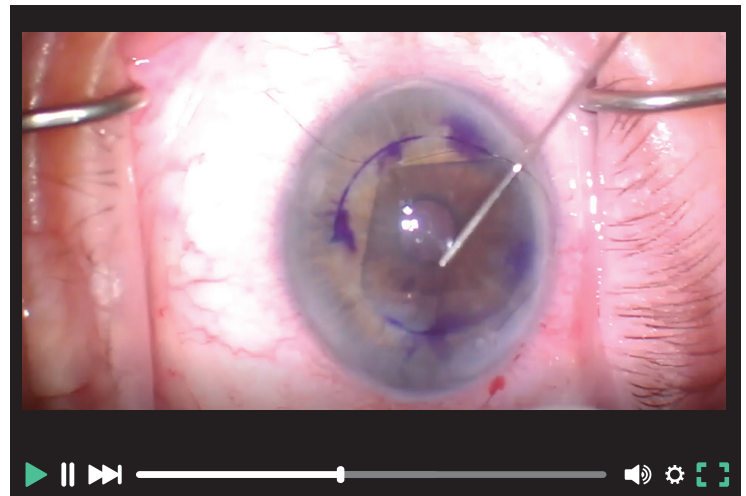


SCAN THE QR CODE TO
VIEW THIS CONTENT

DMEK IN FUCHS ENDOTHELIAL DYSTROPHY

Matthew Weinstein, DO

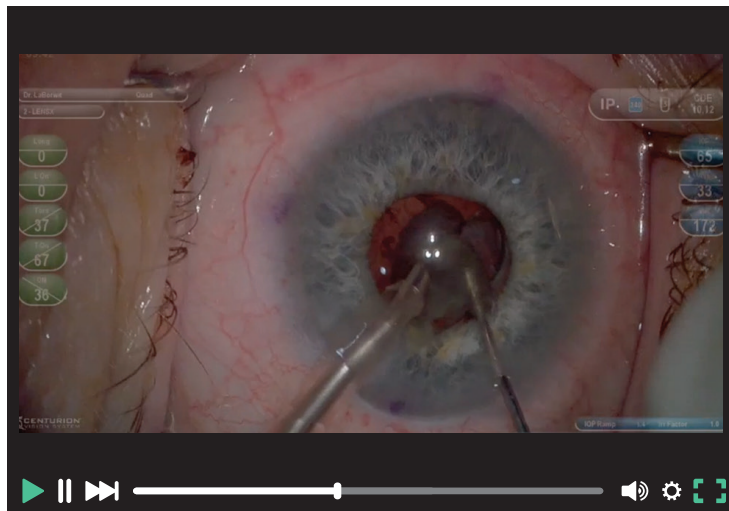
Dr. Weinstein presents a case of Descemet membrane endothelial keratoplasty (DMEK) with preloaded tissue in the eye of a patient with Fuchs endothelial dystrophy.



A SMALL PUPIL CHALLENGE

Scott LaBorwit, MD

Dr. LaBorwit demonstrates cataract surgery in an eye with a small pupil using a 3D visualization system.



Presbyopia Perspectives

CRST Chief Medical Editor Cathleen M. McCabe, MD, hosts a discussion on preferred presbyopia treatments and patient selection for pharmacologic agents, premium IOL technologies, and refractive procedures with guests Audrey R. Talley Rostov, MD; Brian M. Shafer, MD; Mitchell C. Shultz, MD; Stephen G. Slade, MD, FACS; and Dagny C. Zhu, MD.



LISTEN NOW



SECTION EDITOR ERIC ROSENBERG, DO, MSCENG

■ Cornea and complex anterior segment surgeon, SightMD, Babylon, New York

- Assistant Professor, New York Medical College, Valhalla, New York
- Member, EyeTube Editorial Board

- ericr29@gmail.com
- Financial disclosure: None