

CRST MILLENNIALEYE

Cataract & Refractive Surgery Today

NEUROTROPHIC KERATITIS:

A "Rare Disease" Yet
Common Problem

FACULTY:

Francis S. Mah, MD

Marjan Farid, MD

Sumitra Khandelwal, MD

Elizabeth Yeu, MD

A continuing medical education activity provided by Evolve Medical Education LLC.
This activity is supported by an unrestricted educational grant from Dompé.

Provided by



Neurotrophic Keratitis: A “Rare Disease” Yet Common Problem

Release Date: October 2021
Expiration Date: October 2022

FACULTY



FRANCIS S. MAH, MD

Program Chair

Director, Cornea and External Disease
Co-Director, Refractive Surgery
Scripps Clinic
La Jolla, CA



MARJAN FARID, MD

Professor of Ophthalmology
School of Medicine
Vice Chair, Ophthalmic Faculty
Director, Cornea/External Disease, Cataract,
and Refractive Surgery
Gavin Herbert Eye Institute
University of California, Irvine
Irvine, CA



SUMITRA KHANDELWAL, MD

Associate Professor
Medical Director, Lions Eye Bank of Texas
Cornea, Cataract, and Refractive Surgery
Baylor College of Medicine
Houston, TX



ELIZABETH YEU, MD

Virginia Eye Consultants
Medical Director, CVP Mid-Atlantic
Cornea, Cataract, External Disease, and
Refractive Surgery
Assistant Professor
Department of Ophthalmology
Eastern Virginia Medical School
Norfolk, VA

CONTENT SOURCE

This continuing medical education (CME) activity captures content from a live symposium.

ACTIVITY DESCRIPTION

Based on a live satellite symposium held during the American Society for Cataract and Refractive Surgeons Annual Meeting, this supplement summarizes the presentations on the stages of neurotrophic keratitis and the available treatments.

TARGET AUDIENCE

This certified CME activity is designed for ophthalmologists.

LEARNING OBJECTIVES

Upon completion of this activity, the participant should be able to:

- **Identify** the stages of neurotrophic keratitis
- **Recognize** how to differentiate neurotrophic keratitis from similar diseases
- **Describe** the mechanisms of action of newer treatments and when they should be introduced into treatment regimens for neurotrophic keratitis, including the stepwise approach
- **Explain** the relationships between disease characteristics, drug therapies, treatment frequency, visual, and anatomic outcomes

GRANTOR STATEMENT

This activity is supported by an unrestricted educational grant from Dompé.

ACCREDITATION STATEMENT

Evolve Medical Education LLC (Evolve) is accredited by the Accreditation Council for Continuing Medical Education (ACCME) to provide continuing medical education for physicians.

CREDIT DESIGNATION STATEMENT

Evolve designates this enduring material for a maximum of 1 AMA PRA Category 1 Credit™. Physicians should claim only the credit commensurate with the extent of their participation in the activity.

TO OBTAIN CREDIT

To obtain credit for this activity, you must read the activity in its entirety and complete the Pretest/Posttest/Activity Evaluation/Satisfaction Measures Form, which consists of a series of multiple-choice questions. To answer these questions online and receive real-time results, go to <https://evolvemeded.com/course/2132-supp>. Upon completing the activity and self-assessment test, you may print a credit letter awarding 1 AMA PRA Category 1 Credit™. Alternatively, please complete the Posttest/Activity Evaluation/Satisfaction Form and mail or fax to Evolve Medical Education LLC, 353 West Lancaster Avenue, Second Floor, Wayne, PA 19087; Fax: (215) 933-3950.

DISCLOSURE POLICY

It is the policy of Evolve that faculty and other individuals who are in the position to control the content of this activity disclose any real or apparent conflicts of interest relating to the topics of this educational activity. Evolve has full policies in place that will

identify and resolve all conflicts of interest prior to this educational activity.

The following faculty/staff members have the following financial relationships with commercial interests:

Francis S. Mah, MD, has had a financial agreement or affiliation during the past year with the following commercial interests in the form of *Consultant*: Alcon Vision, Allergan, Bausch + Lomb, Eyenovia, Glaukos, iView, Johnson & Johnson Vision, Nevakar, Novartis, Ocular Science, and RxSight.

Sumitra Khandelwal, MD, has had a financial agreement or affiliation during the past year with the following commercial interests in the form of *Consultant*: Alcon Vision, Bausch & Lomb, Carl Zeiss Meditec, Dompé, Novartis, and Ocular Therapeutix.

Marjan Farid, MD, has had a financial agreement or affiliation during the past year with the following commercial interests in the form of *Consultant*: Allergan, Bausch + Lomb, BioTissue, Carl Zeiss Meditec, CorneaGen, Dompé, Tarsus, Orasis, Johnson & Johnson Vision, Kala Pharmaceuticals, Novartis, and Sun Pharmaceutical Industries.

Elizabeth Yeu, MD, has had a financial agreement or affiliation during the past year with the following commercial interests in the form of *Consultant*: Alcon Vision, Allergan, Avedro, Bausch + Lomb, BioTissue, Beaver Visitec, BlephEx, Bruder, Carl Zeiss Meditec, CorneaGen, Dompé, Expert Opinion, EyePoint Pharmaceuticals, Guidepoint, Johnson & Johnson Vision, Kala Pharmaceuticals, Lensar,

Merck, Mynosys, Novartis, Ocular Science, Ocular Therapeutix, Ocusoft, Omeros, Oyster Point Pharma, Science Based Health, Shire, Sight Sciences, Sun Pharmaceutical Industries, Surface, Thea, Tarsus, TopCon, TearLab, Visus Therapeutics. *Grant/Research Support*: Alcon Vision, BioTissue, Ocular Science, TopCon, and TearLab. *Stock/Shareholder*: BlephEx, CorneaGen, Melt, Ocular Science, Oyster Point Pharma, and Tarsus.

EDITORIAL SUPPORT DISCLOSURES

The Evolve staff and planners have no financial relationships with commercial interests. Michelle Dalton, writer, and Nisha Mukherjee, MD, peer reviewer, have no financial relationships with commercial interests.

OFF-LABEL STATEMENT

This educational activity may contain discussion of published and/or investigational uses of agents that are not indicated by the FDA. The opinions expressed in the educational activity are those of the faculty. Please refer to the official prescribing information for each product for discussion of approved indications, contraindications, and warnings.

DISCLAIMER

The views and opinions expressed in this educational activity are those of the faculty and do not necessarily represent the views of Evolve, *Cataract & Refractive Surgery Today*, *MillennialEYE*, or Dompé.

DIGITAL EDITION

To view the online version of the material, go to <https://evolvemedical.com/course/2132-suppl>.



PRETEST QUESTIONS

PLEASE COMPLETE PRIOR TO ACCESSING THE MATERIAL AND SUBMIT WITH POSTTEST/ACTIVITY EVALUATION/
SATISFACTION MEASURES FOR CME CREDIT.

1. Please rate your confidence in your ability to describe the mechanisms of action of newer treatments and when they should be introduced into treatment regimens for neurotrophic keratitis (NK) (based on a scale of 1 to 5, with 1 being not at all confident and 5 being extremely confident).
 - a. 1
 - b. 2
 - c. 3
 - d. 4
 - e. 5
2. A 52-year-old female with history of LASIK OU, pars plana vitrectomy OS, and herpes keratitis OS is referred by her regular optometrist for decreased vision during the past few months in the left eye despite intensive therapy. Vision is 20/20 OD and 20/200 OS. IOP is 15 mm Hg in both eyes. Slit lamp examination of the right eye reveals a well healed LASIK flap but is otherwise unremarkable. The left eye has a 3 x 4 mm epithelial defect with mild stromal haze, diffuse corneal staining outside the defect, and a mild anterior segment reaction. Qualitative testing of corneal sensation shows decreased sensation in the left eye. Fundus examination is normal in the right eye and a B-scan is unremarkable in the left eye. Based on the patient's history and clinical evaluation, this presentation appears to be consistent with neurotrophic keratitis. According to the Neurotrophic Keratitis Study Group, this patient has what stage of disease?
 - a. Stage 1
 - b. Stage 3
 - c. Stage 4
 - d. Stage 5
3. Corneal innervation is essential for good epithelial health. How do corneal nerves maintain a healthy corneal surface?
 - a. Provide stromal, epithelial, and Bowman's structural support
 - b. Maintain sensory functions that are essential to tear film maintenance
 - c. Facilitate protective functions of blinking and tear production as well as trophic support
 - d. Provide key nutrients to the epithelium while also serving as a physical barrier to microbes
4. The Mackie Neurotrophic Keratitis Classification System breaks neurotrophic keratitis into three stages. Recently, the Neurotrophic Keratitis Study Group has developed a new 7-step staging system. The purpose for this new system is:
 - a. To replace an outdated system
 - b. To allow for more accurate monitoring of progression of the disease as well as delineate which patients may respond well to particular therapies and evaluate response to treatment
 - c. To better educate patients about their disease and help them understand the prognosis and possible consequences of the condition
 - d. Determine which patients need amniotic membrane grafting
5. Endogenous nerve growth factor helps preserve and restore the ocular surface by which of the following mechanisms?
 - a. Strengthening tight junctions between epithelial cells to enhance corneal epithelial barrier functions.
 - b. Providing nutrition to conjunctival goblet cells and eyelid tear glands in order to increase tear production and improve tear quality.
 - c. Stimulating limbal stem cells to generate new epithelial cells.
 - d. Increasing tear production at the lacrimal gland, stimulating nerve regeneration, and supporting epithelial cell proliferation and differentiation.
6. According to the Mackie Severity Classification for NK, all but which clinical feature is classified as Stage 1?
 - a. Punctate epitheliopathy
 - b. Stromal opacity
 - c. Decreased tear break-up time
 - d. Stromal haze
7. Ms. Smith is referred into your clinic for a dry eye evaluation. She has a history of type 2 diabetes, proliferative diabetic retinopathy, and bacterial corneal ulcers with poor healing that required penetrating keratoplasty; 2 months later the epithelium has not yet healed. Previous treatments included antibiotics, steroids, bandage contact lenses, and self-retaining amniotic membrane. Corneal sensitivity testing reveals centrally absent sensation. What would be considered an appropriate next step?
 - a. Continue with Prokera
 - b. Increase steroid-free artificial tears to 5 times daily
 - c. Initiate a 6-week course of cenegermin 8 times daily
 - d. Initiate an 8-week course of cenegermin 6 times daily
8. _____ is the only way to diagnose NK.
 - a. Visual acuity testing
 - b. *In vivo* confocal microscopy
 - c. Corneal sensation testing
 - d. Imaging with a slit lamp
9. Which of the following systemic conditions has been shown in studies to exacerbate NK?
 - a. Diabetes
 - b. Multiple sclerosis
 - c. Leprosy
 - d. Congenital syndromes
 - e. All of the above
 - f. None of the above
10. In the REPARO clinical study, _____ of patients who achieved corneal healing remained healed 48 weeks after completing one full course of treatment with cenegermin.
 - a. 40%
 - b. 60%
 - c. 80%
 - d. 100%

Neurotrophic Keratitis: A "Rare Disease" Yet Common Problem

Neurotrophic keratitis (NK) is characterized by decreased or absent corneal sensation, which can lead to epithelial breakdown, impairment of healing, and ultimately, to the development of corneal ulceration, melting, and perforation.¹ This rare, degenerative disease (affecting fewer than 65,000 people in the United States²) is ultimately caused by trigeminal nerve damage, which, in turn, causes the loss of corneal sensitivity.³ NK remains a challenge to successfully diagnose and treat—systemic conditions including diabetes, multiple sclerosis, congenital syndromes, and leprosy have also been associated with the development of corneal anesthesia,⁴ which can make diagnosis more difficult. Treating NK should be prompt and based on the stage and severity of the disease. Despite various medical and surgical therapies having been proposed, NK remains difficult and challenging to treat, and the lack of positive response is commonly observed in the clinical practice.⁵ We've brought together corneal experts to discuss this disease and offer case-based examples.

— Francis S. Mah, MD, Program Chair

INTRODUCTION

Q | DR. MAH: NK is a real problem we face as cornea specialists. Why is it so important to identify it?

Marjan Farid, MD: NK is classified as a rare/orphan disease, but it is actually more prevalent than I thought. The current prevalence estimate is five or less individuals in 10,000.⁶ Its true prevalence is difficult to determine because many mild cases are missed. Even in that mild phase, and certainly in the later stages, it can be visually significant. NK is a degenerative corneal disease that includes damage to the trigeminal nerve (cranial nerve V), loss of corneal sensation, breakdown of the corneal epithelium, impaired corneal healing, and persistent epithelial defect, which leads to corneal ulceration, stromal melting, and perforation.³ If you don't identify it and treat it quickly, it can cause subepithelial scarring, fibrosis, and long-term visual sequelae.

Dr. Mah: That vision-threatening issue is obviously critical. Because of the neurotrophic component, many patients don't realize how serious the issue is. Have you started noticing an increase in the number of patients with NK?

Dr. Farid: Yes, I have noticed an increase. Diabetes plays a large role in exacerbating any underlying etiologies of NK. I have patients with severe diabetes and renal disease and their corneas look terrible. I'm definitely seeing it more as I look for it, and I'm able to address in earlier with our newer therapies.

Dr. Mah: I'm also looking for it more than I did previously. I'm testing corneal sensitivity in anyone who comes in for ocular surface disease or consult for dry eyes. Many of these patients have NK.

Sumitra Khandelwal, MD: It has been a surprise to me that once you start having NK in your differential diagnosis, you start seeing it more in your clinic. I agree with Dr. Mah; I'm testing

anyone with ocular surface issues and finding that decreased sensation is more common than we think.

DIAGNOSING NEUROTROPHIC KERATITIS

Dr. Farid: Testing or checking corneal sensation is the only way to diagnose NK because it's an issue with the trigeminal nerves in the cornea. Patients with NK don't receive that biofeedback to the brain to have good healthy tears, to have the epithelial growth factors released by the nerve endings, and so on.^{5,7} If you don't test that corneal sensation, you won't clinch the diagnosis.

I always checked corneal sensation as a resident and fellow, but that fell to the wayside in a busy clinical practice. It's important to bring corneal sensation testing back to the forefront. We need to educate our technicians and ancillary staff and remind them not to use topical anesthetic solution in patients who are suspicious for NK. If they do, you must bring the patient back and obtain that sensation testing. Remember, patients won't complain of pain; it's the visual disturbance they notice.

Q | DR. MAH: Let's say you do notice there's some decreased corneal sensation, how do you educate the patients on the condition?

Dr. Farid: I relate it to a diabetic foot ulcer. I tell patients that, like patients with diabetic foot ulcers, they won't feel pain when they have an eye ulceration. It's quite dangerous because it can become infected. If we don't treat it, it can scar and affect long-term vision. With that little bit of education, patients are much more willing to adhere to treatment.

Dr. Khandelwal: I educate patients about the importance of follow-up for any change in symptoms. I tell them "the body doesn't heal what it doesn't feel" and this is why it is important to address this challenge even though it doesn't cause them discomfort.

Dr. Mah: The classic NK schema, the Mackie Severity Classification, was described decades ago.⁸ The Mackie Classification includes three stages. A new definition and schema have been proposed that increase the number of stages to six and includes education on how to differentiate it from similar diseases.

Elizabeth Yeu, MD: Do you think it really affects fewer than five people per 10,000?

Dr. Farid: I think perhaps in the stage 2 and 3, the numbers are low. But I think there's a great deal of stage 1 or early disease that is missed.

Dr. Yeu: I agree. Moderate to severe classes of NK should be in the rare category. There are two types of patients on opposite ends of the spectrum: patients with a ton of pain without corneal stain (keratoneuralgia, corneal neuropathic pain) and patients with no pain and a lot of significant keratopathy. Some diseases, such as severe chronic dry eye disease, contact lens-related disorders, blepharitis, stem cell deficiency, topical drug toxicity, and exposure keratopathy, have overlapping features of NK and corneal sensation can be affected.^{2,6} By definition, there's a degeneration of the nerves, whether it's iatrogenic or not, that leads to a vicious cycle, including a breakdown of the corneal epithelium (Figure 1). That breakdown without the neural triggers prevents the actual growth factors from coming in naturally to reepithelialize naturally.

The cornea is the most sensitive and densely innervated tissue in the human body.^{5,7} Corneal innervation is essential. Corneal epithelial cells act in a mutually supportive relationship with corneal nerves, which maintain corneal integrity; it provides the reason for us to actually blink and tear.⁶ Corneal nerve damage leads to loss of corneal sensation, epithelial breakdown, and poor healing.^{5,7} When we lack corneal sensation, we're not performing those motor skills of blinking and refreshing the tear and preventing the desiccation.

Risk factors for NK include infections such as herpes, systemic diseases such as diabetes, contact lens use, and fifth-nerve palsy due to trigeminal neuralgia and surgery. Chronic comorbidities such as dry eye, blepharitis, topical drug toxicity, and contact lens-related disorder may worsen the prognosis of NK.²

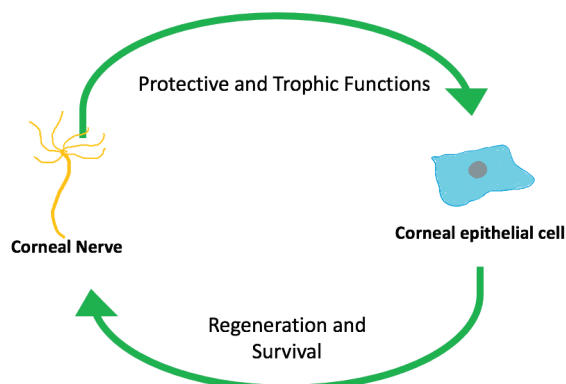


Figure 1. The cycle of neurotrophic keratitis.^{5,7}

Many patients will present to you for a routine follow-up exam, and their eyes don't look that red. They may come in for evaluation of "blurrier vision" that is progressively worsening in the last 3 to 4 days. On clinical presentation, they have decreased sensation with or without pain; corneal epithelium irregularities with or without epithelial defect; stromal involvement that is usually oval in shape with smooth and rolled edges; and corneal ulcer, melting, and perforation.²

A large part of diagnosing NK is taking a thorough clinical history followed by an examination checking for corneal sensitivities. Corneal staining, corneal cultures, *in vivo* confocal microscopy, and Schirmer, which can be impaired as a result of reduction in corneal sensitivity, are also helpful.² Corneal sensitivity tests can be qualitative or quantitative. Qualitative examples include a cotton swab, cotton wisp, dental floss, or tissue tip. Quantitative is often used in basic research and clinical trial settings with, for example, the Cochet-Bonnet esthesiometer.² I use a cotton wisp, checking their blink response in both eyes and ask how they feel.

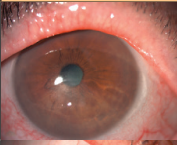

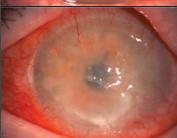
Dr. Khandelwal: It is interesting because once I come close to the patient and check their sensation in both eyes, they suddenly understand there is something wrong with their corneas, especially in unilateral cases. Then we go back in time and discuss how their signs and symptoms of blurry vision or recurrent infections do not correlate with their pain. I agree with all the testing options, although in a busy clinic a qualitative test like cotton swab is quick and easy.

Dr. Mah: I also use qualitative methods with a cotton swab.

Dr. Farid: I use cotton swabs as well. You can also use plain dental floss or a sterile Gore-Tex suture.

Dr. Yeu: Regarding staging, the Mackie Severity Classification of NK has been well documented, but honestly, not many of us use it (Table 1).^{6,8} With stage 1, there is no defect. The patient may have epithelial erosions and decreased tear break-up time. There may

TABLE 1. MACKIE SEVERITY CLASSIFICATION FOR NEUROTROPHIC KERATITIS.^{6,8}

Stage	Clinical Features	
1	<ul style="list-style-type: none"> • Punctate epitheliopathy (punctate corneal fluorescein/ lissamine green staining) • Decreased tear break-up time • Stromal haze 	
2	<ul style="list-style-type: none"> • Persistent epithelial defect with smooth rolled edges • Stromal opacity 	
3	<ul style="list-style-type: none"> • Stromal thinning/ulceration • Corneal perforation 	

be stromal haze from either old scarring or devitalized epithelium that is giving off the perception of haze, but there's not an overt epithelial defect. In stage 2, the patient has a persistent epithelial defect with heaped-up edges; stromal opacity may or may not exist. When a patient gets to stage 3, there is true stromal thinning with potential perforation.

Q | DR. YEU: In your experiences, what are some of the loopholes in the Mackie Severity Classification?

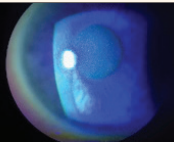

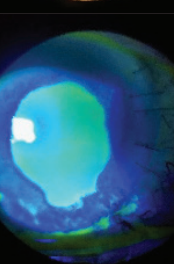
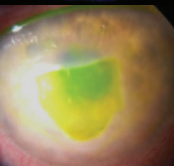
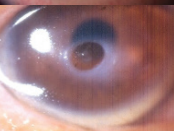

Dr. Farid: It's still very limited; we have patients who are in between these stages. We have patients who have a new persistent epithelial defect without any long-standing subepithelial haze, versus the ones where its edges are more chronic and where there's subepithelial haze and scarring. So even within stage 2, we have degrees of severity that are not caught by this classification.

Dr. Mah: The biggest issue is the Mackie categories are too broad and nonspecific. The recent advent of more effective treatment options has necessitated a more highly defined staging system that better reflects the evolution of the disease and alerts clinicians to the earlier stages of NK. The Neurotrophic Keratitis Study Group (NKSG) has worked to separate the differences so treatment can begin earlier before there's vision loss.

Dr. Yeu: Adding stages makes sense. Stage 2, in particular, is too broad. Just like we can have marginally compensated corneas, you can have a marginally compensated neurotrophic disease that breaks down because of some other comorbid state. You can also have someone who has zero sensation after trigeminal neuralgia surgery. Because of the zero sensation, they're rapidly and more aggressively declining. Stage 2 can include a spectrum, which is why the Mackie Classification may not be overly helpful to clinicians. To address this, the NKSG has proposed a new 7-step clinical staging system (Table 2) to more precisely classify the signs and symptoms of NK, allowing for earlier diagnosis, earlier recognition of where they are in their process, and identifying the underlying etiology or etiologies. The underlying etiology may impact their response to treatment.

The NKSG staging system, which is currently unpublished, starts with stage 0, which is altered sensation without corneal findings. Stage 1 is mild NK, including epitheliopathy without stromal haze. Stage 2 includes epitheliopathy with stromal haze. That stromal haze may be from chronic edema, which can lead to that difficulty with deturgescence of the cornea leading to the haze. It can also be haze secondary to infiltrate or early white blood cell recruitment, which could indicate that there is a kind of superinfection that is going on. Stage 3, severe disease, includes persistent or recurrent epithelial defects. Stage 4 is much more severe and also includes persistent or recurrent epithelial defect, but with stromal scarring without corneal ulceration. In stage 5 disease, the patient has persistent or recurrent epithelial defect with corneal ulceration. Finally, the last stage, stage 6, is corneal perforation.

TABLE 2. NEUROTROPHIC KERATITIS STUDY GROUP 7-STEP CLINICAL STAGING SYSTEM.

Stage	Clinical Features	Imaging
0	Altered sensation without keratopathy	
1 (mild)	Epitheliopathy without stromal haze	
2 (moderate)	Epitheliopathy with stromal haze	
Stage 3 (severe)	Persistent or recurrent epithelial defects	
Stage 4 (severe)	Persistent or recurrent epithelial defect and stromal scarring without corneal ulceration	
Stage 5 (severe)	Persistent or recurrent epithelial defect with corneal ulceration	
Stage 6 (severe)	Corneal perforation	

This new classification system gives you a better sense of where they are in that disease process. Patient history is going to be key in understanding the iatrogenic causes of NK and how not to further exasperate it. These patients can turn into that superimposed or secondary infection rather quickly.

Dr. Khandelwal: It is so important to recognize these stages can progress quickly. I have seen patients with stage 1 disease that are completely neurotrophic progress to stage 3 within weeks on the Mackie classification, so the NKSG staging will hopefully provide us with more data on each patient.

TREATMENTS FOR NEUROTROPHIC KERATITIS

Dr. Mah: NK requires severity-based therapy (Table 3).^{2,7} Going back to the Mackie Classification, which includes three stages, treatment for stage 1 disease is similar to dry eye management with the use of preservative-free artificial tear formulations. Patients with stage 1 disease present with blurred vision and vision fluctuation. They have some punctate epithelial keratopathy, a little bit of corneal edema, and there may be a little stromal scarring. But for all intents and purposes, they look like they've got an epitheliopathy that could be consistent with dry eyes. That's why it's critical to test patients for corneal sensitivity.^{2,7} In addition to artificial tears, you can use punctal occlusion, hydrogel contact lenses, human recombinant nerve growth factor (rhNGF) or cenegermin, and serum drops, plasma, or platelet-rich plasma (PRP).

TABLE 3. SEVERITY-BASED THERAPY FOR NEUROTROPHIC KERATITIS BASED ON MACKIE CLASSIFICATION.^{2,7}

Stage	Therapy
1	<ul style="list-style-type: none"> • Preservative-free artificial tears formulations • Punctal occlusion • Hydrogel contact lens (consider large diameter) • Recombinant human NGF (rhNGF, cenegermin) • Serum/plasma/platelet-rich plasma
2	<i>Supportive therapies plus:</i> <ul style="list-style-type: none"> • rhNGF • Scleral lens (\pm serum/plasma) • Amniotic membrane • Botulinum-induced ptosis, tarsorrhaphy
3	<ul style="list-style-type: none"> • rhNGF • Keratoplasty + scleral lens, tarsorrhaphy, neurotization

Patients with Mackie Classification stage 2 disease have an epithelial defect. They may have a bit of edema and a little scarring, but they do not have melting or excavation of the stroma. Potential therapies include rhNGF and scleral lenses, plus or minus serum or PRP. Amniotic membrane, self-retained or sutured or glued, and botulinum-induced ptosis or tarsorrhaphy, are other therapeutic choices.^{2,7}

Stage 3 disease comes with stromal melting and the potential for corneal perforation. If the cornea is already perforated, then we would think about cyanoacrylate glue for smaller (<2 mm) perforations or tectonic keratoplasty then rhNGF. For significant corneal stromal melting keratoplasty might be an option, scleral lenses, tarsorrhaphy, and neurotization are other possible treatments.^{2,7}

Dr. Khandelwal: Oftentimes, treatment is a combination of all of the options Dr. Mah discussed. In addition, there is not always a reason to wait for more advanced stages to begin treatments like cenegermin or scleral lenses. For example, I may see a patient with any stage disease and decide that a course of cenegermin followed by scleral lenses to help their vision and protect the

cornea is the best course. For others, I may do a more stepwise approach with cenegermin and medical management with drops or amniotic membrane. Each case is unique and often based on what the patient can tolerate.

Serum and plasma as primary or adjunct therapy

Dr. Mah: Serum and plasma have reported efficacy as primary or adjunct therapy in these patients. The reported success of serum alone at 20 to 50% concentration ranges from 71 to 100% within 90 days.⁹⁻¹¹ It's very successful for stage 1 NK. Umbilical cord serum may be more effective, as it has a higher concentration of substance P as well as NGF and peripheral blood serum.^{12,13} In one case series, epithelial defects healed 97.4% in stage 2 and stage 3 NK after 11 weeks of plasma rich in growth factors. Serum can be used safely in combination with a silicone hydrogel contact lens; no inflammation or contact lens deposits were observed in a study by Choi et al.¹⁴

Q | What are your experiences with serum and the plasma-rich platelets?

Dr. Farid: I use serum generously in my patients. I can get serum into the hands of my NK patients quickly while waiting for rhNGF. I use a company called Vital Tears, of which I have no financial interest. They've systematized the whole process and come to the patient's home to draw blood. Their turnaround time is usually 2 to 3 days. Serum can be formulated at 100%, 75%, 50%, or 20%. I usually start around 50 to 75%, and then lower the percentage once the patient improves.

Dr. Yeu: I don't have much experience with plasma-rich protein therapy. I do think serum tears are excellent in the management of neurotrophic disease and epithelial defects. I don't see serum tears as helpful for dry eye, necessarily, but they are extremely useful in combination with other medical therapies and scleral lenses. I typically start with a serum concentration between 20 and 50%, and increase the concentration, if needed.

Amniotic membrane transplantation

Dr. Mah: Amniotic membrane transplantation (AMT) has been a godsend for ocular surface disease specialists. In randomized clinical trials, there have been reports of refractory neurotrophic ulcers healing with conventional therapies such as lubrication plus bandage contact lens or tarsorrhaphy versus AMT. Healing rates were similar in the two groups: 67% with conventional therapy and 73% with AMT.¹⁵ AMT is also equivalent to serum tears in healing neurotrophic ulcers (70% for the serum tears vs 73% for AMT).¹⁶ Multilayer AMT is recommended for deep ulcers and descemetoceles and building up the layers for the stroma.¹⁷ What are your experiences with amniotic membrane?

Dr. Yeu: Cryopreserved AMT is extremely uncomfortable for some patients, but neurotrophic patients are generally very comfortable because they lack ocular surface sensation. I like to

begin with the Prokera Slim (Bio-Tissue), because that helps with comfort.¹⁸ I always ensure a protective ptosis by performing a tape tarsorrhaphy across the upper lid using sterile strips. The cryopreserved AMT usually lasts about a week unless the patient's eye is really hot and angry. If it looks like they need a second, I will repeat it with a conventional one with the thicker amniotic membrane. If that strategy doesn't work, then I'll consider something more permanent, like a pillar or lateral tarsorrhaphy.

Dr. Farid: I agree. Cryopreserved AMT tends to have more of the antiinflammatories and the regenerative properties. Although it can be uncomfortable, NK patients don't feel it in their eyes, so you can repeat it. I use the Prokera Plus (Bio-Tissue), which has a double layer and longer use.

Dr. Khandelwal: There are some patients with NK that I have found are very sensitive to the symblepharon ring that cryopreserved amniotic membrane graft (AMG) is on. For these patients, you can cut out the AMG and glue it using Tisseal or even place under a bandage lens or scleral lens.

Scleral lenses

Dr. Mah: Scleral lenses are another excellent technique for these patients. It takes a little more time because they must be fit properly so it's not really an option for a rapidly evolving or urgent/emergent situation. To optimize success, corneal specialists need a contact lens fitting specialist nearby who can perform the scleral lens fitting. But it is a fantastic long-term solution, especially for patients who have recovered from stage 2 or stage 3 NK with some corneal scarring. The use of fluid-filled scleral contact lens for the treatment of NK was initially reported decades ago.¹⁹ Ling et al reported that nonhealing corneal epithelial defects healed without recurrence in all nine eyes treated with the PROSE scleral lens.²⁰ Overnight wear with close monitoring may accelerate healing.

Q | What are your experiences with scleral lenses?

Dr. Farid: Scleral lenses are a great option. In the acute phases, it's sometimes challenging to get a scleral lens for these patients. But it can work very well long term for visual rehabilitation.

Dr. Khandelwal: At our practice, we have an extra set of PROSE lenses which we can use for a patient to get them through a nonhealing epithelial defect, similar to the previous mentioned studies. But not all practices will have this option.

Dr. Yeu: I've found that it's extremely helpful to add something inside the bed of the scleral lens, such as one drop of antibiotic, either serum tears or amniotic cytokine extract. It helps the patient reepithelialize relatively quickly, so long as they don't have endothelial dysfunction. I wouldn't use it in patients with endothelial disease because they can't pump out the fluid that's within the scleral lens.

Dr. Mah: Corneal neurotization is a newer technique where corneal sensitivity is resorted after sural nerve grafts.²¹ It's a procedure where there's a free sural nerve graft that is coapted end-to-side with the supratrochlear nerve. The distal portion of the nerve is separated into fascicles and distributed around the limbus. The thought is, if the patient doesn't have sensation because of the sensory nerves being damaged or deadened, then why not produce or supply new nerves to the cornea? A study by Elbaz found that corneal sensitivity measured pre- and postoperatively with the Cochet-Bonnet esthesiometer returned to normal after 5 months.²¹ The procedure is very long and arduous, requiring multiple specialties.

Q | Has anyone used corneal neurotization?

Dr. Farid: It's long, arduous, and requires a multidisciplinary team approach to the surgery. But anecdotally, it has been done with success in extremely severe cases.

Dr. Yeu: I also have no personal experience with it, but I have heard results can be very good.

Dr. Mah: It appears to be a nice possibility for some patients with very severe disease who are recalcitrant to every other intervention.

Dr. Khandelwal: We have performed this procedure at our center—it is an invasive procedure, so using alternate treatment first is ideal. However, for cases that do not improve with cenegermin or patients who are unable to use scleral lenses, this can be an excellent treatment. In the beginning, the surgery was performed with neurosurgery. However, our oculo-plastics specialists now use cadaver donor nerve tissue that allows it to be performed just by them. It is important the patient understand the sensation takes months to return, so they will still need a scleral lens or tarsorrhaphy for a while. In addition, for cases in which there is also lack of sensation on the lids or forehead, a contralateral nerve dissection, which is more invasive, may be needed as well.

Cenegermin: A new treatment for neurotrophic keratitis

Dr. Mah: Cenegermin is an ophthalmic solution containing 20 µg/mL of rhNGF. It is the first US FDA-approved therapy for NK and should be considered a first-line option for NK treatment.²²

As a recumbent form of NGF, cenegermin acts through specific high-affinity (ie, TrkA) and low-affinity (ie, p75NTR) NGF in the anterior segment of the eye to support corneal innervation and integrity through three mechanisms of action.³ First, NGF stimulates the regeneration and survival of sensory nerves.^{2,23} Second, NGF helps with receptors on the lacrimal glands and promotes sensory-mediated reflex tearing secretions.²⁴ Third, NGF maintains corneal integrity through cell proliferation and differentiation and survival of the corneal epithelial cell.³ The active ingredient of cenegermin is structurally identical to hNGF and naturally occurring.

Neurotrophin is responsible for differentiation, growth, and maintenance of neurons. It is structurally identical and discovered by Nobel Prize-winning scientists in the early 1950s.²⁵ Efficacy was established in two different studies, one from the United States (NGF0214) and one from Europe (REPARO).²⁶⁻²⁸ Both trials led to the FDA approval of cenergermin. NGF0214 showed complete corneal healing in up to 65.2% of patients receiving cenergermin six times a day or every 2 hours for a total of 8 weeks. The endpoint was complete epithelial healing with no epithelial defect. Every patient in both studies had at least stage 2 or stage 3 NK, meaning they had at least an epithelial defect. REPARO had a slightly different endpoint, which was a reduction in the size of the epithelial defect to less than 0.5 mm. In REPARO, 80% of patients who achieved complete corneal healing remained healed 48 weeks after completing one 8-week cenergermin treatment cycle.²⁶ This is very encouraging and remarkable.

As far as the pooled safety reports, there were no serious treatment-related adverse reactions to the treatment. I do like to prepare my patients for the treatment regimen since it's so intense. A small proportion of patients, about 16%, experience some eye pain following installation, typically 2 to 3 weeks after beginning treatment. How do you educate your patients on cenergermin treatment?

Dr. Farid: When I put my patients on cenergermin, I spend a lot of time reviewing the instructions. I inform them that they will experience some pain around week 2 or 3. I let them know it's a good thing; it means the nerves are regenerating. I have found that explaining that helps with compliance.

Dr. Mah: The studies concluded that after 8 weeks of 6-times-daily treatment, 65.2% of patients completely healed and up to 80% remained healed for up to a year.²⁶⁻²⁸ These are extremely encouraging data.

CASE 1: NONHEALING EPITHELIAL DEFECT

Dr. Farid: Our first case is a patient referred to me by a colleague in the community. He is a 75-year-old man who had a 3-month history of nonhealing epithelial defect. The referring doctor had gone through all the appropriate treatment regimens with this patient, but the eye would not heal. The patient had bilateral LASIK several years earlier, and when asked about shingles, reported "blistering on one side of the face" about 5 to 6 years ago on the same side as his current epithelial defect. He also mentioned an abrasion about a year earlier that had healed after 2 weeks of aggressive lubrication and antibiotic treatments. These are all red flags for NK.

See Figure 2 for his baseline at presentation to our clinic. At this point, the patient had been treated with two rounds of bandage contact lens therapy as well as a self-retaining cryo-preserved amniotic membrane and then autologous serum. We kept him on antibiotics to ensure there were no preservatives in his system; his medical history included valaciclovir for systemic antiviral

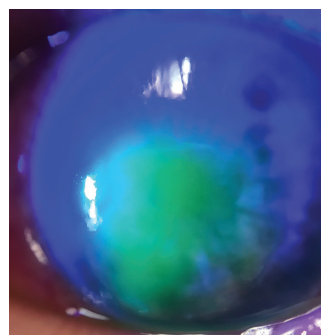


Figure 2. Baseline presentation.

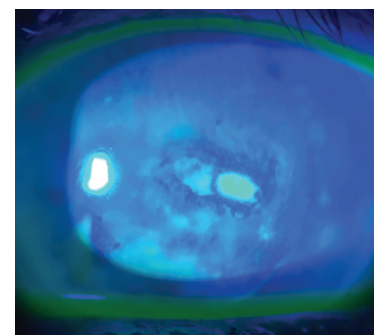


Figure 3. After 4 weeks on cenergermin.

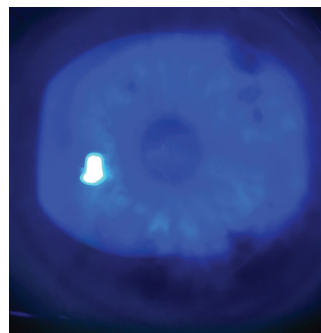


Figure 4. After 8 weeks on cenergermin.

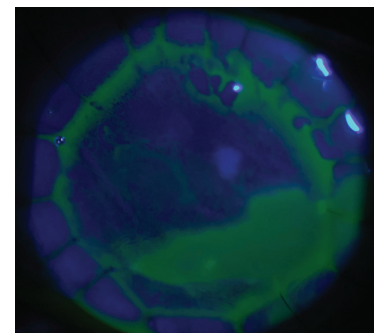


Figure 5. Nonhealing epithelial defect post-PK at baseline.

treatment. The corneal sensitivity testing showed absent sensation on that cornea. By the Mackie Classification, this is stage 2 NK. We prescribed cenergermin, and by 4 weeks on treatment, the epithelial defect had significantly shrunk to about 1 to 2 mm of central opening (Figure 3). By week 8, what I found remarkable was the epithelial defect had completely healed, and there was no other punctate staining on the cornea (Figure 4). He's now 2 years out, and his cornea still looks like it did in Figure 4 with smooth epithelium and a healthy tear film.

CASE 2: NONHEALING EPITHELIAL DEFECT POSTCORNEAL TRANSPLANT

Dr. Farid: Our second case is also one of a nonhealing epithelial defect. This patient, a 78-year-old woman, had undergone a full-thickness penetrating keratoplasty (PK), and developed a nonhealing corneal epithelial defect, with a duration of 8 weeks at presentation (Figure 5). This is certainly atypical, as we expect an epithelial defect posttransplant to heal within the first 1 to 2 weeks. Part of her medical history included diabetes, which as we discussed earlier can exacerbate NK.

We tried all the typical treatments: antibiotic drops, steroids drops for antirejection, bandage contact lenses, self-retaining amniotic membrane, and took her off of all preserved eye drops. Her corneal sensation was decreased as we would expect in a post-PK eye.

We decided to prescribe cenergermin, and you can see in Figure 6 the improvement progression from week 1 through week 8.

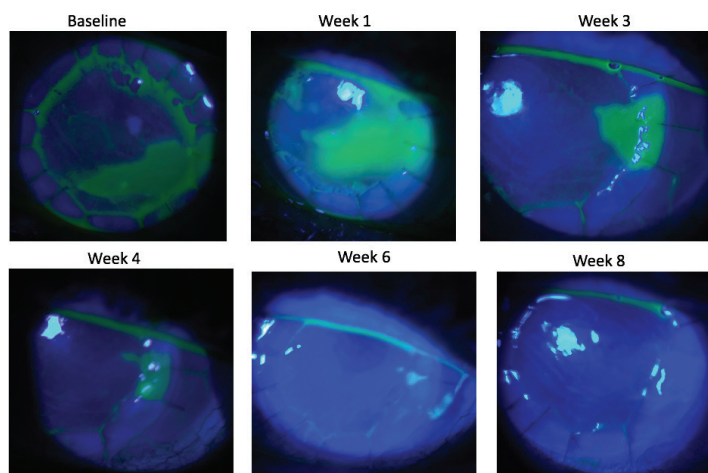


Figure 6. Baseline Through Week 8

Dr. Yeu: Did you use a bandage contact lens alongside treatment, or it was just the cenegermin?

Dr. Farid: That's a great question. So, it's off label to use a contact lens with cenegermin. It's recommended to take off the contact lens to allow the drug to really penetrate into the ocular surface. I'll have these patients in a contact lens early on, but I'll tell them once on cenegermin we need to remove the contact lens during the 8-week course.

Dr. Yeu: This was a beautiful case; it's not often we see that kind of progress for post-PK eyes that have those persistent defects.

Dr. Mah: Have you ever used cenegermin before you were going to do a PK?

Dr. Farid: I haven't yet, unless they have NK. I think it's reasonable to try. You do need to document NK as a diagnosis code in your chart in order for the insurance to kick in and cover the cenegermin.

Dr. Mah: I've used cenegermin after PKs. I wasn't able to treat the NK before the corneal transplant.

CASE 3: STAGE 1 NEUROTROPHIC KERATITIS

Dr. Mah: Our next case is a 45-year-old woman who was referred by a retina colleague. This patient had type 2 diabetes, diabetic neuropathy, and proliferative diabetic retinopathy, which then led to a vitreous hemorrhage, and my colleague performed a pars plana vitrectomy for the vitreous hemorrhage. She was bilaterally pseudophakic because of her diabetes. She wears a contact lens and was being treated for dry eye; my retina colleague tried cyclosporine, lifitegrast, loteprednol, erythromycin ointment, serum tears, and even self-retained amniotic membrane punctal plugs. Believe it or not, her only real complaint before referral into our clinic was that she wanted to see so she could drive. Figure 7 shows her cornea at baseline presentation to us. The whirling pattern almost looks like limbal stem cell failure. Corneal sensitivity was reduced in all quadrants as well as centrally. As I said earlier, I now incorporate corneal sensitivity into all my dry eye referrals/evaluations.

Because this was a bilateral case, I put a Prokera lens in one eye and a bandage contact lens in the other while we were waiting for cenegermin (this was during the clinical trials for cenegermin, so we did not have it readily on hand). We removed the bandage contact lens because that is an off-label use, and prescribed cenegermin for 8 weeks, every 2 hours six times daily. Figure 8 shows the beautiful improvement progression at weeks 4 and 8. At week 4, the central corneal visual axis is clear, which resulted in her improved vision. She still has some punctate erosions, but at 8 weeks there was no corneal staining, which was remarkable. Again, she didn't really complain about pain. Her only complaints were related to her vision. How do you address patients who want to know if they have to take the cenegermin for the full 8 weeks?

Dr. Farid: If you dig into the data from the cenegermin studies, at 4 weeks more than 50% of patients had fully healed, but they remained on the study medication through 8 weeks. So we don't know yet if we'll get the same long-term results with a 4- or 6-week treatment instead.

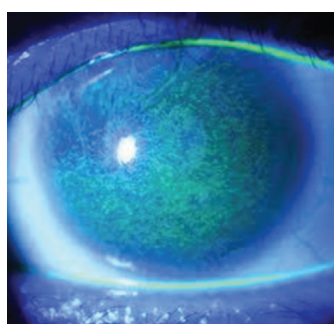


Figure 7. Baseline imaging with a stage 1 neurotrophic keratitis diagnosis.

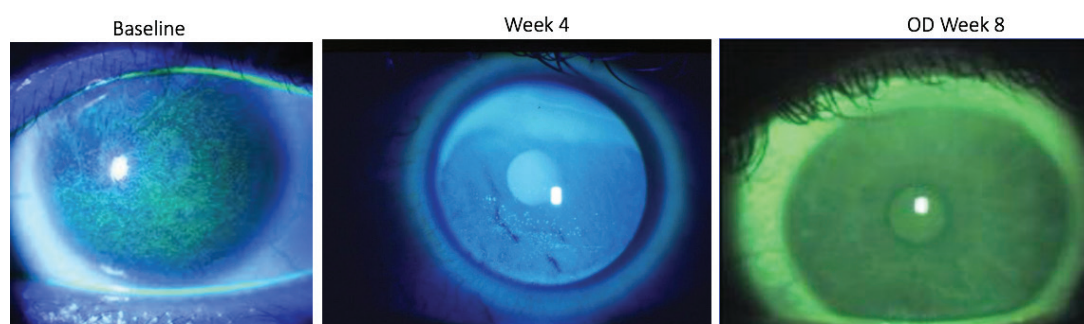


Figure 8. Improvement over time.

Q | DR. MAH: What about the reverse? After 8 weeks, cenegermin proved effective for 72% of the patients, but that leaves 28% who have not healed. Has anyone used more than one round of 8-week treatment?

Dr. Yeu: I'm very bullish about the 8 weeks because I want to regenerate as many nerves as possible. I had a patient who had repeated herpes simplex virus keratitis, epithelial keratitis, and then had the breakdown because of the neurotrophic disease. They were treated with topical trifluridine, which is so toxic it creates its own neurotrophic disease and cycle. If there's still staining after 8 weeks or even a defect, I will try another course. If patients break down again, I'll do another round in the future.

Dr. Mah: I'll also do a second or even third round to get them fully healed.

CASE 4: NONHEALING CORNEAL ULCER

Dr. Khandelwal: This is a 56-year-old man who presents with a nonhealing corneal ulcer that developed after a Descemet stripping endothelial keratoplasty (DSEK) procedure with removal of epithelium. He was treated with fortified antibiotics for several weeks. He was referred into our clinic because of a nonhealing ulcer. His cultures were negative and patient was found to be neurotrophic as well. Our diagnosis was sterile neurotrophic ulcer from weeks of fortified antibiotics. See Figure 9.

Q | What are your thoughts?

Dr. Mah: Once the persistent epithelial defect forms, then the ulcer, obviously it's an urgent matter to get things healed as quickly as possible. It would be interesting to hear if there was anything in the history that could have been a tip off of preexisting NK. Otherwise, obviously, surgery could have been the cause of NK.

Dr. Farid: A neurotrophic ulcer can often be misdiagnosed as infectious and the attempted topical treatment for the infection, whether antibiotics for bacteria or antivirals for herpetic disease, can often worsen the NK ulcer. If the epithelial defect is not improving or responding with the antimicrobials after a week, then the diagnosis of NK has to be considered.

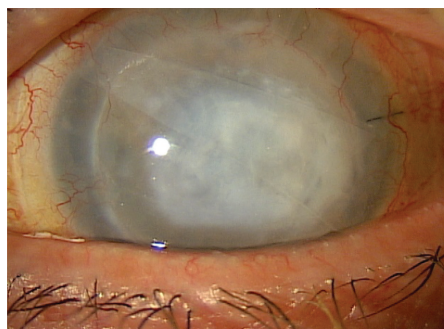


Figure 9. Nonhealing corneal ulcer.

Dr. Khandelwal: There was a suboptimal response, so we next tried amniotic membrane, but that fell off. He's had multiple bandage lenses. We treated the patient with cenegermin six times daily for 8 weeks. To treat

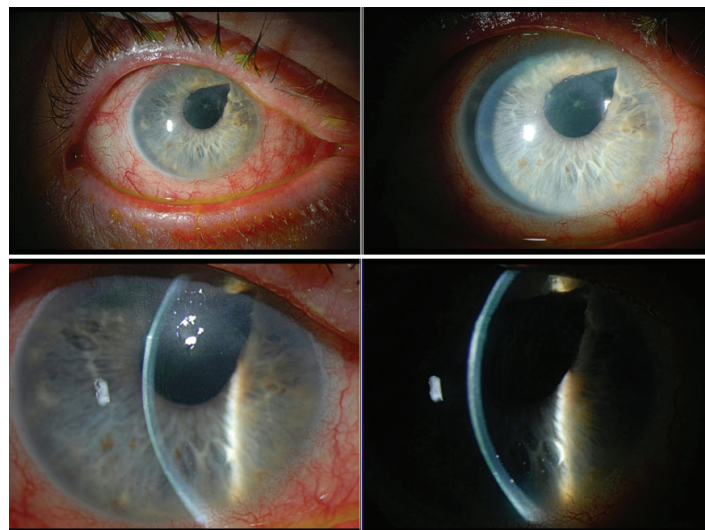


Figure 10. Possible epithelial basement membrane dystrophy.

the scarring, we performed a PK with AMG and tarsorrhaphy. Finally, we removed the tarsorrhaphy and fit the patient with a scleral lens.

Dr. Farid: Complex and slow responding cases like this often require multimodal treatment approaches. The key is to support the ocular surface from further breaking down with protective mechanisms such as scleral lens or tarsorrhaphy while at the same time providing growth factors to regenerate the nerves and the self-healing properties of the cornea.

Dr. Mah: This is a difficult case because the patient underwent a DSEK procedure to improve vision but he had a complication postoperatively that could compromise vision. Most likely, he had some NK prior to the DSEK surgery. If the patient had diabetes mellitus or contact lens wear, or other possible reasons for NK, there is a possibility it could have been identified prior to DSEK, and the surgeon could have pretreated with cenegermin.

CASE 5: LONG-TERM DISEASE

Dr. Khandelwal: Our next case is a 77-year-old man, who presented in May 2020 after 6 months of redness, irritation, and blurry vision in his right eye. He was referred to us for evaluation of possible basement membrane dystrophy. His ocular history includes a retinal detachment in his right eye after pars plana vitrectomy with scleral buckle in 2003. He has bilateral primary open-angle glaucoma. He's pseudophakic, reporting no postoperative complications from cataract surgery. Based on what you see, how would you proceed? (Figure 10.)

Dr. Mah: As we've discussed, I've incorporated corneal sensitivity into all my ocular surface consults. The patient has several reasons to possibly have at least some mild NK.

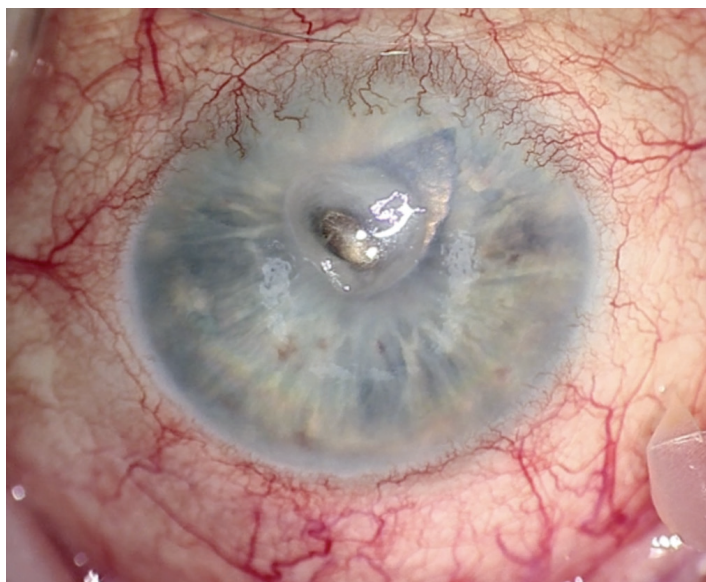

Figure 11. Follow-up exam in June 2020.

Dr. Khandelwal: You're exactly right. This was a patient with stage 1 NK that we started planning to treat. The patient returned about a month later, with worsening symptoms, and we determined he now had stage 3 NK with microperforation. (Figure 11).

Dr. Mah: It's amazing how quickly things can progress, and why it's so important to check and identify possible NK.

Dr. Khandelwal: I agree. In August 2020, we proceeded with layered amniotic membrane with tarsorrhaphy, which solved the acute issues with the descemetocoele with microperforation.

Dr. Farid: I have had several patients that have required PK eventually and I believe that the use of cenegermin for the full 8-week course prior to the keratoplasty significantly improved their postoperative course and healing time. The stem cells and the nerve plexus at the limbus do respond and regenerate so that epithelialization subsequent to a transplant is improved.

Dr. Khandelwal: Once the amniotic graft dissolved, he was started on cenegermin six times daily for 8 weeks. He then

underwent PK without complications. We're still following him, and have plans for repeating cenegermin in the future.

Dr. Mah: Nice job escalating quickly to stabilize the situation. I want to thank the faculty for this incredibly informative discussion. ■

1. Feroze KB, Patel BC. Neurotrophic keratitis. Last updated December 6, 2018. Treasure Island, FL: StatPearls Publishing, 2018.
2. Sacchetti M, Lambiase A. Diagnosis and management of neurotrophic keratitis. *Clin Ophthalmol*. 2014;8:571-579.
3. Mastropasqua L, Massaro-Giordano G, Nubile M, Sacchetti M. Understanding the Pathogenesis of Neurotrophic Keratitis: The Role of Corneal Nerves. *J Cell Physiol*. 2017;232(4):717-724.
4. Bonini S, Rama P, Olzi D, Lambiase A. Neurotrophic keratitis. *Eye (Lond)*. 2003;17(8):989-995.
5. Versura P, Giannaccare G, Pellegrini M, et al. Neurotrophic keratitis: current challenges and future prospects. *Eye Brain*. 2018;10:37-45.
6. Dua HS, Said DG, Messmer EM, et al. Neurotrophic keratopathy. *Prog Retin Eye Res*. 2018;66:107-31.
7. Sheha H, Tighe S, Hashem O, Hayashida Y. Update On Cenegermin Eye Drops In The Treatment Of Neurotrophic Keratitis. *Clin Ophthalmol*. 2019;13:1973-1980.
8. Mackie IA. *Current Ocular Therapy*: WB Saunders, 1995.
9. Guadilla AM, Balado P, Baeza A, Merino M. [Effectiveness of topical autologous serum treatment in neurotrophic keratopathy]. *Arch Soc Esp Ophthalmol*. 2013;88(8):302-306.
10. Jeng BH, Dupps WJ Jr. Autologous serum 50% eyedrops in the treatment of persistent corneal epithelial defects. *Cornea*. 2009;28(10):1104-1108.
11. Pflugfelder SC. Is autologous serum a tonic for the ailing corneal epithelium? *Am J Ophthalmol*. 2006;142(2):316-317.
12. Yoon KC, You IC, Im SK, et al. Application of umbilical cord serum eyedrops for the treatment of neurotrophic keratitis. *Ophthalmology*. 2007;114(9):1637-1642.
13. Sanchez-Avila RM, Merayo-Llodes J, Riestra AC, et al. Treatment of patients with neurotrophic keratitis stages 2 and 3 with plasma rich in growth factors (PRGF-Endoret) eye-drops. *Int Ophthalmol*. 2018;38(3):1193-1204.
14. Choi JA, Chung SH. Combined application of autologous serum eye drops and silicone hydrogel lenses for the treatment of persistent epithelial defects. *Eye Contact Lens*. 2011;37(6):370-373.
15. Khokhar S, Natung T, Sony P, et al. Amniotic membrane transplantation in refractory neurotrophic corneal ulcers: a randomized, controlled clinical trial. *Cornea*. 2005;24(6):654-660.
16. Turkoglu E, Celik E, Alagoz G. A comparison of the efficacy of autologous serum eye drops with amniotic membrane transplantation in neurotrophic keratitis. *Semin Ophthalmol*. 2014;29(3):119-126.
17. Kruse FE, Rohrschneider K, Völcker HE. Multilayer amniotic membrane transplantation for reconstruction of deep corneal ulcers. *Ophthalmology*. 1999;106(8):1504-1510; discussion 11.
18. Brooks D, Mead OG, Tighe S, Tseng SCG. Self-Retained Cryopreserved Amniotic Membrane for the Management of Corneal Ulcers. *Clin Ophthalmol*. 2020;14:1437-1443.
19. Romero-Rangel T, Stavrou P, Cotter J, et al. Gas-permeable scleral contact lens therapy in ocular surface disease. *Am J Ophthalmol*. 2000;130(1):25-32.
20. Ling JD, Gire A, Pflugfelder SC. PROSE therapy used to minimize corneal trauma in patients with corneal epithelial defects. *Am J Ophthalmol*. 2013;155(4):615-9, 9.e1-2.
21. Elbaz U, Bains R, Zuker RM, et al. Restoration of corneal sensation with regional nerve transfers and nerve grafts: a new approach to a difficult problem. *JAMA Ophthalmol*. 2014;132(11):1289-1295.
22. Deeks ED, Lamb YM. Cenegermin: A Review in Neurotrophic Keratitis. *Drugs*. 2020;80(5):489-494.
23. Müller LJ, Marfurt CF, Kruse F, Tervo TM. Corneal nerves: structure, contents and function. *Exp Eye Res*. 2003;76(5):521-542.
24. Muzi S, Colafrancesco V, Sornelli F, et al. Nerve growth factor in the developing and adult lacrimal glands of rat with and without inherited retinitis pigmentosa. *Cornea*. 2010;29(10):1163-1168.
25. Lambiase A, Rama P, Bonini S, et al. Topical treatment with nerve growth factor for corneal neurotrophic ulcers. *N Engl J Med*. 1998;338(17):1174-1180.
26. Bonini S, Lambiase A, Rama P, et al. Phase II Randomized, Double-Masked, Vehicle-Controlled Trial of Recombinant Human Nerve Growth Factor for Neurotrophic Keratitis. *Ophthalmology*. 2018;125(9):1332-1343.
27. Dome Inc. Dompé receives FDA approval of Oxervate eye drops (cenegermin-bkbj ophthalmic solution), first-in-class recombinant human nerve growth factor with potential to completely heal rare neurotrophic keratitis. www.biospace.com/article/releases/dome-receives-fda-approval-of-oxervate-eye-drops-cenegermin-bkbj-ophthalmic-solution-first-in-class-recombinant-human-nerve-growth-factor-with-potential-to-completely-heal-rare-neurotrophic-keratitis/2018.
28. Chao W. Healing of persistent epithelial defects or corneal ulcers by recombinant human nerve growth factor eye drops in patients with stage 2 or 3 neurotrophic keratitis. Congress of the European Society of Ophthalmology. Barcelona, Spain 2017.

NEUROTROPHIC KERATITIS:

A "Rare Disease" Yet Common Problem

Release Date: October 2021
Expiration Date: October 2022

INSTRUCTIONS FOR CME CREDIT

To receive credit, you must complete the attached Pretest/Posttest/Activity Evaluation/Satisfaction Measures Form and mail or fax to Evolve Medical Education LLC, 353 West Lancaster Avenue, Second Floor, Wayne, PA 19087; Fax: (215) 933-3950. To answer these questions online and receive real-time results, please go to <https://evolvemeded.com/course/2132-suppl>. If you experience problems with the online test, email us at info@evolvemeded.com. *NOTE: Certificates are issued electronically.*

Please type or print clearly, or we will be unable to issue your certificate.

Full Name _____

Phone (required) _____ ☐ Email (required*) _____

Address/P.O. Box _____

City _____ State/Country _____ Zip/Postal Code _____

*Evolve does not share email addresses with third parties.

License Number _____ OE Tracker Number _____

DEMOGRAPHIC INFORMATION

Profession	Years in Practice	Patients Seen Per Week (with the disease targeted in this activity)	Region
___ MD/DO	___ >20	___ 0	___ Northeast
___ OD	___ 11-20	___ 1-15	___ Northwest
___ NP	___ 6-10	___ 16-30	___ Midwest
___ Nurse/APN	___ 1-5	___ 31-50	___ Southeast
___ PA	___ <1	___ >50	___ Southwest
___ Other			

LEARNING OBJECTIVES

Did the program meet the following educational objectives?

Identify the stages of neurotrophic keratitis

Agree Neutral Disagree

Recognize how to differentiate neurotrophic keratitis from similar diseases

Describe the mechanisms of action of newer treatments and when they should be introduced into treatment regimens for neurotrophic keratitis, including the stepwise approach

Explain the relationships between disease characteristics, drug therapies, treatment frequency, visual, and anatomic outcomes

PLEASE COMPLETE AT THE CONCLUSION OF THE PROGRAM.

1. Based on this activity, please rate your confidence in your ability to describe the mechanisms of action of newer treatments and when they should be introduced into treatment regimens for neurotrophic keratitis (based on a scale of 1 to 5, with 1 being not at all confident and 5 being extremely confident).
 - a. 1
 - b. 2
 - c. 3
 - d. 4
 - e. 5
2. A 52-year-old female with history of LASIK OU, pars plana vitrectomy OS, and herpes keratitis OS is referred by her regular optometrist for decreased vision during the past few months in the left eye despite intensive therapy. Vision is 20/20 OD and 20/200 OS. IOP is 15 mm Hg in both eyes. Slit lamp examination of the right eye reveals a well healed LASIK flap but is otherwise unremarkable. The left eye has a 3 x 4 mm epithelial defect with mild stromal haze, diffuse corneal staining outside the defect, and a mild anterior segment reaction. Qualitative testing of corneal sensation shows decreased sensation in the left eye. Fundus examination is normal in the right eye and a B-scan is unremarkable in the left eye. Based on the patient's history and clinical evaluation, this presentation appears to be consistent with neurotrophic keratitis. According to the Neurotrophic Keratitis Study Group, this patient has what stage of disease?
 - a. Stage 1
 - b. Stage 3
 - c. Stage 4
 - d. Stage 5
3. Corneal innervation is essential for good epithelial health. How do corneal nerves maintain a healthy corneal surface?
 - a. Provide stromal, epithelial, and Bowman's structural support
 - b. Maintain sensory functions that are essential to tear film maintenance
 - c. Facilitate protective functions of blinking and tear production as well as trophic support
 - d. Provide key nutrients to the epithelium while also serving as a physical barrier to microbes
4. The Mackie Neurotrophic Keratitis Classification System breaks NK into three stages. Recently, the Neurotrophic Keratitis Study Group has developed a new 7-step staging system. The purpose for this new system is:
 - a. To replace an outdated system
 - b. To allow for more accurate monitoring of progression of the disease as well as delineate which patients may respond well to particular therapies and evaluate response to treatment
 - c. To better educate patients about their disease and help them understand the prognosis and possible consequences of the condition
 - d. Determine which patients need amniotic membrane grafting
5. Endogenous nerve growth factor helps preserve and restore the ocular surface by which of the following mechanisms?
 - a. Strengthening tight junctions between epithelial cells to enhance corneal epithelial barrier functions.
 - b. Providing nutrition to conjunctival goblet cells and eyelid tear glands in order to increase tear production and improve tear quality.
 - c. Stimulating limbal stem cells to generate new epithelial cells.
 - d. Increasing tear production at the lacrimal gland, stimulating nerve regeneration, and supporting epithelial cell proliferation and differentiation.
6. According to the Mackie Severity Classification for NK, all but which clinical feature is classified as Stage 1?
 - a. Punctate epitheliopathy
 - b. Stromal opacity
 - c. Decreased tear break-up time
 - d. Stromal haze
7. Ms. Smith is referred into your clinic for a dry eye evaluation. She has a history of type 2 diabetes, proliferative diabetic retinopathy, and bacterial corneal ulcers with poor healing that required penetrating keratoplasty; 2 months later the epithelium has not yet healed. Previous treatments included antibiotics, steroids, bandage contact lenses, and self-retaining amniotic membrane. Corneal sensitivity testing reveals centrally absent sensation. What would be considered an appropriate next step?
 - a. Continue with Prokera
 - b. Increase steroid-free artificial tears to 5 times daily
 - c. Initiate a 6-week course of cenegermin 8 times daily
 - d. Initiate an 8-week course of cenegermin 6 times daily
8. _____ is the only way to diagnose NK.
 - a. Visual acuity testing
 - b. *In vivo* confocal microscopy
 - c. Corneal sensation testing
 - d. Imaging with a slit lamp
9. Which of the following systemic conditions has been shown in studies to exacerbate NK?
 - a. Diabetes
 - b. Multiple sclerosis
 - c. Leprosy
 - d. Congenital syndromes
 - e. All of the above
 - f. None of the above
10. In the REPARO clinical study, _____ of patients who achieved corneal healing remained healed 48 weeks after completing one full course of treatment with cenegermin.
 - a. 40%
 - b. 60%
 - c. 80%
 - d. 100%

ACTIVITY EVALUATION/SATISFACTION MEASURES

Your responses to the questions below will help us evaluate this activity. They will provide us with evidence that improvements were made in patient care as a result of this activity.

Rate your knowledge/skill level prior to participating in this course: 5 = High, 1 = Low _____

Rate your knowledge/skill level after participating in this course: 5 = High, 1 = Low _____

This activity improved my competence in managing patients with this disease/condition/symptom ____ Yes ____ No

Probability of changing practice behavior based on this activity: ____ Yes ____ No ____ No change needed

If you plan to change your practice behavior, what type of changes do you plan to implement? (*check all that apply*)

- | | |
|--|---|
| <input type="checkbox"/> Change in pharmaceutical therapy | <input type="checkbox"/> Change in nonpharmaceutical therapy |
| <input type="checkbox"/> Change in diagnostic testing | <input type="checkbox"/> Choice of treatment/management approach |
| <input type="checkbox"/> Change in current practice for referral | <input type="checkbox"/> Change in differential diagnosis |
| <input type="checkbox"/> My practice has been reinforced | <input type="checkbox"/> I do not plan to implement any new changes in practice |

Please identify any barriers to change (*check all that apply*):

- | | | |
|---|--|--|
| <input type="checkbox"/> Cost | <input type="checkbox"/> Lack of experience | <input type="checkbox"/> Lack of resources (equipment) |
| <input type="checkbox"/> Lack of consensus or professional guidelines | <input type="checkbox"/> Lack of time to assess/counsel patients | <input type="checkbox"/> Patient compliance issues |
| <input type="checkbox"/> Lack of administrative support | <input type="checkbox"/> Lack of opportunity (patients) | <input type="checkbox"/> No barriers |
| | <input type="checkbox"/> Reimbursement/insurance issues | <input type="checkbox"/> Other. Please specify: _____ |

The design of the program was effective for the content conveyed.	____ Yes ____ No	The content was relative to your practice.	____ Yes ____ No
---	------------------	--	------------------

The content supported the identified learning objectives.	____ Yes ____ No	The faculty was effective.	____ Yes ____ No
---	------------------	----------------------------	------------------

The content was free of commercial bias.	____ Yes ____ No	You were satisfied overall with the activity.	____ Yes ____ No
		Would you recommend this program to your colleagues?	____ Yes ____ No

Please check the Core Competencies (as defined by the Accreditation Council for Graduate Medical Education) that were enhanced through your participation in this activity:

- | | |
|--|---|
| <input type="checkbox"/> Patient Care | <input type="checkbox"/> Medical Knowledge |
| <input type="checkbox"/> Practice-Based Learning and Improvement | <input type="checkbox"/> Interpersonal and Communication Skills |
| <input type="checkbox"/> Professionalism | <input type="checkbox"/> System-Based Practice |

Additional comments:

____ I certify that I have participated in this entire activity.

This information will help evaluate this activity; may we contact you by email in 3 months to ask if you have made changes to your practice based on this activity? If so, please provide your email address below.
