Tissue Tuck Technique for Pterygium Surgery

BY NEEL R. DESAI, MD

In the course of my own residency and cornea fellowship training, the general attitude toward pterygia was one of avoidance—avoid surgery for fear of making things worse. We were instead encouraged to treat symptoms conservatively with tears and NSAIDs. When surgery was unavoidably indicated we braced ourselves for what would inevitably turn out to be an hour-long conjunctival autograft procedure replete with months-long postoperative recovery pitfalls including pain, poor cosmesis, recurrence, granuloma, scarring, and restrictive diplopia. To top off the prolonged chair time spent managing these patients postoperatively, we dealt with the lost-opportunity cost of valuable operating room time and headaches in billing and reimbursement. One was often left wondering, "Why do pterygium surgery at all?"

In reflecting on the evolution of my own practice, pterygium surgery—and ocular surface disease (OSD) in general—is not the mainstay of my practice. However, it became clear that a sound approach to OSD would pay dividends in the form of better outcomes, positive word-of-mouth, and a far broader referral base. We found referring providers universally desperate for a receptive surgeon to send their patients to for these conditions, and, after seeing happy patients return to them, these providers would soon show willingness to refer all their patients.

Goals of Pterygium Surgery

The endpoints of successful pterygium surgery are multifold. First and foremost, we wish to avoid recurrences and other postoperative complications. It is imperative that we implement an easy, efficient, and reproducible surgical technique that produces the lowest recurrence rates, rapid cosmesis, and little to no discomfort.

To achieve these goals, we must evolve our thinking on pterygium surgery from one of primary focus on removing the pterygium and covering a wound, to a more comprehensive paradigm that aims to functionally reconstruct the normal anatomy of the ocular surface using the regenerative properties of biologics within the cryo-preserved amniotic membrane platform technology. Simply excising the pterygium, while failing to seal the gap between conjunctiva and underlying Tenon's fascia will lead to failure on many levels. Instead, with the Tissue Tuck Pterygium technique I describe herein, we aim to seal the gap to recurrences while reconstructing the natural semi-lunar fold for functional and cosmetic restoration.

Vehicles of Active Biologics

It is rather easy to be misled into thinking amniotic membranes are all the same. They are decidedly not so, as evidenced by over 200 peer-reviewed scientific and clinical publications. Rather, the published data should prompt us to view the unique cryo-preserved platform found in AmnioGraft (Figure 1) and Prokera (both Bio-Tissue) as a delivery vehicle for the high-molecular weight HC-HA complexes and PTX-3 fetal biologics that promote and positively modify the wound-healing pathway and promote rapid re-epithelialization, stem cell expansion, goblet cell density, and nerve regeneration, while reducing inflammation, scarring, and angiogenesis.[1]



Figure 1. AmnioGraft, a cryopreserved amniotic membrane graft.

The Tissue Tuck Technique

Several methodologies for pterygium excision have been described over the last several decades. Each method suffers from significant downsides in terms of recurrence or other complications, recovery time, reproducibility, or operating time. Alternatively, other advanced methodologies of sealing the gap and achieving low recurrence rates and excellent cosmesis have been reported wherein surgeons suture conjunctiva to Tenon's fascia with nylon or prolene suture.[2] However, in my own hands, I found this suturing technique time-consuming, pro-inflammatory, and challenging to discern Tenons from fibrovascular tissue when suturing far posteriorly. These challenges gave birth to the Tissue Tuck Pterygium technique utilizing Amniograft.

The overarching principles of the Tissue Tuck procedure center upon functionally reconstructing the semilunar fold with the eye in maximal abduction while sealing the gap with a deep tuck of cryo-preserved amniotic membrane after all fibrovascular tissue and Tenon's fascia have been meticulously dissected. The procedure begins by placing a critically important corneal traction suture to place the eye in full abduction for a common nasal pterygium. This serves to stretch and flatten the rectus muscle against the globe to ensure the muscle sheath remains intact and, moreover, allows functional redundancy of conjunctiva in the recreated semilunar fold. With the eye returning to primary gaze postoperatively, the gap is only further recessed and cosmetically hidden. When the patient abducts their eye postoperatively, it can do so without restriction and diplopia, and

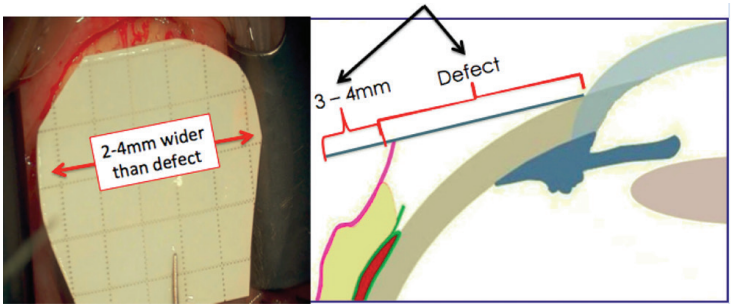

Figure 2. Cut AmnioGraft 4 mm larger than defect to allow adequate tissue to tuck under conjunctival rim.

the gap remains sealed because it was sealed and reconstructed in that position to begin with. Further anesthesia, paresthesia, hemostasis, and separation of natural tissue planes is achieved by infiltrating 2% lidocaine with epinephrine in the subconjunctival and Tenon's space. Excision of the pterygium begins by brushing the head cleanly from Bowman's layer using a crescent blade in an anterior to posterior direction. Wescott scissors are then used to begin the dissection at the limbus, extending as far posteriorly as the intended position of the new semilunar fold. The width of excision is uniform across all cases, with the intent to hide the superior and inferior wound margins with the upper and lower eyelid.

It is important to fully free the pterygium from all scleral attachments, preserving the muscle sheath and allowing the bulk of fibrovascular tissue to retract before making posterior resection. Once the pterygium and bulk of fibrovasular tissue is excised, we will return our attention to meticulous dissection and debulking of tenons and fibrovascular tissue along the entire conjunctival rim and posteriorly in the gap. Tenons are grasped and pulled out from the subconjunctival space, resected, and allowed to recess itself posteriorly, leaving a thin, translucent rim of conjunctiva that lays flat against sclera. This allows for smooth transitions, strong seal, and excellent cosmesis once the membrane is tucked underneath. To further ensure sealing of the gap and reduce recurrences, bent MacPherson bipolar cautery forceps are used to reach under the conjunctival rim and lightly cauterize any remaining fibrovascular tissue to the recessed tenons edge. This maneuver takes advantage of Tenons' tendency to retract by tethering the fibrovascular root of the pterygium to Tenons.

In preparing the membrane for placement, it should be trimmed to roughly match the shape of the scleral bed, aiming to oversize it by at least 4 mm in all directions to allow adequate tissue for tucking under the superior and inferior conjunctival margin and for performing the Tissue Tuck posteriorly to recreate a semilunar fold (Figure 2). The membrane is peeled from the paper backing and draped over the cornea in a stromal-side-down orientation.

In preparation for tissue placement and adherence, dry the scleral bed and subconjunctival space. Three drops or less of the thrombin component are placed first, spreading with the side of the cannula and removing any excess that pools within the posterior gap. Next, three drops of fibrinogen are placed over the scleral bed. This order allows adequate working time to carefully place the amniotic tissue. The membrane is dragged from the cornea, posteriorly by the leading edges over the microlayer of glue on the scleral bed then up and over the posterior conjunctival rim. Then, in a manner similar to making a bed with a well-defined crease under the pillows, curved tying forceps are

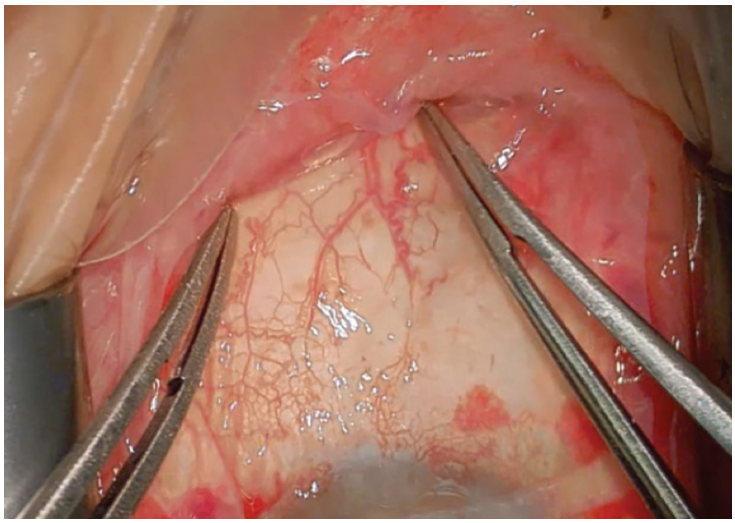

Figure 3. Tucking technique to recreate semilunar fold and seal the gap.

used to sweep the membrane into the gap, folding it back on itself and exposing the stromal side of the membrane to the stromal underside of the conjunctival rim. Sweeping motions are used to tuck the tissue deep into the subconjunctival gap until the trailing edge of the membrane is seen to come even with the conjunctival edge. This tucking maneuver provides the amniotic scaffold for conjunctival re-epithelialization and recreation of the semilunar fold, while doubly sealing the gap to recurrences (Figure 3). Excess glue is squeegeed only anteriorly to avoid sequestration. The lateral sides of the membrane are tucked flatly under the superior and inferior margins. Excess membrane can be trimmed at the limbus, and a large diameter contact lens is placed for 1 week to protect this leading edge.

The postoperative regimen includes only a potent steroid taper and an antibiotic. NSAIDS have become unnecessary in my experience as this technique, and the biologic platform, provide for minimal pain and discomfort.

Conclusion

With meticulous attention to technique, it is possible to achieve exceedingly low recurrence rates, rapid cosmesis in as little as 2 weeks, surgical efficiency, and reproducibility. Applying this technique along with the AmnioGraft technology creates superior clinical results for the ocular surface. This technique, when performed correctly, along with the biologics of the amniotic membrane, can reduce our pterygium recurrence, prevent scarring and neovascularization, provide excellent cosmesis, and lead to happier patients. ■

1. BioTissue Data on file.
2. Sheppard JD, Mansur A, Comstock TL, et al. An update on the surgical management of pterygium and the role of loteprednol etabonate ointment. *Clin Ophthalmol*. 2014; 8:1105-1118.

NEEL R. DESAI, MD
- Director, Cornea, Refractive and Cataract, The Eye Institute of West Florida
- Course Director for Ocular Surface Biologics Training Course
- Medical Director, Lions Eye Bank & Transplant Institute
- President & CEO, Clarity: Visionary Consulting, Inc.
- desaivision2020@gmail.com
- Financial disclosure: Consultant (Bio-Tissue)