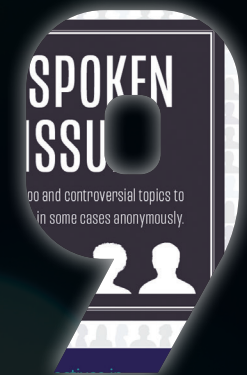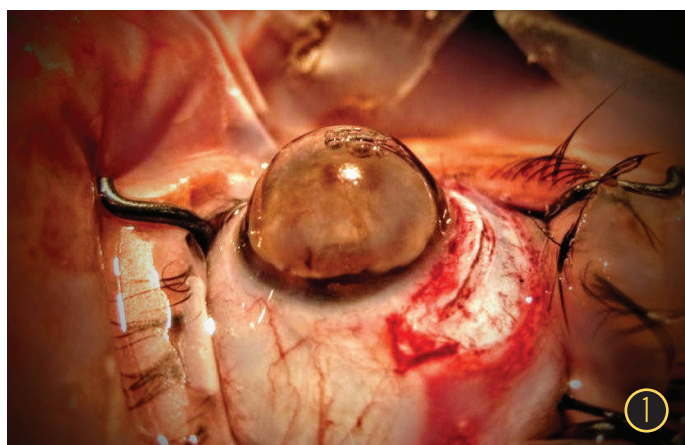


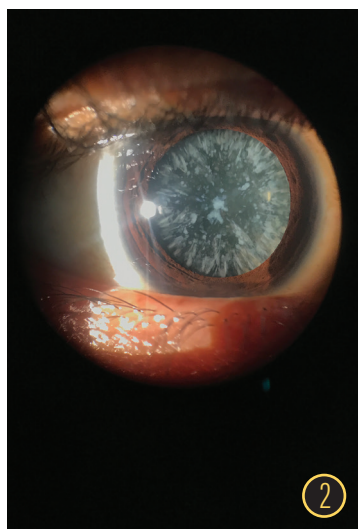YEAR IN FOCUS



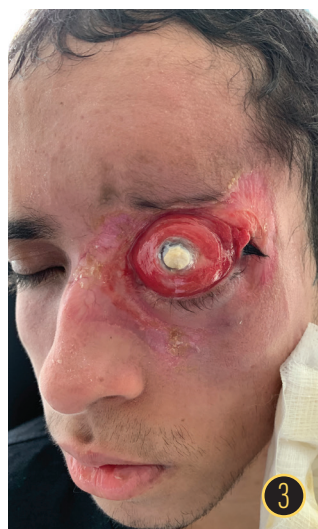Rare and Unusual CASES



▲ VICTOR BERGAMASCO, MBBS
The Globe

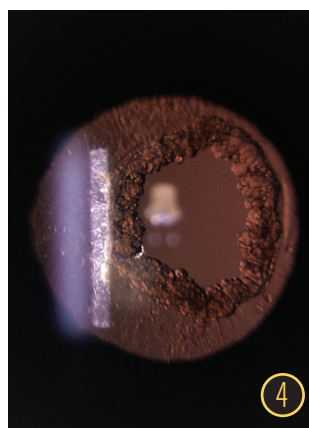


▲ MARCELO MESQUITA MAIA, MD
Confetti

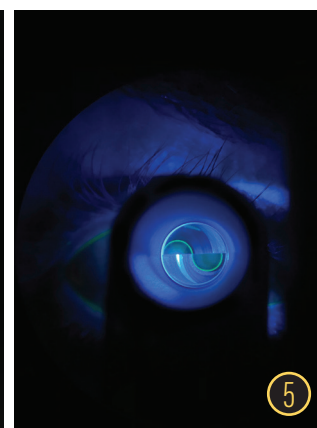


▲ ALEXANDER MARTÍNEZ RUA, MD
Necrotizing Fasciitis


Interesting and Artistic IMAGES



▲ MANAS NATH, MBBS, DO,
FAEH, FAICO
Ring of Pearls



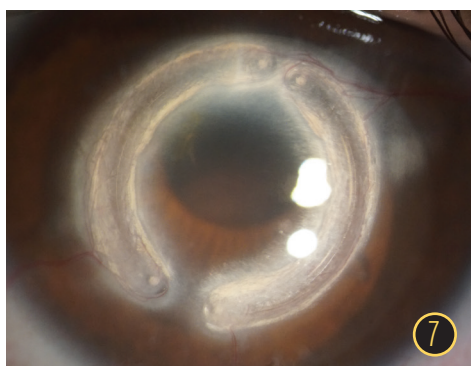
▲ CELSO DE SOUZA DIAS JÚNIOR, MD
An Encounter With Semicircles



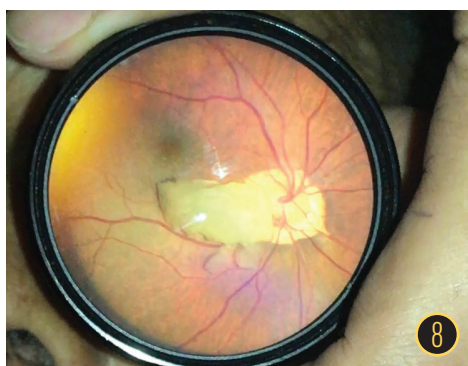
▲ ADNAN BERKAY KISAKÜREK, MD
Conjunctival Squamous Papilloma

WINNERS OF *CRST'S* Annual Photo Contest

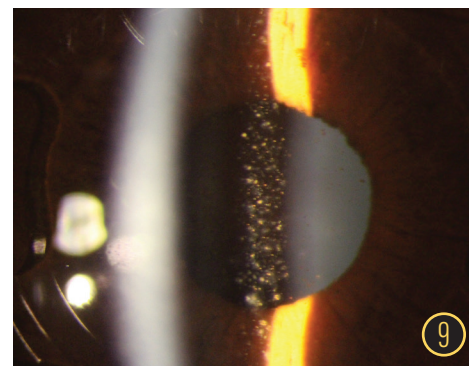
SURGICAL *Complications*



▲ CLAUDIO TRINDADE, MD, PHD
Neovascularization After Corneal Ring Segments



▲ ROBERTO JULE, MD
Misplaced



▲ RICARDO STOCK, MD
Artisan Pigmentation

RARE AND UNUSUAL CASES

- 1 This image shows keratoglobus and a total fibrotic cataract in a 45-year-old woman with Ehlers-Danlos syndrome who underwent uneventful extracapsular cataract extraction followed a few months later by limbus-to-limbus penetrating keratoplasty.
- 2 This is a photograph of an interesting and unusual type of cortical cataract.
- 3 The image in this photograph is of necrotizing fasciitis in a patient with acute lymphoid leukemia.

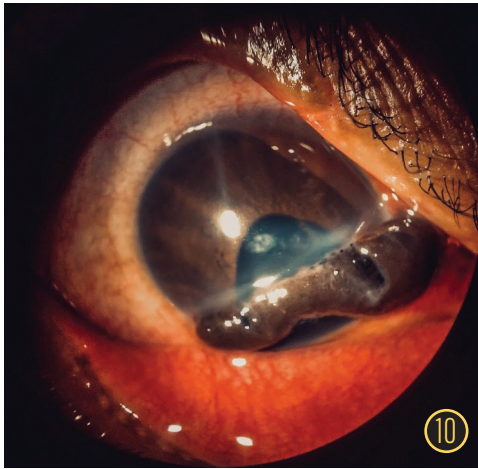
INTERESTING AND ARTISTIC IMAGES

- 4 This slit-lamp retroillumination image shows proliferation of Elschnig pearls at the margin of an Nd:YAG laser posterior capsulotomy opening. The posterior capsulotomy was performed more than 2 years prior to presentation.
- 5 This image of fluorescein semicircles in a nonglaucomatous eye was taken during Goldmann applanation tonometry.
- 6 A 45-year-old man presented with a mass on the inferior eyelid of his right eye. He reported experiencing foreign body sensation in the eye as well as irritation and itching.

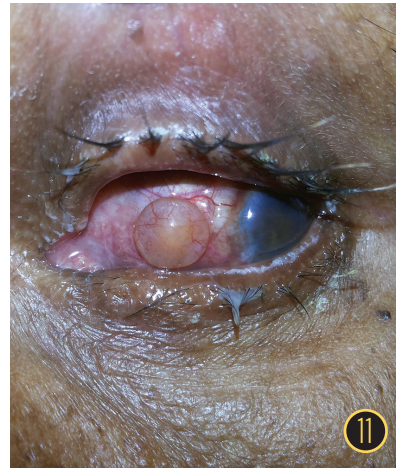
SURGICAL COMPLICATIONS

- 7 This image was captured with a slit lamp using open-slit illumination and diffuse background illumination; a 35-year-old patient with keratoconus presented with a complex web of neovascularization around an intrastromal corneal ring segment 7 years after ring segment implantation. White deposits along the intrastromal tunnel caused visual and cosmetic problems.
- 8 An image of a cataract fragment in the posterior pole after posterior capsular rupture during cataract surgery.
- 9 A photograph of iris pigment attached to an Artisan Phakic IOL (Ophtec) after uneventful surgery.

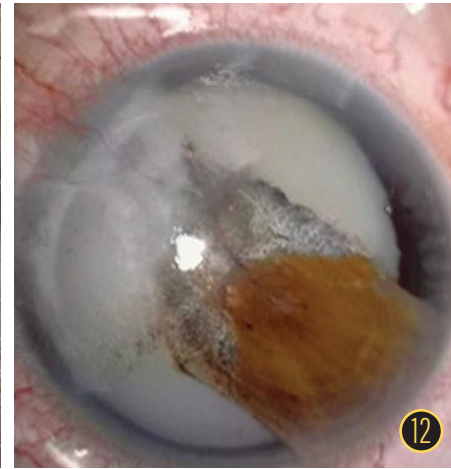
OCULAR Trauma



▲ CAROLINA MENDOZA, MD
A Prolapsed Self-Sealing Iris

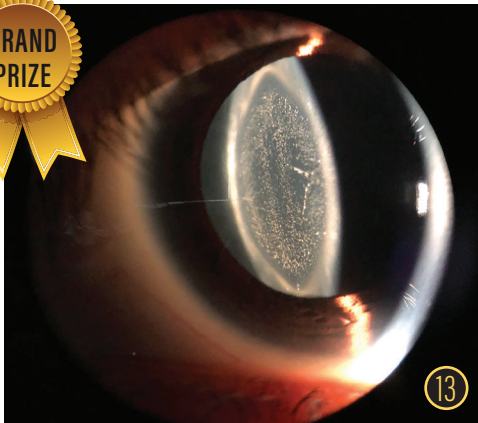


▲ MARCELO MESQUITA MAIA, MD
Phacocoele

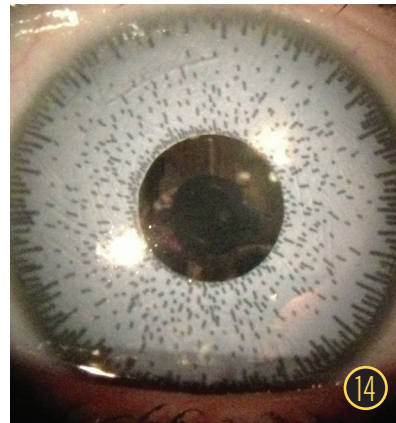


▲ LEKSEJ MEDIC, MD
Traumatic Cataract With Total Iridodialysis

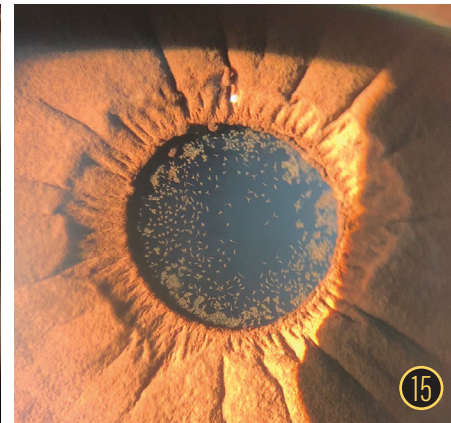
Slit-Lamp IMAGES



▲ GRAND PRIZE WINNER | JOCELYN RIVERA, MD
Galaxy



▲ MICHAEL RIZEN, MD
Don't It Make My Brown Eyes Blue



▲ GABRIEL CASTILHO SANDOVAL BARBOSA, MD
Epicapsular Stars

OCULAR TRAUMA

- 10 This image of the right eye of a 29-year-old woman with a history of penetrating corneal laceration shows a corneal and scleral laceration with prolapsed iris sealing the corneal injury, which kept the anterior chamber formed.
- 11 This is an image of the eye of a patient with a history of trauma who presented with a lens extrusion in the subconjunctival space through a scleral tear.
- 12 An image of a patient with a traumatic cataract with subtotal iridodialysis caused by a penetrating injury of the cornea and sclera.

SLIT-LAMP IMAGES

- 13 This image shows a dense cerulean cataract in a 28-year-old woman with high myopia who presented with a 1-year history of progressive visual loss in her left eye.
- 14 This is a photo of a patient who received iris implants in South America and presented with uveitis. Removal of the implants was recommended to prevent long-term complications of glaucoma and corneal decompensation.
- 15 This is a photograph of a remnant of the tunica vasculosa lentis that appears as star-shaped brown pigments in the anterior lens capsule. ■