

A CONTROLLED APPROACH TO IOL EXPLANTATION



Folding the lens for extraction can provide advantages over bisection.

BY BRET L. FISHER, MD

Premium IOLs can help surgeons achieve great outcomes for their patients, but there are rare occasions when these lenses must be explanted. Ideally, we can avoid the need for explantation with careful patient screening and education. Not only do we want to match the right lens with the right candidate, we also want to ensure that the patient understands the potential for postoperative effects such as glare and halos.

But in the event that an IOL explantation is necessary, I have developed the technique described in this article, which has been helpful to me.

REASONS FOR EXPLANTATION

There are rare occasions when premium IOL explantation is necessary. (It is far more likely that I would explant a standard monofocal lens and exchange it for a premium IOL.) I would not normally explant a lens due to small residual refractive error because that can be addressed with either LASIK or PRK at 6 weeks or more after the initial surgery. It is very rare to have a gross power mismatch with the use of intraoperative aberrometry, but, if a large power surprise occurs, this might be a reason to exchange a premium IOL.

The most typical reasons for premium IOL exchange are related to the compatibility of the lens with the patient. For example, if a patient

received a multifocal IOL and ultimately could not adapt to the night vision disturbance from that particular lens, it might be necessary to exchange it. Thankfully, as generations of multifocal IOLs continue to improve, this becomes less common.

THE TECHNIQUE

My technique for IOL explantation begins with topical anesthesia—the same as I use for cataract surgery—plus light sedation with an MKO Melt (midazolam/ketamine HCl/ondansetron, Imprimis) or light intravenous administration.

I use a temporal approach and try to reopen the incision from the original cataract surgery, which is typically about 2.2 mm, and I then enlarge it to about 2.5 mm with a diamond keratome. It is important in these cases not to make too large an incision because it could have an unintended refractive effect.

I then inject a high molecular-weight OVD such as DisCoVisc (Alcon) to maintain the anterior chamber, and I use the OVD cannula to dissect around the existing lens implant. I carefully go behind the lens and down to the haptic-optic junction to ensure that the OVD reaches the haptics. I am always prepared to use more than one vial of OVD when necessary.

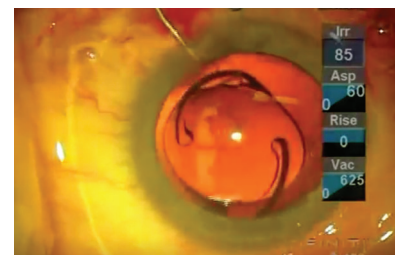
Once the haptics are loose, I use a Maloney lens rotator to gently pull the haptics out of the capsular bag,

making sure that they are free and not adhering to the capsule. Rather than trying to dial or spin the lens out, I use the instrument to pull the haptics up into the anterior chamber, which brings the optic with it. I believe this applies the least stress on the zonules and the capsular bag.

With the lens sitting freely in the anterior chamber, I make sure that there is OVD anterior and posterior to the lens. Then I use intraocular foreign body forceps (Millennium Surgical) for removal. This instrument will fit through a 2.5-mm incision and can clamp down on the optic. I can then slowly withdraw the IOL, and the lens will fold itself as it goes through the incision. Thus, I can avoid the need to cut the lens or amputate the haptics, preventing damage to the endothelium.

While removing the lens, I caution the patient that he or she will feel pressure during this step. I also make sure there is plenty of OVD to keep the iris away from the corneal

▶ WATCH IT NOW ◀



▶ BIT.LY/FISHER0419

WHEN EXPLANTATION IS NOT FEASIBLE

There are times when a patient is unhappy after a premium IOL implantation but explantation is not feasible. In such a case, another approach is needed to fix the problem.

Take, for example, a patient who received a multifocal IOL several years ago and is now unhappy with his or her vision. If upon examination it is clear that there were some problems with the previous surgery or that the lens was scarred into place, I might counsel that patient regarding pharmacologic treatments

as an alternative to explantation and exchange. Topical drops that slightly constrict the pupil at night can help with dysphotopsias.

Another option for dealing with nighttime vision issues is spectacles for specific uses. For example, the opticians in my practice have had success prescribing glasses specifically for night driving. For a patient having difficulty with night vision, we would prescribe spectacles with the best residual prescription plus tinting to lessen glare or other dysphotopic effects.

tunnel. I put some countertraction on the sideport incision with standard 0.12-mm forceps and then slowly but firmly withdraw the lens, allowing it to fold. This technique brings the lens out through the tunnel in one piece, and the incision remains unenlarged at 2.5 mm.

AVOIDING COMPLICATIONS

The technique described here is quite simple—and that is the key. I certainly don't think it is a problem to cut or partially cut the lens within the eye if it is done skillfully. However, stabilizing the lens with one instrument and cutting it with another instrument while it's covered with OVD is tricky, and one could damage the endothelium during this maneuver.

In my technique, I try to keep the lens as stable as possible in the anterior chamber. The technique is very controlled, as the lens is sandwiched in OVD, grasped firmly with a single instrument, and withdrawn from the eye.

EXPLAINING EXPLANTATION

If I decide that an IOL exchange is warranted, I am careful to tell the patient that, although this is a safe procedure, I cannot guarantee that the exchange will be possible until we are in the OR. I may discover that

the patient's body has healed around the existing lens implant, for example, and it may not be safe to remove it. There may be too much scar tissue formed around it, and trying to explant the lens could damage the eye. In such an event, I say we will have to try another approach to fix the problem (see *When Explantation is Not Feasible*).

I also make sure the patient understands that it is possible he or she will experience blurrier vision during recovery than after the initial procedure. It may be a couple of weeks before we can really judge the results of the surgery and whether it has addressed the issues that caused the explantation.

CONCLUSION

Patients with premium IOLs need premium solutions when they are unhappy with a surgical result. The technique described here has been helpful to me and some of my colleagues, and I hope others will find it useful as well. ■

BRET L. FISHER, MD

- Medical Director, Eye Center of North Florida, Panama City, Florida
- bfisher@eyecarenow.com
- Financial disclosure: Consultant (Alcon); Medical monitor (Ziemer)