Insert to
March 2019
CRST
Cataract & Refractive Surgery Today

WHY I CHOOSE THE ISTENT INJECT

Adding value to cataract surgery for your glaucoma patients.

JOHN A. HOVANESIAN, MD

My goal with cataract surgery is not lowering intraocular pressure, nor is it a diopter target. What I am really looking for with refractive cataract surgery is hugs and kisses. I want my patients to be thrilled with their results, and I, in turn, want to help improve their quality of life.

Patients who have glaucoma and are planning to undergo cataract surgery are pleasantly surprised to learn they can potentially eliminate IOP-lowering medications by coupling a micro-invasive glaucoma procedure. In fact, 4-year data from my practice show that the average patient has a pressure reduction of about 22% with trabecular micro-bypass (Glaukos). I can tell patients they have about a two-thirds chance of eliminating one IOP-lowering drop and about a one-third chance of eliminating two drops, if they are using two. Patients are thrilled with that benefit.

What's more, in my busy clinic, I cannot have patients coming in after surgery with hypotonous pressures of 3 mm Hg or 5 mm Hg, macular edema, or shallowing chambers. Every eye must be quiet and stable with a predictable result, and the recently approved iStent *inject* (Glaukos) can give me that result.

SIMPLE PATH TO LEAST RESISTANCE

The iStent *inject* system is comprised of two tiny multidirectional stents that are preloaded on a single-use injector. The micro stents are implanted in the trabecular meshwork and create two bypasses that allow multidirectional flow through Schlemm's canal (Figure 1).

I like that we are following the natural outflow pathway of the eye to access multiple collector channels. We are taking advantage of the fact that the trabecular pathway accounts for the majority of aqueous outflow from the eye, and the natural resistance to outflow minimizes potential challenges such as hypotony. In my experience, I have not seen a case of hypotony when placing a trabecular bypass stent.

This is unlike the unconventional pathway, where the aqueous humor exits through the root of the iris between the ciliary muscle bundles and then through the suprachoroidal-scleral tissues, potentially leading to low pressures followed by very high rebound pressures.

This also makes sense, because the trabecular meshwork is the site of much of the pathogenesis of primary open-angle glaucoma, as shown by the scanning electron microscopy images in Figure 2. With trabecular bypass stents, we are creating a pathway for aqueous to flow to help minimize the effect of the disease.

Some MIGS procedures are designed to ablate or completely unroof Schlemm's canal. In a recent paper, Xin and

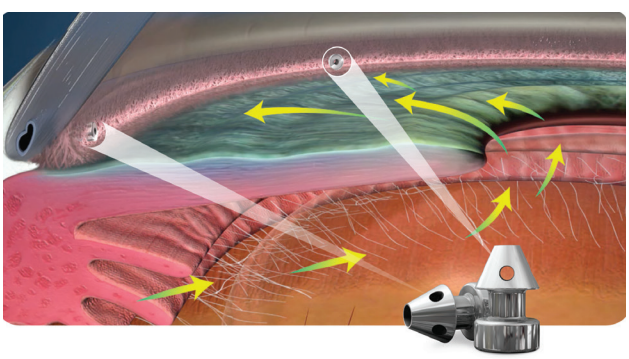

Figure 1. Two iStent *inject* stents bypassing the trabecular meshwork.

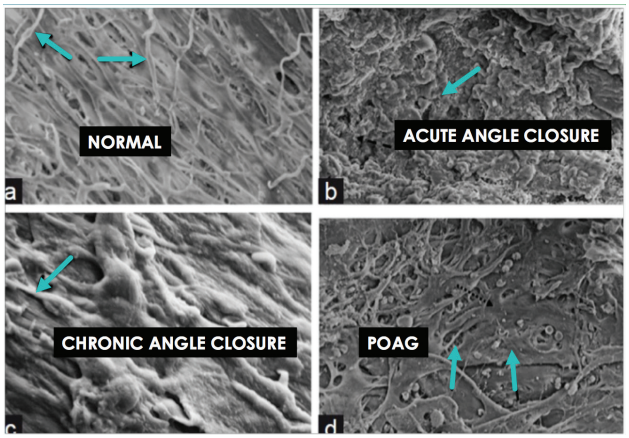

Figure 2. Pathology of the trabecular meshwork.

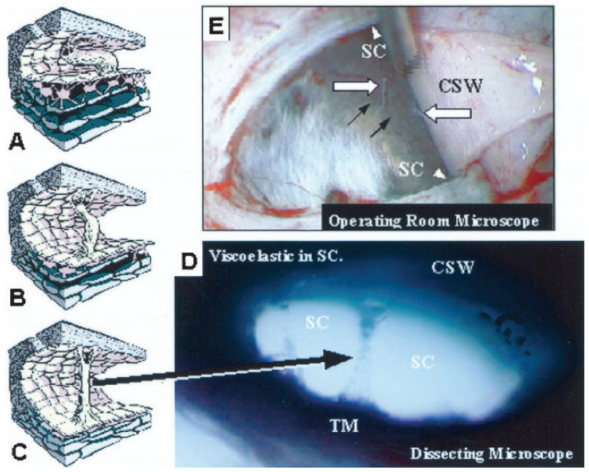

Images courtesy of Murray A. Johnstone, MD; originally published *J Glaucoma.* 2004;13:421-438.

Figure 3. Aqueous outflow as a mechanical pump.[2] Reproduced with permission from the *Journal of Glaucoma.*

colleagues bring to light a concern about these types of procedures.[1] They report a natural mechanical pump that occurs and moves aqueous fluid through the outflow system.

With trabecular bypass stents, we still allow that to happen, because we are increasing outflow and maintaining the integrity of the trabecular meshwork. We are bypassing the resistance that is present, rather than damaging natural anatomy. Some nice images from a different study show where the trabecular meshwork leads to collector channels and allows outflow (Figure 3).[2]

CONCLUSION

The iStent *inject* is a very useful MIGS device for cataract surgeons, as it leverages the natural outflow pathway in the most micro-invasive manner. It is an elegant procedure and has been straightforward to use. Additionally, multiple studies have demonstrated the iStent *inject* can lower IOP and may reduce the need for IOP-lowering medications (based on physician discretion).[3]

If you are a cataract surgeon with a busy practice, and you are looking to add value for your patients but not disrupt your practice, I encourage you to learn MIGS and consider trabecular bypass stents as valuable tools. ■

1. Xin C, Johnstone M, Wang N, Wang RK. OCT study of mechanical properties associates with trabecular meshwork and collector channel motion in human eyes. *PLoS One.* 2016;11:e0162048.
2. Johnstone MA. The aqueous outflow system as a mechanical pump evidence from examination of tissue and aqueous movement in human and non-human primates. *J Glaucoma.* 2004;13:421-438.
3. Hengerer FH, Auffarth GU, Riffel C, Conrad-Hengerer I. Prospective, non-randomized, 36-month study of second-generation trabecular micro-bypass stents with phacoemulsification in eyes with various types of glaucoma. *Ophthalmol Ther.* 2018;7:405-415.

JOHN A. HOVANESIAN, MD
■ Private practice, Harvard Eye Associates, Laguna Hills, California
■ Clinical Assistant Professor, UCLA Jules Stein Eye Institute, Los Angeles
■ johnhova@gmail.com
■ Financial disclosure: Consultant (Glaukos, Ivantis, Sight Sciences)