

CROWDED EYE WITH POSTERIOR PRESSURE

How to anticipate, prevent, and deal with the challenges.

BY LISA BROTHERS ARBISSER, MD; SOON-PHAIK CHEE, MD; AND THOMAS A. OETTING, MS, MD

CASE PRESENTATION

A 63-year-old male truck driver presents for a consultation regarding visual acuity reduced to 20/50 that is complicating his activities of daily living. The patient has bilateral hyperopia (+5.00 D refraction), a short but not nanophthalmic right eye, narrow angles, and bilateral 2+ nuclear sclerotic cataracts. Upon examination, IOP is within

normal limits in each eye, and gonioscopy shows grade 1 angles without pigment or synechiae. With pupillary dilation, IOP rises 5 mm Hg. Anterior chamber (AC) depth is 2.3 mm in each eye.

The patient is a monofixator with only gross stereopsis. He states that he would “feel naked without glasses.”

How would you proceed? What precautions would you take? Be specific about nuances of the surgical steps.

—Case prepared by
Lisa Brothers Arbisser, MD



SOON-PHAIK CHEE, MD

Eyes with a short axial length pose several surgical challenges. IOL power calculation can be inaccurate, and the surgeon can encounter a shallow AC and positive posterior vitreous pressure with an increased risk of posterior capsular rupture. Preoperative discussion should educate the patient about these risks.

Surgery should not be delayed because of the risk of primary angle-closure glaucoma. I would start with the microtropic eye so that, if necessary, I could adjust the IOL power for the fellow eye. Biometry based on swept-source OCT is accurate and checks for foveal fixation. I would choose aspheric monofocal IOLs and target emmetropia in both eyes. For IOL power calculation, I would rely on the Barrett Toric or the Universal IOL Calculator, both of which I have found to be accurate in short eyes. Laser cataract surgery and intraoperative wavefront aberrometry might be helpful in this case.

Thirty minutes before surgery, the patient would receive intravenous mannitol 20% to help reduce posterior pressure. I would use peribulbar anesthesia with ocular compression under sedation to minimize lid squeezing. Jaffe pediatric eyelid retractors would be used to reduce pressure on the globe. I would create a 1.8-mm incision to prevent iris prolapse and then deepen the AC with either a dispersive or viscoadaptive OVD.

Next, using microforceps, I would create the capsulorhexis and repeatedly refill the AC with OVD to reduce the risk of an errant tear. If the AC stayed persistently shallow, I would perform a limited 23-gauge anterior vitrectomy through the pars plana to soften the globe. I would carry out phacoemulsification using reduced parameters. It would be important to maintain pressure in the AC with OVD when removing instruments from the eye to reduce the risk of choroidal effusion. I would inject a capsular tension ring before implanting the IOL to minimize the risk of forward movement of the iris-IOL-capsular bag complex. Postoperatively, administering topical atropine might help to counter early anterior rotation of the lens-iris

diaphragm detected on ultrasound biomicroscopy.



THOMAS A. OETTING, MS, MD

I love operating on hyperopes because they often have low expectations and are generally accepting of mild refractive error. That said, it would be necessary in this case to address one big issue up front: Does this patient have amblyopia in the right eye, the left eye, or both? If the patient has amblyopia, it would be important to set reasonable expectations regarding postoperative vision.

The choice of IOL power calculation formula is critical when the axial length is short. Some older formulas such as the SRK/T are poor choices for hyperopic patients. The good news is that modern formulas such as the Barrett 2 do well in every situation.¹

Because operating on only one eye would raise concern about anisometropia, operating on both of the patient's eyes would be preferable. In a situation

like this, I usually look at the IOL power calculation results before discussing a refractive goal. I would expect to be able to achieve a nearly plano result with a standard IOL in this case. It could be beneficial, however, to switch to an IOL such as the AcrySof IQ Monofocal IOL (model SA60, Alcon), which is available in powers up to 40.00 D. Some patients like this one will end up slightly hyperopic postoperatively.

Before proceeding to surgery, I would emphasize to the patient that he is at risk of developing glaucoma over time and that cataract surgery should nearly eliminate the risk.

The cataract procedure itself presents a few challenges. Space is the biggest issue. The small AC depth makes iris prolapse and endothelial damage more likely. I prefer to use iris hooks in this situation to prevent iris prolapse, and I typically place the instruments in a diamond configuration, with one hook located below the main incision. A Malyugin Ring (MicroSurgical Technology) or similar device would be another option, but it would take up more space in the AC. In cases like this one, I usually add glutathione to the irrigating solution (BSS Plus, Alcon) and perform the soft-shell technique pioneered by Steve A. Arshinoff, MD, to protect the corneal endothelium.

Patients like this one are at increased risk of choroidal effusion and hemorrhage. These complications typically occur late in the case, especially if the AC collapses frequently. Prevention requires performing speedy surgery and keeping the AC formed at all times.



WHAT I DID:
LISA BROTHERS ARBISSER, MD

The patient had a closable but not closed angle. For that reason, rather

than perform a preoperative peripheral iridectomy, I recommended cataract surgery to improve his visual acuity and, I hoped, stave off progressive damage from angle-closure glaucoma. I performed bilateral surgery with monofocal IOLs, with the procedures spaced 1 week apart. I operated on the patient's nondominant eye first and instructed him to use over-the-counter plano +2.50 D bifocals between surgeries.

My preference is to avoid a dry pars plana tap at all costs. Instead, I will manage a shallow AC with intravenous mannitol delivered as a bolus of 0.25 g/kg 20 minutes before making the cataract incision under a soft shell of Healon GV (Johnson & Johnson Vision) and Viscoat (Alcon) that is ironed out under the corneal endothelium. I am careful to prevent AC collapse. If there is a pronounced rise in IOP with preoperative pupillary dilation, I dilate the pupil with intracameral medication while the patient is on the table instead of instilling topical dilating drops in the holding area.

In a case like this, the surgeon can carefully perform a standard capsulorhexis through a clear corneal incision or a paracentesis. It is essential to prevent iris prolapse beyond the incision tunnel to avoid creating postoperative transillumination defects. On foot position zero, I pass the phaco handpiece into an OVD-controlled chamber so as to minimize stress on the subincisional iris and Descemet membrane. Establishing flow before initiating ultrasound helps to prevent wound burn.

It is essential always to return to foot position zero before exiting the eye so that the iris does not follow. When removing the phaco and I/A handpieces from the AC, I support the chamber with balanced salt solution through the paracentesis to help prevent AC collapse. Chamber collapse not only threatens endothelial integrity, but it can also retrodirect the flow of irrigation fluid around

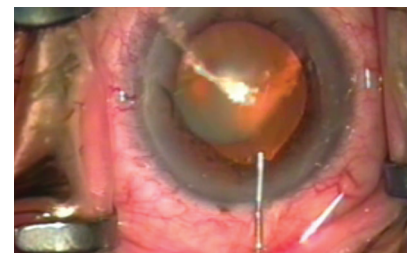
the zonules, hardening an eye with susceptible anatomy like the crowded anterior segment in this eye.

For nuclear disassembly, I prefer vertical chop using cross action, a back-cracking technique, and burst mode. This strategy allows the phaco needle to stay in the safe deepest central zone at all times, it keeps large lens fragments away from the cornea, and it ensures that virtually all ultrasound energy is expended at or below the iris plane. A blunt chopper (Sinsky hook) protects the posterior capsule during final fragment removal, countering any potential surge.

Measured reinstallation of an OVD (never distal to proximal) before, during, and after maneuvers helps protect iris and corneal tissue. Thorough cortical removal is essential. Verifying that the cataract incision is closed after IOL implantation will help prevent chamber collapse. As prophylaxis against postoperative IOP elevation, I thoroughly remove OVD from the anterior and posterior chambers, instill a drop of acetylcholine at the conclusion of the case, and administer one acetazolamide extended-release capsule (Diamox Sequels, Duramed Pharmaceuticals) on discharge. All of my patients also routinely receive intracameral moxifloxacin off-label.

One day after surgery, UCVA was 20/25 in the patient's first eye. He underwent surgery on his second eye 1 week later, and UCVA was 20/20 on postoperative day 1. The

► WATCH IT NOW ◀



► BIT.LY/ARBISSER0119

ACs were deep, and IOP was in the normal range. ■

1. Melles RB, Holladay JT, Chang WJ. Accuracy of intraocular lens calculation formulas. *Ophthalmology*. 2018;125(2):169-178.

SECTION EDITOR LISA BROTHERS ARBISSER, MD

- Emeritus position, Eye Surgeons Associates, the Iowa and Illinois Quad Cities
- Adjunct Professor, John A. Moran Eye Center, University of Utah, Salt Lake City
- (563) 343-8896; drlisa@arbisser.com

- Financial disclosure: None

SOON-PHAIK CHEE, MD

- Head and Senior Consultant of Cataract Subspecialty Service and Ocular Inflammation & Immunology Service, Singapore National Eye Centre, Singapore
- Professor, Duke-National University of Singapore Graduate Medical School
- Professor, Department of Ophthalmology, Yong Loo Lin School of Medicine, National University of Singapore

- chee.soon.phaik@singhealth.com.sg
- Financial disclosure: None

THOMAS A. OETTING, MS, MD

- Rudy and Margaret Perez Professor of Ophthalmology and Director of the Ophthalmology Residency Program, University of Iowa, Iowa City, Iowa
- Chief of Eye Service and Deputy Director of Surgery Service, VAMC Iowa City, Iowa
- thomas-oetting@uiowa.edu
- Financial disclosure: None