

# HISTORY OF POSTERIOR CONTINUOUS CURVILINEAR CAPSULORHEXIS AND OPTIC CAPTURE



BY HOWARD V. GIMBEL,  
MD, MPH, FRCSC

This useful technique is not just for pediatric surgery.

Secondary cataracts after pediatric cataract surgery have long been recognized as an expected complication when the posterior capsule is left intact. Planned anterior vitrectomy after posterior capsulectomy or capsulotomy is now performed routinely with cataract and IOL surgery in children. This is because, even with the posterior capsule open and the IOL in the bag, lens epithelial cell migration can proceed through the posterior continuous curvilinear capsulorhexis (PCCC), behind the IOL, and across the visual axis, making it evident that the anterior vitreous must be removed to eliminate this scaffold for cell migration.

After the development of anterior continuous curvilinear capsulorhexis,<sup>1</sup> it became obvious that tears in the posterior capsule should, if possible, be converted to a PCCC. In addition, opening the posterior capsule (PC) with the PCCC technique in the presence of a dense plaque leaves a strong capsular bag in which to place an implant.

I first used this technique in 1987 to remove a dense posterior capsular plaque and in 1988 to convert a PC tear to a PCCC.<sup>2</sup>

Optic capture in the anterior continuous curvilinear capsulorhexis was described by Neuhann and Neuhann in a film, "The Rhexis-Fixated Lens," in 1991.<sup>3</sup> With the experience I gained using that technique in adult cataract surgery, it seemed obvious that, after performing a PCCC, the same capture technique could be used with the haptics left in the bag and the optic captured by the PCCC. I expected that this would seal the opening and prevent the aforementioned complication of cell migration through the PCCC and across the intact vitreous face in pediatric cataract surgery.

#### EARLY EXPERIENCE

I first combined PCCC with optic capture in children's eyes undergoing cataract surgery in April 1993. I described the technique and my early experience using it in eight eyes of

children in a publication coauthored with DeBroff in 1994.<sup>4</sup>

In my early experience, the PCCC was done after the IOL was in the bag so that, in the event of an unsuccessful PCCC, the IOL would already be safely in the bag. To keep the vitreous from coming through the PCCC as it was being fashioned, a highly cohesive OVD was placed through the first small tear in the PC. Then more OVD was added as the tear was completed with forceps. Optic capture was then performed slowly, one edge at a time, so that some of the cohesive OVD behind the IOL could escape, and the vitreous would not be pushed out through the PCCC.

A PCCC of 4.0 mm or 4.5 mm resulted in a very tight seal after optic capture. During irrigation and aspiration of the OVD from the anterior chamber, I also used slight pressure on the IOL to prevent the vitreous and the OVD behind the lens from pushing the optic out of capture when the chamber became more shallow as the OVD

was aspirated. Postoperatively, the OVD was trapped behind the IOL optic and caused no IOP spike as it was gradually metabolized.

At that time, we were using the one-piece PMMA 811B CeeOn lens (Pharmacia; no longer available) with a 6.0-mm optic and narrow, thin, optic-haptic junctions that were at right angles to the optic. This resulted in a tight seal of the capsule to the lens around these junctions. Other surgeons using one-piece PMMA IOLs with broad optic-haptic junctions found that, in a significant number of cases, there was still cell migration across an intact vitreous face.<sup>5,6</sup> Vasavada et al more recently reported that the posterior optic capture technique, used with foldable three-piece acrylic IOLs that also have narrow optic-haptic junctions, successfully prevented secondary cataract.<sup>7</sup>

It appears that a narrow optic-haptic junction is necessary only with PMMA IOLs. Using the same technique with one-piece foldable hydrophobic acrylic IOLs, we have seen no cell migration across the vitreous face to cause secondary cataract. The IOL material and right-angled edges of these lenses and haptics possibly contribute to the tight barrier at their optic-haptic junctions, preventing cells from getting behind the IOL.

#### ADVANTAGES AND LIMITATIONS

The PCCC technique with optic capture has become quite widely used, with or without anterior vitrectomy, in pediatric cataract surgery, perhaps because in this setting the technique conveys other advantages in addition to prevention of secondary cataract. First, it ensures a stable, centered IOL that is fixed to the capsule. Second, whether used with or without anterior vitrectomy, it has the advantage of maintaining the two separate compartments of the eye. Without optic capture, vitreous elements can have access to the anterior

chamber. The lower incidence of pediatric glaucoma in pseudo-phakic eyes compared with aphakic eyes may be related to the compartmentalization that an optic-captured IOL provides, as the captured optic provides a more definitive, sealed separation of the two compartments.

The double optic capture technique proposed by DeBroff and Nihalani has yet another advantage.<sup>8</sup> With the haptics in the sulcus, the IOL–capsular bag complex will be more stable in the event of progressive zonular weakness.

We know that the haptics of one-piece acrylic IOLs cannot be placed in the sulcus, so both the DeBroff vitrectomy-plus-double-optic capture technique for children and the hyaloid-sparing double capture technique of Arbisser (unpublished) are limited to use with IOLs with thin haptics.

#### ROUTINE USE

In adults, the risk of cell migration behind a PCCC-captured IOL may not be as great as in pediatric cases. However, the established incidence of secondary opacification of the posterior capsule due to lens epithelial cell migration and/or fibrin formation gives merit to the routine use of PCCC with optic capture to eliminate visual axis opacification in adults as well as in children.

In 2008, Menapace published a report of his excellent study of a large series of adult cataract surgeries using PCCC and what he termed *optic buttonholing without vitrectomy*.<sup>9</sup> He recommended that use of this technique for the prevention of secondary cataract in pediatric cataract surgery should be extended to adults to avoid the known risks of Nd:YAG laser capsulotomy. He recommended that buttonholing be done routinely in adult surgery, at least in eyes with pseudoexfoliation syndrome, high axial myopia, peripheral retinal

**“THE PCCC TECHNIQUE WITH OPTIC CAPTURE HAS BECOME WIDELY USED ... IN PEDIATRIC CATARACT SURGERY, PERHAPS BECAUSE ... THE TECHNIQUE CONVEYS OTHER ADVANTAGES IN ADDITION TO PREVENTION OF SECONDARY CATARACT.”**

disease, and/or multifocal IOL implantation.

Complications of Nd:YAG laser posterior capsulotomies are rare, but they do happen. They can include floaters, laser pits on the IOL, incomplete openings that leave small apertures causing glare, retinal detachment, macular edema, macular holes, uveitis, and glaucoma.<sup>10</sup>

Lisa Brothers Arbisser, MD, the guest editor of this cover focus, has taken up the torch in promoting the routine use of PCCC plus optic capture in adult cataract surgery to avoid the necessity for and risks of Nd:YAG laser posterior capsulotomy and to convey the technique’s other advantages. Her technique, unlike DeBroff’s in pediatric cataract, does not include vitrectomy.

#### MANAGING COMPLICATIONS

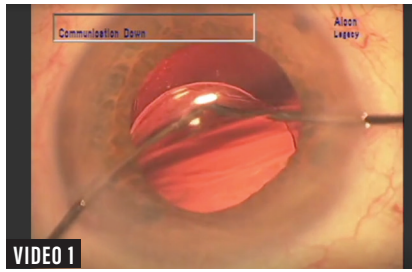
Neuhann’s rhexis fixation and our PCCC with optic capture technique have been used in many ways to manage a number of intraoperative and postoperative complications. In 2004, we published six variations of optic capture, including reverse optic capture (ROC).<sup>11</sup> Masket and Fram described the use of the ROC technique for reducing dysphotopsia.<sup>12</sup> We described its use to rotationally

stabilize a one-piece acrylic toric IOL in a large capsular bag.<sup>13</sup> Jones and colleagues described their technique of ROC for implanting a one-piece acrylic IOL after PC tear and anterior vitrectomy.<sup>14</sup> We have recently described an alternative technique of haptic tuck for ROC in this situation.<sup>15</sup>

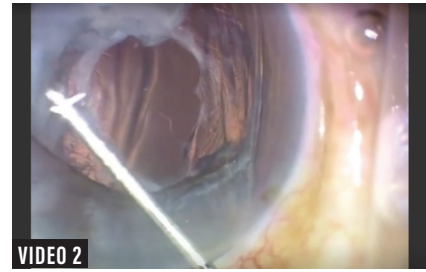
Another variation, membrane optic capture (MOC), is a technique that may be used to manage late complications such as unstable or dislocated IOLs. It also has applications in secondary IOL implantation after extracapsular cataract surgery and in IOL exchanges, in which cases the fibrotic membrane is used for optic capture. Cases in which infant cataract surgery was performed without IOL implantation have been managed later in life with secondary sulcus IOL implantation and MOC. The membrane opening may have to be enlarged with a vitrector or plasma blade such as the Fugo Blade (Medisurg) to allow use of MOC.<sup>16</sup>

Large, thick Soemmering rings must be opened and emptied to avoid having the haptics pushed up against the iris. Some complete, thick rings may be opened outside the fibrotic ring to provide a capsular bag in which to place the haptics.

▶ WATCH IT NOW ◀



VIDEO 1



VIDEO 2

▶ BIT.LY/0119GIMBEL1

▶ BIT.LY/0119GIMBEL2

**CONCLUSION**

Neuhann's rhexis fixation and our PCCC with optic capture techniques have prompted the application of the optic capture concept in a number of other ways, such as ROC with an intact or compromised capsular bag, haptic tuck for ROC, and MOC. Optic capture may also be used in a variety of late complications such as loose sulcus lenses, stable but eccentric lenses, lenses lost partially or completely into the vitreous, IOL exchanges, and secondary IOL implantation. PCCC with optic capture is a useful technique, and surgeons may want to consider adopting its routine use in uncomplicated cataract surgery in adults. ■

- Gimbel HV, Neuhann T. Development, advantages, and methods of the continuous circular capsulorhexis technique. *J Cataract Refract Surg.* 1990;16:31-37.
- Gimbel HV. Posterior capsule tears using phacoemulsification: causes, prevention and management. *European Journal of Implant and Refractive Surgery.* 1990;2:63-69.
- Neuhann TT, Neuhann T. The rhexis-fixed lens. Film presented at: The ASCRS Annual Meeting; April 7-10, 1991; Boston, MA.
- Gimbel HV, DeBroff BM. Posterior capsulorhexis with optic capture: maintaining a clear visual axis after pediatric cataract surgery. *J Cataract Refract Surg.* 1994;20:658-664.
- Vasavada A, Desai J. Primary posterior capsulorhexis with and without anterior vitrectomy in congenital cataracts. *J Cataract Refract Surg.* 1997;23:645-651.

- Vasavada A, Trivedi RH, Singh R. Necessity of vitrectomy when optic capture is performed in children older than 5 years. *J Cataract Refract Surg.* 2001;27:1181-1193.
- Vasavada A, Vasavada V, Shah S, et al. Postoperative outcomes of intraocular lens optic capture in pediatric cataract surgery. *J Cataract Refract Surg.* 2017;43:1177-1183.
- DeBroff BM, Nihalani BR. Double optic capture with capsular bag fusion: a new technique for pediatric intraocular lens implantation. *Techniques in Ophthalmology.* 2008;6(2):31-34.
- Menapace R. Posterior capsulorhexis combined with optic buttonholing: an alternative to standard in-the-bag implantation of sharp-edged intraocular lenses? A critical analysis of 1000 consecutive cases. *Graefes Arch Clin Exp Ophthalmol.* 2008;46(6):787-801.
- Apple DJ, Solomon KD, Tetz MR, et al. Posterior capsule opacification. *Surv Ophthalmol.* 1992;37:73-116.
- Gimbel HV, DeBroff BM. Intraocular lens optic capture. *J Cataract Refract Surg.* 2004;30:200-206.
- Masket S, Fram NR. Pseudophakic negative dysphotopsia: surgical management and new theory of etiology. *J Cataract Refract Surg.* 2011;37:1199-1207.
- Gimbel HV, Amritanand A. Reverse optic capture to stabilize a toric intraocular lens. *Case Rep Ophthalmol.* 2013;4(3):138-143.
- Jones JJ, Oetting TA, Rogers GM, Jin GJ. Reverse optic capture of the single-piece acrylic intraocular lens in eyes with posterior capsule rupture. *Ophthalmol Surg Lasers Imaging.* 2012;43(6):480-488.
- Gimbel HV, Marzouk HA. Haptic tuck for reverse optic capture of a single-piece acrylic toric or other single-piece acrylic intraocular lenses [published online ahead of print December 6, 2018]. *J Cataract Refract Surg.*
- Fugo RJ. Fugo blade to enlarge phimotic capsulorhexis [letter]. *J Cataract Refract Surg.* 2006;32:1900.

**HOWARD V. GIMBEL, MD, MPH, FRCSC**

- Clinical Professor of Ophthalmology, University of Calgary, Calgary, Alberta, Canada
- Clinical Professor of Ophthalmology, Loma Linda University, Loma Linda, California
- Medical Director, Gimbel Eye Center, Calgary, Alberta, Canada
- hvgimbel@gimbel.com
- Financial disclosure: None

**CRST**  
Cataract & Refractive Surgery Today

**TWEETING ABOUT THIS ISSUE? BE SURE TO USE OUR HASHTAG**

**#CRSTODAY**