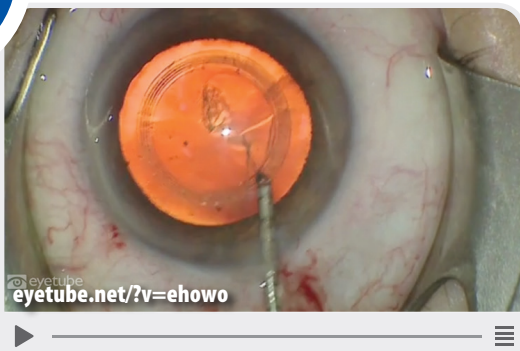


THE BEST OF EYETUBE 2015

Of the many submissions this year to the cataract, refractive, and laser vision correction channels on Eyetube.net, these 10 videos were the most popular.

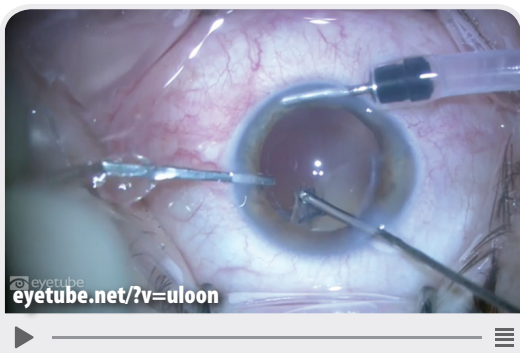
TOP FIVE CATARACT VIDEOS |



No. 1. FIRST EXPERIENCE WITH VERUS

BY AARON WAITE, MD

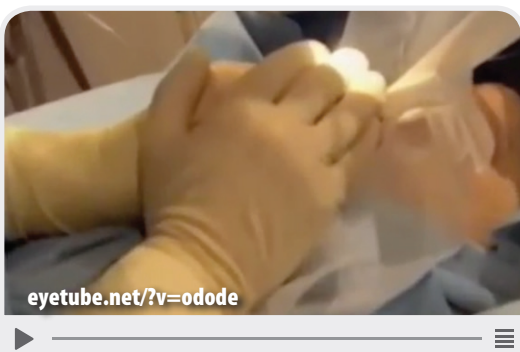Dr. Waite shares his first experience with the Verus ophthalmic caliper (Mile High Ophthalmics) and outlines seven steps for the successful use of the device. The Verus, a biocompatible silicone ring designed to enhance the accuracy and reproducibility of the continuous curvilinear capsulorhexis, fits into the flow of a standard cataract procedure and concludes with a well-centered and round 5-mm capsulotomy.



No. 2. CATARACT SURGERY USING A VITREOUS CUTTER WITHOUT PHACOEMULSIFICATION

BY GURKAN ERDOGAN, MD

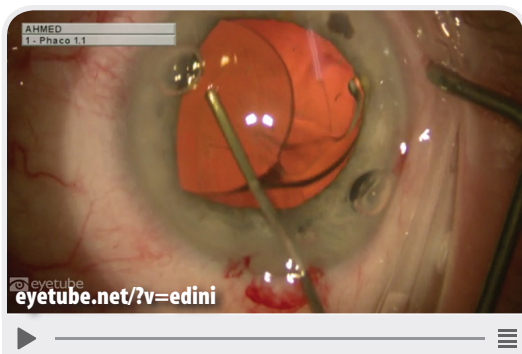
Dr. Erdogan uses a vitreous cutter to remove a cataract in an uncomplicated case.



No. 3. SURGEON'S HAND POSITION DURING CATARACT SURGERY: PEARLS FOR RESIDENTS

BY HOWARD GIMBEL, MD

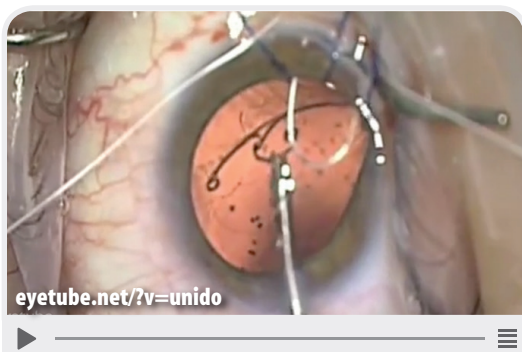Hand and arm positions during cataract and refractive surgery are not often visible when surgical expertise is shared via video or a satellite broadcast of live surgery. Dr. Gimbel provides insights into hand techniques that have been successful for cataract and refractive surgery.



No. 4. IOL EXCHANGE AND DOUBLE OPTIC CAPTURE FOR THE MANAGEMENT OF UVEITIS-GLAUCOMA-HYPHEMA SYNDROME

BY XAVIER CAMPOS, MD; IQBAL IKE K. AHMED, MD; AND MANJOOL SHAH, MD

The surgeons demonstrate the removal of a one-piece acrylic IOL in a bag-sulcus position in a patient with symptomatic uveitis-glaucoma-hypHEMA syndrome. A posterior continuous capsulorhexis is performed, and a three-piece IOL is subsequently implanted in the sulcus and double optic captured posteriorly through the anterior and posterior capsulotomies.



No. 5. IRIDODIALYSIS, CAPSULAR BAG REPAIR, PHACOEMULSIFICATION, AND IOL INSERTION

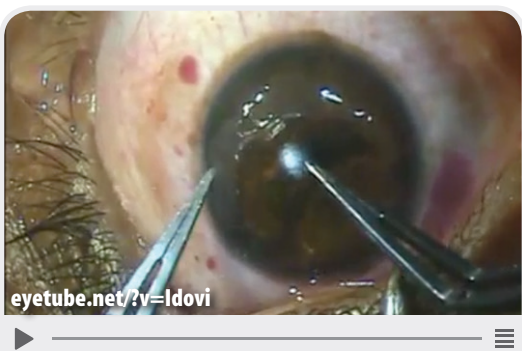BY ALLON BARSAM, MB, BS, MA, FRCOPHTH

Dr. Barsam shares a challenging case involving a patient who had suffered blunt trauma, a large iridodialysis over 120° of zonular weakness. He presents a step-by-step approach to the management of cataract surgery in the presence of multiple ocular traumas.



www.eyetube.net

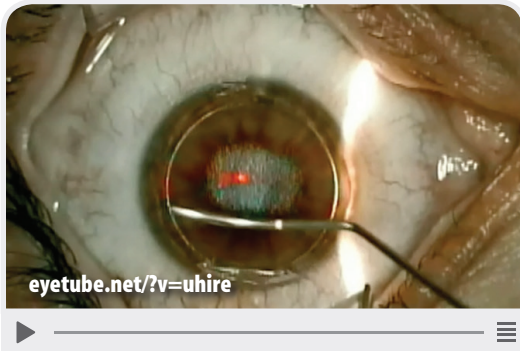
TOP FIVE REFRACTIVE AND LASER VISION CORRECTION VIDEOS |



No. 1. LONGEST REFRACTIVE DAY

BY SOOSAN JACOB, MS, FRCS, DNB

Dr. Jacob shows the sequence of events and explains the management strategy that she employed to address a buttonhole that eventually led to a satisfied patient.



No. 2. DISPOSABLE INSTRUMENTS FOR CREATING AN OVAL FLAP

BY ASIM PIRACHA, MD

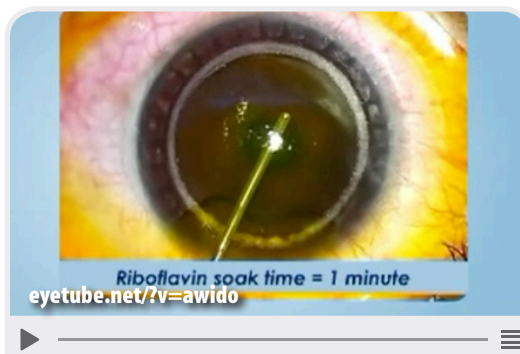
Dr. Piracha creates an oval flap with the 150-kHz iFS femtosecond laser (Abbott Medical Optics) and uses disposable, single-use instruments, including the adjustable speculum, Sinsky hook, and LASIK cannula (Moria) throughout the procedure.



No. 3. ReLEX SMILE TECHNIQUE

BY JOAQUÍN FERNÁNDEZ, MD

Dr. Fernández performs ReLEX small-incision lenticular extraction (Carl Zeiss Meditec) for myopia and astigmatic correction. The video is narrated by Almudena Valero Marcos, MD.



No. 4. FILI KERATOCONUS

BY SRI GANESH, MBBS, MS, DNB

Dr. Ganesh performs femtosecond laser intrastromal lenticule implantation combined with accelerated corneal collagen cross-linking for the treatment of mild to moderate keratoconus. During the procedure, a donut-shaped lenticule is placed in a corneal pocket in order to improve corneal shape and thickness to reduce aberrations.



No. 5. THE EPI BOWMAN KERATECTOMY PROCEDURE

BY ORCA SURGICAL

This video demonstrates the epi Bowman keratectomy technique for epithelium removal, which preserves Bowman layer and creates clear and graduated borders for enhanced healing. ■