Astigmatism and Early Cataracts After Keratotomy

BY MICHAEL G. WOODCOCK, MD; JEFFREY WHITMAN, MD; ARTHUR B. CUMMINGS, FRCSED; AND ALAN R. FAULKNER, MD

CASE PRESENTATION

Case No. 1

A 68-year-old woman presents with a BCVA of 20/30 that drops to 20/50 with glare on brightness acuity testing. The examination is significant for early nuclear sclerotic changes and cortical changes to the lens. A slit-lamp examination reveals previous hexagonal keratotomy surgery on the patient's left eye (Figure 1). Preoperative keratometry (K) readings with the IOLMaster (Carl Zeiss Meditec) show 3.21 D x 140 corneal astigmatism. The rest of the examination is unremarkable.

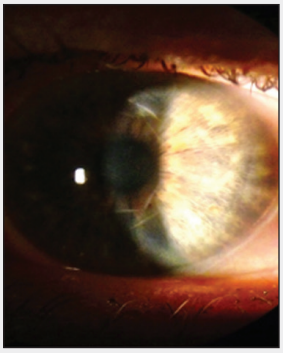

Figure 1. After hexagonal keratotomy.

Case No. 2

A 69-year-old woman presents with a BCVA of 20/40 with glare on brightness acuity testing. Her examination is significant for early nuclear sclerotic changes to the lens and an early posterior subcapsular cataract. A slit-lamp examination reveals a 16-incision radial keratotomy (RK) using a small optical zone and two astigmatic incisions that cross the radial incisions in the patient's right eye. K readings taken with the Lenstar LS900 (Haag-Streit) show 4.34 D x 003 corneal astigmatism, and computed tomography finds 6.80 D x 153 of total corneal astigmatism at the 4-mm zone (Figure 2).

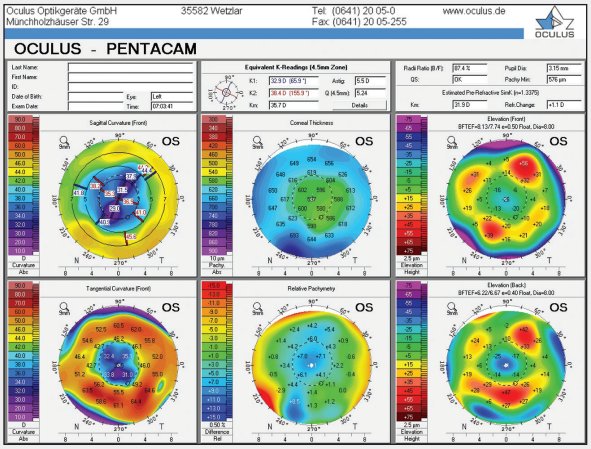

Figure 2. Astigmatism with a defined axis after RK.

How would you proceed pre-, intra-, and postoperatively? What formulas and information would you gather for the IOL power calculations? In the event of an over- or undercorrection, what would you do, and would that be a part of the discussion prior to surgery?

—Cases prepared by Karl G. Stonecipher, MD.

MICHAEL G. WOODCOCK, MD

Any 68-year-old with cataracts and astigmatism should be considered for lens-based refractive surgery. If the 3.00+ D of astigmatism are regular and orthogonal, I would obtain manual K readings. If the mires were good, I would calculate the IOL power using the Holladay 2 formula and estimate the toric IOL power needed to approximate emmetropia. These data can be used as a backup for my go-to method of intraoperative aberrometry using the ORA System (Alcon). I would remove the cataract and obtain an aphakic estimate of the sphere and cylinder needed to achieve emmetropia. I would implant the toric IOL using guidance from the ORA System followed by confirmatory

readings. Should a refractive surprise be verified, the IOL would be exchanged on the spot. With experience and careful observation of IOL position, I find I can reliably execute this maneuver. As an alternative to the immediate exchange for refractive surprises, the IOL could be exchanged a week after settling into position.

I would also replace the lens of the RK patient. Although there is a plethora of approaches to IOL power calculation, I perform a hard contact lens over-refraction, use the Holladay IOL Professional Consultant software (Holladay Consulting), and estimate the power of the toric IOL to give a -0.75 D result. This approach serves as my backup plan should there be any problem with obtaining intraoperative aberrometry measurements. If a patient's preoperative refractions are stable from morning until evening, I find reasonable predictability with the ORA System. When I obtain a pseudophakic reading greater than -1.00 D, I do several things:

- Rotate the IOL and ensure there is no residual viscoelastic behind the lens.
- Tap the IOL to the most posterior position in the bag.
- Repeat the ORA power reading.

If the refraction is still more than -1.00 D, I exchange the IOL in the OR. If the refraction is more than +1.00 D, I move the IOL to the front of the bag by "burping" fluid from the anterior chamber, pressurize the chamber, and take another measurement. If the ORA refraction remains too hyperopic, I exchange the IOL.

After all of these manipulations, it is still possible to be too far off target to satisfy some patients. Although I was originally taught that LASIK over RK can cause significant scarring, I have only experienced one such case in 19 years, so I will perform LASIK on these patients still needing an enhancement. Surgeons need to be cautious about performing enhancements too early, because these corneas may take several months to stabilize.

JEFFREY WHITMAN, MD

The patient in the first case who underwent hexagonal keratotomy exhibits central corneal steepening and, for this procedure, not much asymmetric irregularity. I have had success in cases such as this one using the Lenstar's K readings for the flat K. Then, I take the axes from the Orbscan (Bausch + Lomb) or similar topography as well as the amount of cylinder, which I add to the flat axis from the Lenstar to obtain the new steep axis. I enter this information into the Shammas formula for posthyperopic LASIK eyes to choose the spherical power for the lens and then the Barrett formula for the toric power and the axial location (both formulas available on the American Society of Cataract and Refractive Surgery's website). As after RK, it usually takes 4 to 6 weeks before a stable refraction can be obtained. I would wait 3 months before considering an enhancement. I would explain to the patient preoperatively that she might need glasses or a hard contact lens to achieve the best possible visual acuity postoperatively. If the patient's refractive error after surgery were spherical, I would consider a piggyback lens only; I do not like performing laser correction after hexagonal keratotomy, hyperopic LASIK, or hyperopic automated lamellar keratoplasty, because the results are unpredictable.

I would tell the post-RK patient that her visual acuity will continue to shift from morning until evening no matter what surgical intervention is pursued. I would not recommend any premium modality other than a toric IOL, and even then, the cornea will "trampoline" throughout the day. That said, I would proceed much as I would when treating a patient who underwent a four- or eight-cut RK procedure. (My colleagues and I performed about 20,000 RK surgeries in my practice, so we have worked at getting the best postoperative results possible.)

I obtain an effective refractive potential value using the EyeSys Corneal Analysis System (Tracey Technologies) for the surgeon-modified value. I take the flat K reading from the Lenstar and, then, both the axis and the amount of cylinder from the topography (Orbscan), and I plug these into the Holladay 2 formula. I find that the Lenstar provides an accurate phakic measurement of the anterior chamber depth as well as lens thickness. I use the white-to-white from the Orbscan. Next, I take the spherical value closest to producing a -0.50 D result and use this for the spherical value if the patient chooses a traditional lens with no toric correction and will wear glasses or a hard contact lens postoperatively. I advise the patient preoperatively that it will take 4 to 6 weeks for the refraction to stabilize.

If the patient will receive a toric lens, I place the aforementioned numbers into the Barrett formula to give me both the toric amount and axis. If the K readings are too flat for the Barrett formula (which takes posterior corneal astigmatism into account), then I enter the numbers directly into the AcrysofToric calculator (Alcon). After the refraction stabilizes, the patient is either fit for a hard contact lens or glasses. If a change in spherical power is needed, I consider a piggyback lens.

ARTHUR B. CUMMINGS, FRCSED

These tricky cases are becoming more common as the RK generation develops cataracts. Results in this population are even less predictable than in patients with a

history of LASIK or PRK. Two approaches have served me well to date.

The first is to correct the cornea with topography-guided PRK, wait 6 months, and then treat the cataract. This approach will produce a more regularly shaped cornea prior to cataract surgery, which should increase the predictability of IOL power calculation and produce a better overall quality of vision postoperatively.

The second option is to perform cataract surgery first and purposely target a hyperopic refraction for the flat cornea (eg, +3.00 D) or a myopic target for a steep cornea (eg, -3.00 D). When PRK is performed sometime after the cataract surgery to fine-tune and regularize the corneal shape via a topography-guided profile, the steep cornea is flattened, and the flat cornea is steepened. The end result is a more physiological corneal shape that is also more regular on topography.

Incisional cases typically have no shortage of tissue, because the previous procedures did not remove tissue. It is also important to examine the radial incisions carefully to verify an absence of epithelial ingrowth and plugs. If these findings are present, the preferred approach is to clean out the incisions and then close them with nonabsorbable 10–0 or 11–0 sutures. These sutures can be removed over time as the topography dictates. Once the surgeon is satisfied with the corneal shape, it may be wise to perform epithelium-on corneal collagen cross-linking (procedure not approved in the United States) in order to strengthen the incisions. Epithelium-off cross-linking should be avoided, because the procedure would damage the remaining corneal sutures that are under strain and influencing the corneal shape.

I have no personal experience with the technology but understand that intraoperative aberrometry may be highly useful in cases such as these. It is very important to inform patients that their complex situation means refractive results may be less predictable and that they may require more than one laser vision correction procedure to achieve the desired outcome.

ALAN R. FAULKNER, MD

Both cases must be analyzed individually. The obvious problem is determining what the true K readings in the visual axis are and probably, to a lesser degree, which IOL formula will be the most accurate. I like to obtain multiple topographic measurements and K readings for comparison. In particular, I like to look at the Magellan Mapper's ACP (average corneal power; Nidek), which is determined over the undilated pupil, as well as the corneal aberrometry maps. With the Pentacam Comprehensive Eye Scanner (Oculus), I use the detailed Holladay report to look at the K readings over the range of zones, and I pay most attention to the zone that matches the size of the patient's pupil.

If I were trying to attain the best UCVA in the first case, I would choose a nonaspheric toric IOL, because hexagonal keratotomy creates a hyperprolate cornea. In the second case, I would implant an aspheric toric lens. I would absolutely not select a multifocal lens. I would attempt intraoperative aberrometry, but the results may be unreliable for highly aberrated corneas and must be considered in light of the preoperative analysis.

In both of the presented cases, preoperative counseling should address the large margin of error and the potential for dissatisfaction with visual quality postoperatively. If the targeted outcome were missed, I would wait at least 2 weeks for the IOL to settle and the refraction to stabilize. Then, I would refer to astigmatismfix.com to determine if rotating or exchanging the IOL might yield an improvement. I would avoid a laser refractive procedure, if possible. ■

Section Editor Stephen Coleman, MD, is the director of Coleman Vision in Albuquerque, New Mexico.

Section Editor Karl G. Stonecipher, MD, is the director of refractive surgery at TLC in Greensboro, North Carolina. Dr. Stonecipher may be reached at (336) 288-8523; stonenc@aol.com.

Arthur B. Cummings, FRCSEd, is a consultant ophthalmologist at the Wellington Eye Clinic and UPMC Beacon Hospital in Dublin, Ireland. Dr. Cummings may be reached at abc@wellingtoneyeclinic.com.

Alan R. Faulkner, MD, is the founder of and is in private practice with Aloha Laser Vision in Honolulu, Hawaii. He acknowledged no financial interest in the products or companies he mentioned. Dr. Faulkner may be reached at (808) 792-3937; dralan@alohalaser.com.

Jeffrey Whitman, MD, is the president and chief surgeon of the Key-Whitman Eye Center in Dallas. He acknowledged no financial interest in the products or companies he mentioned. Dr. Whitman may be reached at (800) 442-5330; whitman@keywhitman.com.

Michael G. Woodcock, MD, practices with Carolina Vision Center, with locations in Fayetteville and Charlotte, North Carolina. He is a member of the Medical Advisory Board for WaveTec Vision, and he had stock options, which were exercised after the sale to Alcon. Dr. Woodcock may be reached at (910) 485-3937; lasikpro@gmail.com.