

ENSURE TORIC IOLs' STABILITY

Pay close attention to wound construction and sealing.

BY DANIEL H. CHANG, MD



The rotational stability of a toric IOL is crucial to a successful outcome. For the best visual acuity results, the IOL should be placed and remain within 5° of the axis of astigmatism. Postoperative IOL misalignment is commonly due to errors in preoperative biometry and marking—important topics that are not addressed in this article.

Assuming the surgeon places the IOL correctly, why is there any rotation at all?

The exact mechanism for toric lens rotation is not well understood. The lens is confined within the bag where there is no bulk fluid flow or other internal force vectors after surgery. Rotation is therefore likely due to external forces applied to the eye. If an eye were hypotonous, forceful blinking, eye rubbing, or the pressure of a dropper bottle could transmit a force to the IOL. Compressing a hypotonous eye is therefore likely the primary mechanism for toric IOL rotation. Gross deformation of the globe could cause a shift in the IOL's position.

After implanting more than 300 Tecnis Toric IOLs (Abbott), I have only had to reposition one. This is due in

part to the excellent stability of the lens itself. In clinical trials, it had a mean axial change of just 2.74° between baseline and 6 months. More than 90% of the lenses rotated 5° or less between visits 3 months apart (Figure). Good surgical technique is key. Here are four steps for ensuring that a toric IOL is properly aligned for optimal results.

STEP
No. 1

BE METICULOUS ABOUT WOUND CONSTRUCTION

Whether using a femtosecond laser or a blade, construct a triplanar incision that will seal well at the end of the case. It should be nearly square and long enough for good wound closure.

STEP
No. 2

CREATE A WELL-CENTERED CAPSULOTOMY

A full 360° of capsular overlap may help to limit asymmetric capsular forces on the IOL postoperatively.

STEP
No. 3

POSITION THE IOL CORRECTLY IN A CLEAN CAPSULE

IOL implantation should be done with a cohesive viscoelastic for easy and complete removal at the end of the case. As the lens unfolds, I rotate it in the bag several times and perform aspiration behind the IOL. This process helps to clear out retained viscoelastic and cortical debris. It also ensures that the haptics are fully deployed into the capsular fornix. Once the haptics have unfolded completely, I center the IOL by having the patient fixate on a coaxial light source. Then, I align the marks on the IOL with the corneal axial marks on the steep meridian. The IOL need not align perfectly with these axial marks. As long as it is parallel to the marks, it is more important to center the IOL well.

STEP
No. 4

ENSURE A TIGHTLY SEALED WOUND

I hydrate the wound to seal it and bring the eye to physiologic pressure, while being careful not to under- or hyperinflate it. With the chamber stable, I can fine-tune the lens' position before finally rehydrating and

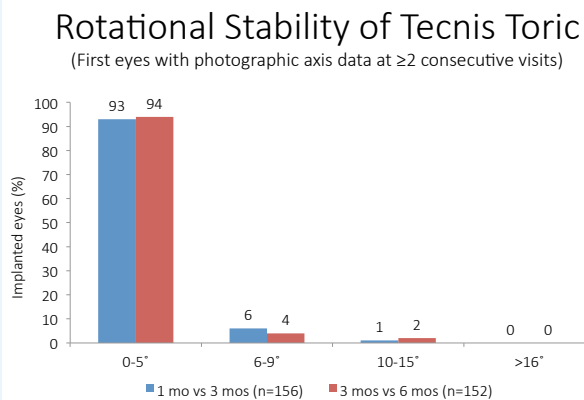
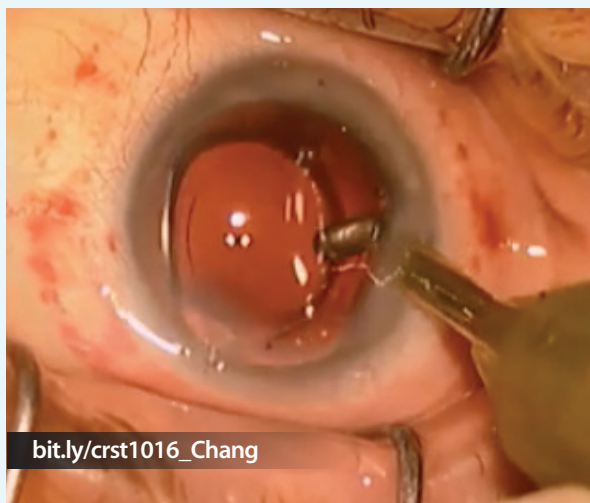


Figure. Excellent stability has been reported for the Tecnis Toric IOL. Surgeons can further maximize stability by following the techniques described in this article.

WATCH IT NOW

Daniel H. Chang, MD, demonstrates the lens positioning steps outlined in this article.



checking the wounds and the IOL's position one last time. When checking the wound, I dry it to find slow leaks and press on the globe to simulate an eye rub. When in doubt, I suture the wound or consider a sealant.

CONCLUSION

Postoperatively, I instruct patients not to rub their eyes. I try to minimize the dosing regimen of postoperative drops with combination products or dropless surgery. This reduces the chance that patients will rub their eyes or poke them with the bottle, which I suspect is a common occurrence.

With these steps (see *Watch It Now*), surgeons can be confident that their toric IOLs will remain stable to successfully correct astigmatism in refractive cataract patients. ■

Daniel H. Chang, MD

- private practice at Empire Eye and Laser Center in Bakersfield, California
- (661) 325-3937; dchang@empireeyelandlaser.com
- financial disclosure: consultant to Abbott