

Cataract Surgery in the Setting of Pseudoexfoliation

Careful planning and adjustments to one's surgical technique can assuage the challenges associated with this condition.

BY ALAN LOWINGER, MD, AND BONNIE AN HENDERSON, MD

Pseudoexfoliation (PXF) is a progressive condition involving the deposition of an abnormal fibrillar protein. Accumulations of this protein in the trabecular meshwork can elevate IOP, and it negatively affects pupillary dilation if it is deposited in the iris. There is an increased risk of cataract, possibly due to ischemia¹ or antioxidant imbalance.² Zonules can also be affected, resulting in fragility and an unstable capsular bag. Compared to those without the condition, cataract surgery in eyes with PXF can be more challenging, with a higher risk of complications. Zonular dialysis, capsular rupture, vitreous loss, and late dislocation of an implanted IOL can occur more

“Zonular dialysis, capsular rupture, vitreous loss, and late dislocation of an implanted IOL can occur more frequently in this patient population.”

frequently in this patient population. Fortunately, many of the difficulties associated with PXF can be mitigated or reduced through optimal surgical planning and technique.

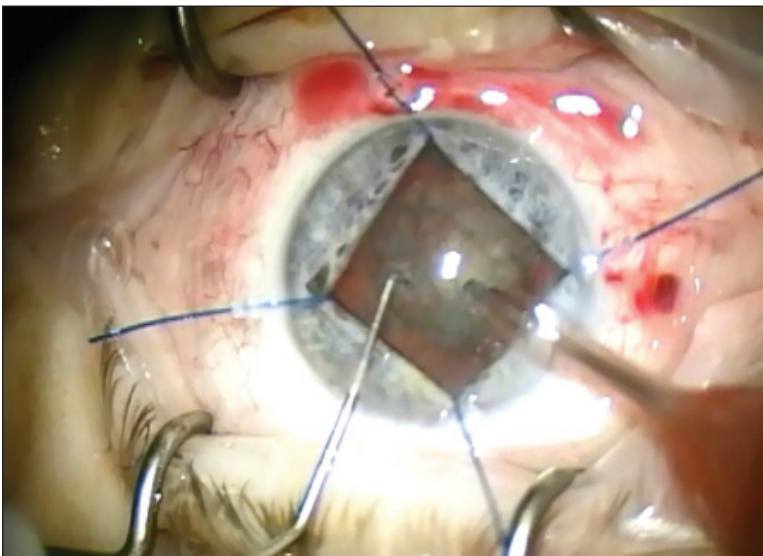


Figure. An eye with PXF and late subluxation of the IOL.

PREOPERATIVE EVALUATION

The first step is to properly diagnose PXF, because signs of the condition can be subtle and are often missed at the slit lamp. A careful evaluation for a Sampaolesi line on gonioscopy, white pupillary ruff, and subtle anterior capsular PXF deposition can be crucial to the diagnosis. These features are often asymmetric.

Careful measurement of pupillary dilation should be noted for proper surgical planning. The measurement of any frank dislocation or more subtle signs of zonular weakness such as phacodonesis is also important. A great and asymmetric anterior chamber depth preoperatively may suggest zonular laxity. Another key step is to ask patients if they have a history of ocular trauma.

INTRAOPERATIVE ADJUSTMENTS

The Pupil

The pupil tends to dilate poorly in eyes with PXF, which can lead to decreased visualization of the capsular bag and lens and thus a smaller capsulotomy. We recommend administering nonsteroidal anti-inflammatory drugs and dilating drops preoperatively to reduce intraoperative miosis and aid with pupillary dilation. If the pupil is not well dilated, viscoelastic or mechanical stretching as well as iris hooks or a pupillary expansion ring can be attempted. In eyes without iris hooks or a pupillary ring, care should be taken to avoid contact with the iris during surgery to prevent additional constriction of the pupil (Figure).

Capsular Opening

A small capsulotomy can occur in the setting of a small pupil and can increase the chance of inadvertent phaco-capsular touch, leading to an anterior capsular tear. Additionally, the risk of placing a chopper or second instrument on top of the capsulotomy is greater when the opening is small. Postoperatively, small openings are associated with progressive capsular phimosis,³ and PXF patients are already at higher risk for phimosis.^{3,4} This phimosis, along with progressive zonular weakness, likely contributes to pseudophacodonesis and dislocation.⁵

We aim for a capsular opening of 5 to 5.5 mm. Too large a capsulotomy can increase the risk of the haptics' accidental placement into the sulcus. Implanting capsular tension rings can also be difficult if the capsulotomy is too big.

Wrinkling instead of a clear cut from the initial puncture of the capsule with a cystotome can be an early sign of zonular weakness. There is less countertraction with loose zonules, which may complicate propagation of the tear. In cases like these, we recommend using capsular hooks to support the capsular bag and offer countertraction.

If the capsular opening is small, we recommend secondary enlargement after IOL implantation with scissors or a cystotome to make an additional nick in the capsulotomy. Next, the surgeon can use forceps to create a flap that can be torn circumferentially to enlarge the opening.

Hydrodissection and Hydrodelineation

As with all phaco cases but especially in eyes with PXF, proper hydrodissection is important to separate the lens from the bag and to minimize zonular stress during rotation. Hydrodelineation can be useful to remove the inner nucleus before attempting to rotate the entire lens.

“Eyes with PXF are at elevated risk of IOP spikes and increased postoperative inflammation.”

Phacoemulsification

When performing phacoemulsification in eyes with PXF, we minimize repeated rotation of the lens and recommend a gentle rotation of the nucleus with two instruments to reduce stress on the zonules. In our experience, a chopping technique is less taxing on ocular structures than divide and conquer. We lower the fluidic parameters by decreasing the bottle height and reducing vacuum and aspiration. These adjustments decrease fluctuations in the anterior chamber, which could exert further stress on the zonules.

IOLs and Capsular Tension Rings

Some surgeons prefer to implant a capsular tension ring (CTR) in all eyes with PXF, but we tend to implant one only in the presence of phacodonesis or obvious zonular weakness in any area. An oval capsulotomy can be a sign of zonular weakness. CTRs should not be used if an anterior or posterior capsular tear is present.

In eyes with less than 5 clock hours of zonular weakness, we place a sutureless CTR. We have found that positioning the haptic of the IOL on the axis of zonular weakness provides additional support for lens centration. If the eye has more than 5 clock hours of zonular dialysis, we use a sutured CTR or capsular tension segment.

We prefer a three-piece IOL in eyes with zonular weakness, because the haptics are more rigid and function similarly to a CTR by distributing the forces and centering the bag. Additionally, if the IOL-capsular bag complex dislocates at a later time, we find that a three-piece IOL is easier to suture to the sclera or iris.

Implanting presbyopia-correcting IOLs in eyes with PXF can be challenging due to late decentration and insufficient accommodative movement of the lens diaphragm. We suggest caution and proper informed consent when implanting premium IOLs in these patients.

POSTOPERATIVE CONSIDERATIONS

Eyes with PXF are at elevated risk of early IOP spikes⁶⁻⁸ and increased postoperative inflammation,⁹ both of which can be managed with additional IOP-lowering medications and steroids as needed. Anterior

(Continued on page 44)

(Continued from page 40)

capsular phimosis can occur later in the postoperative period and can lead to decentration and tilt of an implanted IOL. We recommend performing relaxing incisions with an Nd:YAG laser as soon as phimosis becomes apparent.

CONCLUSION

Eyes with PXF can be difficult to manage. Preoperative clues such as poorly dilating pupils, darker pigmentation on gonioscopy, and phacodonesis are additional findings besides the deposition of the fibrillar protein seen on the anterior capsules. Intraoperative adjustments to the fluidics and technique and adjunct equipment are beneficial. With proper planning, cataract surgery in eyes with PXF can be successful. Preoperative counseling to inform the patient of the associated increased risks is important. ■

Bonnie An Henderson, MD, is a partner in Ophthalmic Consultants of Boston and a clinical professor at Tufts University School of Medicine in Boston. Dr. Henderson may be reached at (781) 487-2200, ext. 3321; bahenderson@eyeboston.com.



Alan Lowinger, MD, is a cataract and glaucoma surgeon at the New England Eye Center in Boston and an assistant professor at Tufts University School of Medicine in Boston. Dr. Lowinger may be reached at (617) 636-8108.



- Schlotzer-Schrehardt U, Naumann GOH. Ocular and systemic pseudoexfoliation syndrome [perspective]. *Am J Ophthalmol*. 2006;141:921-937.
- Yilmaz A, Adigüzel U, Tamer L, et al. Serum oxidant/antioxidant balance in exfoliation syndrome. *Clin Exp Ophthalmol*. 2005;33:63-66.
- Davison JA. Capsule contraction syndrome. *J Cataract Refract Surg*. 1993;19:582-589.
- Hayashi H, Hayashi K, Nakao F, Hayashi F. Anterior capsule contraction and intraocular lens dislocation in eyes with pseudoexfoliation syndrome. *Br J Ophthalmol*. 1998;82:1429-1432.
- Shingleton BJ, Crandall AS, Ahmed II. Pseudoexfoliation and the cataract surgeon: preoperative, intraoperative and postoperative issues related to intraocular pressure, cataract, and intraocular lenses. *J Cataract Refract Surg*. 2009;35(6):1101-1120.
- Pohjalainen T, Vesti E, Uusitalo RJ, Laatikainen. Intraocular pressure after phacoemulsification and intraocular lens implantation in nonglaucomatous eyes with and without pseudoexfoliation. *J Cataract Refract Surg*. 2001;27:426-431.
- Shingleton BJ, Laul A, Nagao K, et al. Effect of phacoemulsification on intraocular pressure in eyes with pseudoexfoliation: single surgeon series. *J Cataract Refract Surg*. 2008;34:1834-1841.
- Levkovich-Verbin H, Habot-Wilner Z, Burla N, et al. Intraocular pressure elevation within the first 24 hours after cataract surgery in patients with glaucoma or exfoliation syndrome. *Ophthalmology*. 2008;115:104-108.
- Schumacher S, Nguyen NX, Kuchle M, Naumann GOH. Quantification of aqueous flare after phacoemulsification with intraocular lens implantation in eyes with pseudoexfoliation syndrome. *Arch Ophthalmol*. 1999;117:733-735.

Additional resources:

- Chang D, ed. *Phaco Chop and Advanced Phaco Techniques: Strategies for Complicated Cataracts*. 2nd ed. Thorofare, NJ: Slack, Inc.; 2013.
- Henderson BA, ed. *Essentials of Cataract Surgery*. 2nd ed. Thorofare, NJ: Slack, Inc.; 2014.
- Shingleton BJ, Crandall AS, Ahmed II. Pseudoexfoliation and the cataract surgeon: preoperative, intraoperative, and postoperative issues related to intraocular pressure, cataract, and intraocular lenses. *J Cataract Refract Surg*. 2009;35(6):1101-1120.
- Steinert RF, ed. *Cataract Surgery*. 3rd ed. Philadelphia: Saunders/Elsevier; 2010.