

Can Corneal Inlays Grow the Presbyopic Treatment Market?

As US surgeons await FDA approval of the technology, real-world and clinical trial experience shows great promise.

BY JOHN A. HOVANESIAN, MD

Three corneal inlays are designed to reverse presbyopia, but none is currently available in the United States. The Kamra (AcuFocus) has been submitted for US approval and has received a favorable vote from the FDA Ophthalmic Devices Panel. The Raindrop (ReVision Optics) is in the midst of phase 3 studies that began in 2013. The Presbia Flexivue Microlens (Presbia) just entered phase 2 studies (Figure 1). All of the devices have CE Mark approval.

No approved technology that supports the emmetropic presbyope has been embraced as readily by patients as these devices have been outside the United States.



“No approved technology that supports the emmetropic presbyope has been embraced as readily by patients as these devices have been outside the United States.”

Although surgeons are only correcting the nondominant eye, patients do not consider the result to be monovision. In trials of all three technologies, patients routinely retained a distance visual acuity of 20/25 or better and were highly satisfied with the result.

OVERVIEW

There is no need to remove an inlay to perform cataract surgery. Moreover, because patients' presbyopia has already been corrected, they probably will not need a presbyopia-correcting IOL.

Tan and Mehta found the SRK/T formula to be accurate for calculating IOL power in eyes that had previously received the Kamra inlay.¹

In addition to the similarities already mentioned, all three inlays use pockets for implantation and are associated with a low rate of complications. Surgical technique is also fairly similar across the platforms and entails a rather short learning curve for physicians familiar with refractive surgery.

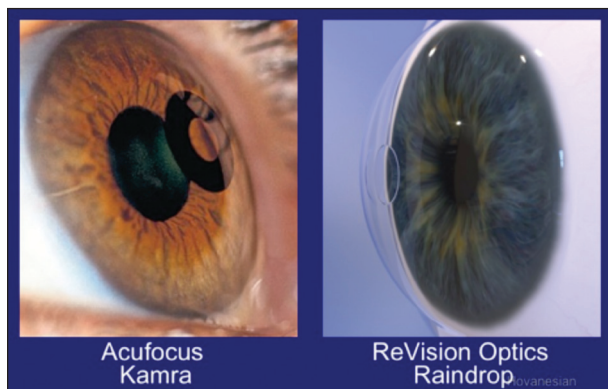


Figure 1. The two corneal inlays closest to receiving US marketing approval.

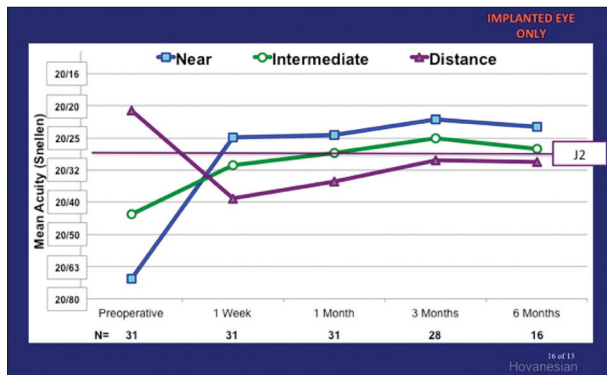


Figure 2. Mean monocular UCVA with the Raindrop.

KAMRA

The Kamra is a small-aperture inlay composed of polyvinylidene fluoride.² The 1.6-mm central annulus acts as a pinhole, and the outer diameter measures 3.8 mm.²

Although the device is visible, especially in eyes with light irides, I do not anticipate a major backlash from patients, based on how well accepted the device has been in Europe. The Kamra reduces some light in the cornea, but again, I do not expect that to be a major problem.

In numerous studies of the inlay, patients achieved a visual acuity of 20/20 at distance and J2 at near.³⁻⁶ The device has been shown to be equally impressive

in pseudophakic patients^{4,7} and in those undergoing simultaneous bilateral LASIK.⁸

RAINDROP

Composed of hydrogel, the Raindrop features a space-occupying lenticule that creates a hyperprolate cornea.² This differential change in surface curvature creates a multifocal cornea.² The diameter of the inlay was enlarged to 2 mm, which expands the near optical zone and improves useful near vision. Based on 1-year results, patients achieve a visual acuity of 20/40 as early as 1 week postoperatively and report a high level of satisfaction.⁹

The protocol of the US phase 3 studies (n = 75) uses a LASIK flap, but investigations outside this country are studying the implantation of the device under a 150- μ m corneal pocket. Based on my personal results (N = 30), patients can achieve a near visual acuity of J2 through 6 months (Figure 2).

Outside the United States, studies are underway in which the inlay is combined with concurrent bilateral LASIK. The early results are promising, with vision gained at all points and a high rate of satisfaction among patients.¹⁰

From my experience, continual hydration is imperative during the device's implantation. Too wet a surgical field causes the device to move around too much, but

CORNEAL INLAYS AT A GLANCE

KAMRA

Implanted in the patient's nondominant eye, the Kamra (AcuFocus) uses the principle of small-aperture optics to improve near vision while minimally changing distance vision. Manufactured from polyvinylidene, the inlay is 5 μ m thick and features 8,400 fenestrations to maintain metabolic flow to the anterior cornea.¹ The device is placed at a depth of approximately 200 μ m under a LASIK flap. More than 20,000 patients across four continents have received the technology.

RAINDROP

The Raindrop (ReVision Optics) is the first and only corneal inlay that creates a prolate cornea. The device is placed under a 150- μ m corneal flap. The hydrogel lenticule is approximately 2 mm in diameter and 30 μ m thick. The phase 3 study is currently enrolling 75 patients.

PRESBIA FLEXiVUE MICROLENS

With a diameter of 3 mm and an edge thickness of approximately 15 μ m, the Presbia FlexiVue Microlens is barely discernible when placed within the corneal stroma. The device is made of a hydrophilic polymer and is implanted in the patient's nondominant eye. The current clinical study will enroll a total of 412 patients at up to 30 investigational sites in the United States, who will be observed through 36 months postoperatively.

1. Waring GO 4th, Klyce SD. Corneal inlays for the treatment of presbyopia. *Int Ophthalmol Clin*. 2011;51(2):51-62.

excessive dryness makes the device difficult to adjust. Postoperatively, only one of my patients complained of halos (at 1 month but not later), and one patient complained of glare at 3 months. Patients' satisfaction across multiple settings was 92% to 93% at 1 year.

PRESBIA FLEXI^{VUE} MICROLENS

This is the only inlay using a refractive add power. The central zone is free of refractive power. The peripheral zone has a standard refractive power with an index of refraction that is higher than that of the cornea, generating +1.25 to +3.00 D of add power.² Published case studies suggest improvements in near visual acuity from J6 to J1 or 20/50 to 20/20.^{11,12}

Limnopoulou et al evaluated 47 emmetropic presbyopes. At 12 months, near UCVA was 20/32 or better in 75% of operated eyes, and mean distance UCVA decreased significantly from 20/20 to 20/50. Binocular distance UCVA did not change significantly.¹³

CONCLUSION

Corneal inlays have the potential to serve millions of people—particularly those over the age of 50. I look forward to the availability of these devices in the United States. ■

John A. Hovanesian, MD, is in private practice at Harvard Eye Associates in Laguna Hills, California, and he is on staff at the UCLA Jules Stein Eye Institute in Los Angeles. He is a paid consultant to ReVision Optics and a member of its medical advisory board. Dr. Hovanesian may be reached at jhovanesian@harvardeye.com.



1. Tan TE, Mehta JS. Cataract surgery following Kamra presbyopic implant. *Clin Ophthalmol*. 2013;7:1899-1903.
2. Waring GO 4th, Klyce SD. Corneal inlays for the treatment of presbyopia. *Int Ophthalmol Clin*. 2011;51(2):51-62.
3. Tomita M, Huseynova T. Evaluating the short-term results of KAMRA inlay implantation using real-time optical coherence tomography-guided femtosecond laser technology. *J Refract Surg*. 2014;30(5):326-329.
4. Huseynova T, Kanamori T, Waring GO 4th, Tomita M. Small-aperture corneal inlay in presbyopic patients with prior phakic intraocular lens implantation surgery: 3-month results. *Clin Ophthalmol*. 2013;7:1683-1686.
5. Seyeddain O, Bachernegg A, Riha W, et al. Femtosecond laser-assisted small-aperture corneal inlay implantation for corneal compensation of presbyopia: two-year follow-up. *J Cataract Refract Surg*. 2013;39(2):234-241.
6. Dextl AK, Seyeddain O, Riha W, et al. One-year visual outcomes and patient satisfaction after surgical correction of presbyopia with an intracorneal inlay of a new design. *J Cataract Refract Surg*. 2012;38(2):262-269.
7. Huseynova T, Kanamori T, Waring GO 4th, Tomita M. Outcomes of small aperture corneal inlay implantation in patients with pseudophakia. *J Refract Surg*. 2014;30(2):110-116.
8. Tomita M, Kanamori T, Waring GO 4th, et al. Simultaneous corneal inlay implantation and laser in situ keratomileusis for presbyopia in patients with hyperopia, myopia, or emmetropia: six-month results. *J Cataract Refract Surg*. 2012;38(3):495-506.
9. Garza EB, Gomez S, Chayet A, Dishler J. One-year safety and efficacy results of a hydrogel inlay to improve near vision in patients with emmetropic presbyopia. *J Refract Surg*. 2013;29(3):166-172.
10. Chayet A, Barragan Garza E. Combined hydrogel inlay and laser in situ keratomileusis to compensate for presbyopia in hyperopic patients: one-year safety and efficacy. *J Cataract Refract Surg*. 2013;39(11):1713-1721.
11. Stojanovic NR, Panagopoulou SI, Pallikaris IG. Refractive corneal inlay for near vision improvement after cataract surgery. *J Cataract Refract Surg*. 2014;40(7):1232-1235.
12. Bouzoukis DI, Kymionis GD, Limnopoulou AN, et al. Femtosecond laser-assisted corneal pocket creation using a mask for inlay implantation. *J Refract Surg*. 2011;27(11):818-820.
13. Limnopoulou AN, Bouzoukis DI, Kymionis GD, et al. Visual outcomes and safety of a refractive corneal inlay for presbyopia using femtosecond laser. *J Refract Surg*. 2013;29(1):12-18.