Perfecting Presbyopia-Correcting IOL Surgery

Success with these lenses demands that surgeons reduce postoperative refractive errors.

BY WILLIAM F. WILEY, MD

Intraoperative aberrometry has become a valuable tool for all toric and presbyopia-correcting IOL cases in my practice. Patients' high expectations combined with the complex optics of these lenses makes it imperative that we surgeons fully correct refractive errors. In particular, true corneal astigmatism is often different from what we expect it to be based on preoperative measurements. This discrepancy is due to the contributions of the posterior corneal curvature or surgically induced astigmatism. Without intraoperative aberrometry, I find it is difficult to manage astigmatism effectively in premium IOL cases.

Based on intraoperative information obtained from the ORA System with VerifEye (WaveTec Vision), I alter my planned IOL power selection in about one-third of cases and adjust my astigmatic management plan in another one-third of cases. The two cases presented herein illustrate how intraoperative aberrometry helps me make surgical decisions that benefit my patients receiving presbyopia-correcting IOLs.

CASE No. 1. MULTIFOCAL IOL WITH AMBIGUOUS CYLINDER

I performed surgery on a 76-year-old woman with a preoperative refraction of -2.00 -100 x 100 OD and -4.00 -0.75 × 85 OS. With a goal of good near and far UCVA, I planned to implant a Tecnis Multifocal IOL (Abbott Medical Optics) in both eyes, beginning with the nondominant left eye.

Keratometry readings with the IOLMaster (Carl Zeiss Meditec) were 45.49 D/46.55 D for 1.06 D of astigmatism at 172° in the left eye. According to my personalized nomogram, limbal relaxing incisions (LRIs) were not required, but the amount of astigmatism—which varied among the IOLMaster, manual keratometry readings, and topography—was very close to when I would perform LRIs.

As with all of my presbyopic correction cases, I had several IOL options available in the OR, and I used the

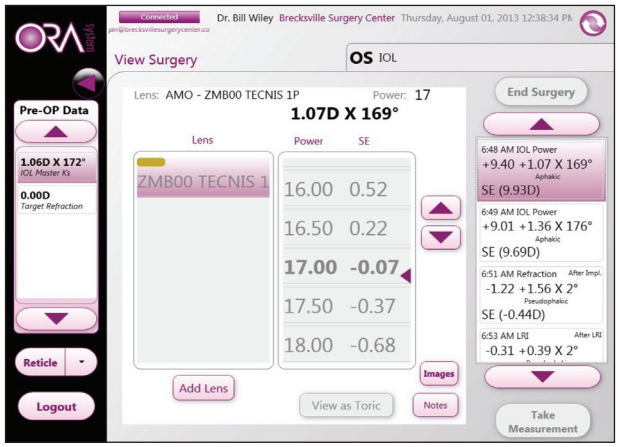

Figure 1. ORA aphakic screenshot guiding the surgeon's IOL choice for case No. 1.

ORA System's aphakic refraction to decide which lens power would provide the least residual error (Figure 1). I implanted a 16.50 D Tecnis Multifocal IOL.

The intraoperative measurements also showed more astigmatism than any of the preoperative measures would have predicted. VerifEye streams refractive information superimposed on a live video display of the eye throughout a procedure, allowing me to monitor critical parameters and watch the effect of the incisions in real time, which I describe as a "smart blade" technique. I use real-time intraoperative information to guide the axial placement and length of the incision versus simply relying on questionable preoperative information to determine these paramaters (Figure 2). The initial incision reduced the astigmatism by about half. Because more cylinder remained than I preferred, I performed an LRI enhancement with the patient on the OR table to reduce her astigmatism nearly to zero.

eyetube.net
eyetube.net/?v=ugode

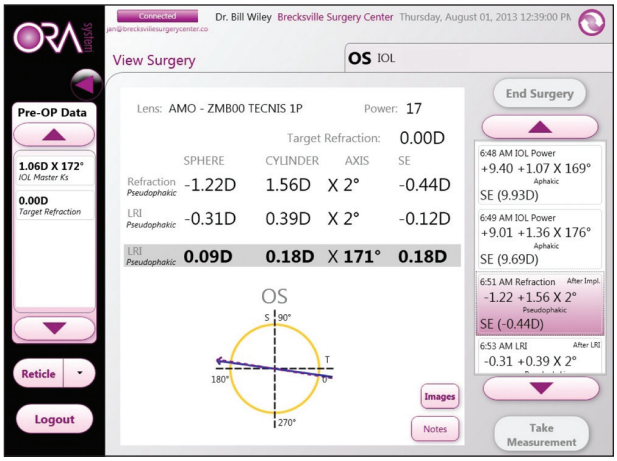

Figure 2. ORA pseudophakic screenshot showing the original cylinder and the cylinder after the placement of LRIs and after the LRI enhancement for case No. 1.

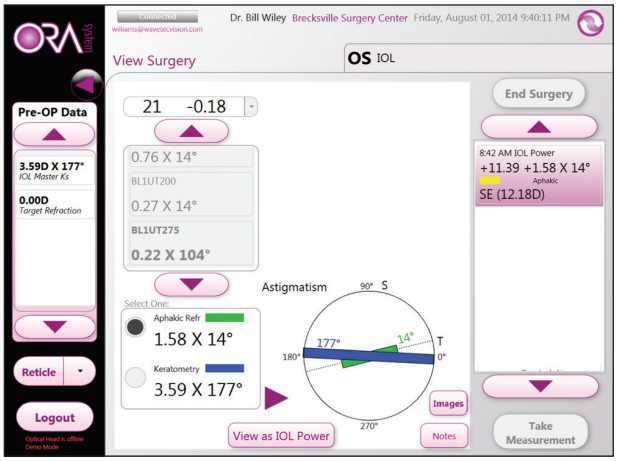

Figure 3. ORA aphakic screenshot for case No. 2.

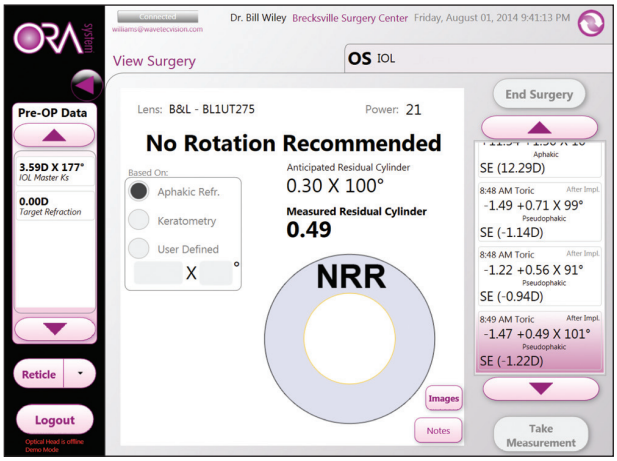

Figure 4. Pseudophakic ORA screenshot for case No. 2.

Postoperatively, the patient's manifest refraction is -0.25 D sphere, and she is very pleased with the outcome. I have had patients with residual or undiagnosed astigmatism who were very unhappy with their vision following multifocal IOL implantation. In my experience, patients' tolerance for small amounts of cylinder is much lower than that of patients who receive monofocal IOLs.

CASE No. 2. REFINING POWER SELECTION FOR A NEW IOL

A 66-year-old man with mixed astigmatism wanted to decrease his dependence on glasses after cataract surgery. Other than +2 nuclear sclerosis, the patient's ocular and health history was unremarkable.

After discussing the options, including toric IOLs with reading glasses or LASIK, it was clear the patient did not want to undergo multiple surgical procedures per eye, and he had high expectations for his postoperative UCVA. I chose to implant the Trulign Toric IOL (Bausch + Lomb), because this lens can correct astigmatism with added depth of focus compared to traditional IOLs. The patient agreed, and I proceeded with his left eye first.

The large database of more than 160,000 cases performed with the ORA System was very helpful to me for refining the choice of spherical power for an IOL platform that was less familiar to me. I knew that the intraoperative aberrometer would be the deciding factor for the power of the toric IOL, because the magnitude of astigmatism varied in my preoperative measurements (2.16 D on topography, 2.25 D in the manifest refraction, and 3.59 D with the IOLMaster). Aphakic intraoperative aberrometry showed 1.50 D of astigmatism (Figure 3), which guided my cylindrical Trulign power decision. After implantation of the Trulign 275, I took several more pseudophakic aberrometry measurements and, based on those, made some microadjustments to ensure that the IOL was positioned correctly to maximize the astigmatic correction (Figure 4).

I performed surgery on the patient's right eye a few weeks later. He has been very happy with 20/20 distance and J3 near vision.

CONCLUSION

Both of these cases—and many others that I perform every week—illustrate the power of advanced intraoperative aberrometry to help surgeons refine both the spherical and cylindrical correction and give patients who choose presbyopia-correcting IOLs the results they expect. ■

William F. Wiley, MD, is the medical director of the Cleveland Eye Clinic and an assistant clinical professor of ophthalmology at University Hospitals/Case Western Reserve University in Cleveland. He is a consultant to WaveTec Vision. Dr. Wiley may be reached at (440) 526-1974; drwiley@clevelandeyeclinic.com.