Glare After Damage to the Iris

Iris deficiencies can have a profoundly negative effect on a patient's quality of life.

BY MICHAEL E. SNYDER, MD

A 51-year-old woman referred to me from the Sunshine State had undergone cataract surgery in her left eye. Unfortunately during the procedure, the iris was damaged, leading to severe glare and profound functional disability. Her visual acuity measured 20/20-2 with a -1.00 +0.75 X 145 refraction. Her examination was notable for iris material that was absent from the 9-o'clock to the 1-o'clock meridians, and the iris tissue was frayed significantly at the margins. The AcrySof IQ Toric IOL (model SN6AT4; Alcon Laboratories, Inc., Fort Worth, TX) was well positioned within the capsular bag, and the posterior capsule was clear. The remainder of the ocular examination was not noteworthy.

This case demonstrates a classic divergence between a patient's symptoms and her Snellen measurements. Her complaints of glare resulted from multiple factors. First, the enlarged pupillary aperture let in more light than she found comfortable, resulting in photophobia. Second, the edge of the IOL was exposed to ambient light and caused this incidental light to be diffracted, inducing typical edge-related glare (Figure 1). Lastly, the light passing through the IOL focused on the retinal surface. The light entering from the aphakic space around the IOL's margin was defocused, however, which could degrade the focused image, reduce contrast sensitivity, and give images a washed-out appearance. These three factors are the common denominator in the photic symptoms experienced by similarly affected pseudophakic patients. How might their problems be best addressed?

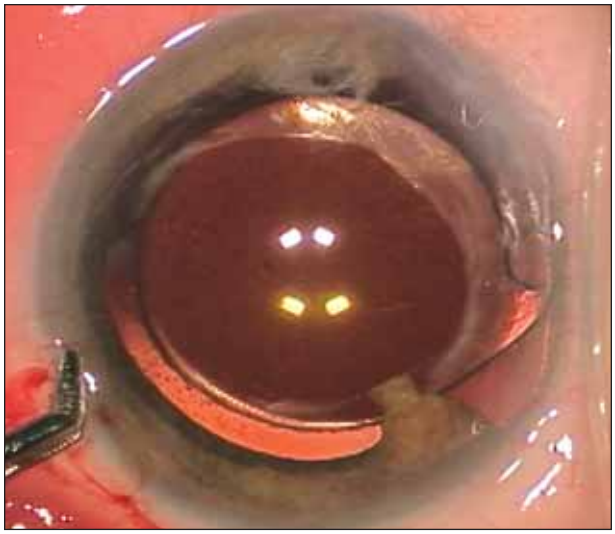

Figure 1. Appearance of the eye at the beginning of the case. Note the large sectoral iris defect and the IOL's exposed edge in this area.

OPTIONS

Assuming that the patient desires an improvement in his or her symptoms, a contact lens with peripheral opacity may provide a degree of symptomatic relief. Although this strategy reduces the amount of light entering the eye, patients may continue to experience glare from the edge of the IOL and reduced contrast sensitivity, because the contact lens' opacity is at the corneal plane. Light passing through the pupil from off-axis or tangential sources can still strike the IOL's edge or enter the aphakic space, diminishing only one of the three origins of the photic aberrations. Further, these contact lenses typically have lesser oxygen transmission and are relatively thicker than typical models, thus reducing patients' comfort and/or realistic wearing time.

In some instances, the native iris tissue can be stretched and sutured to create a new pupillary aperture. The success of such techniques is highly dependent on the relative amount, quality, and elasticity of the remaining iris tissue. In this case, too much iris tissue was absent to guarantee a successful repair using native tissue.

I offered the patient in this case an iris prosthesis. An

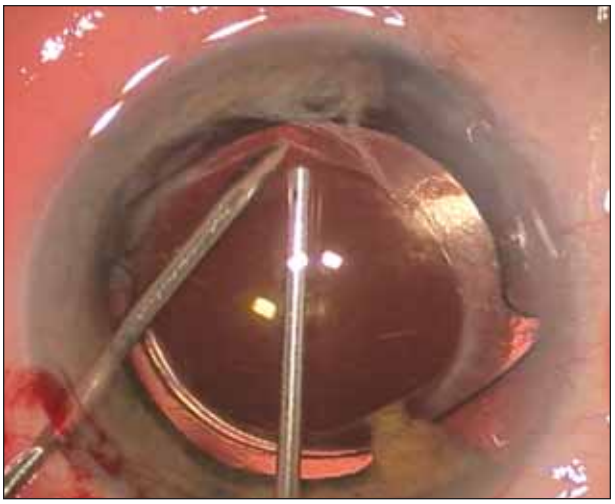

Figure 2. Dr. Snyder uses the back of a 25-gauge needle to lift the capsule off the IOL's surface so that he can insert an OVD cannula under the anterior capsular leaflet.

implant that covers the aphakic space and the edge of the lens optic within the IOL-iris plane could address all three components of her symptoms. Artificial irides currently marketed in the Western world include large-incision, rigid devices and some small-incision devices. They vary in their relative cosmesis. This lady selected a CustomFlex Artificial Iris (HumanOptics AG [Erlangen, Germany] and Dr Schmidt Intraocularlinsen GmbH [SanktAugustin, Germany]). Because there are currently no FDA-approved iris prostheses, I requested and received a compassionate use device exemption from the FDA. A photograph of the patient's residual iris was sent to the manufacturer, and a customized device was made.

SURGICAL COURSE

I prepared for the insertion by creating a corneal wound and, under the protection of a combined cohesive and dispersive ophthalmic viscosurgical device (OVD) (DisCoVisc; Alcon Laboratories, Inc.), then reopening the capsular bag with viscodissection. I facilitated the maneuver by lifting the edge of the capsulorhexis' margin off the IOL's surface using the blunt back edge of a 25-gauge needle's tip (Figure 2). I viscodissected open the anterior aspect of the bag, while taking care not to dissect the IOL from the posterior capsule so as to avoid rotation of the toric IOL and an unpredictable astigmatic outcome. Capsular staining with trypan blue dye improved visualization. The iris device was manually trephinated to 10 mm and injected into the capsular bag, in front of the PCIOL (Figure 3). I gently trimmed the frayed margins of the native iris with a 25-

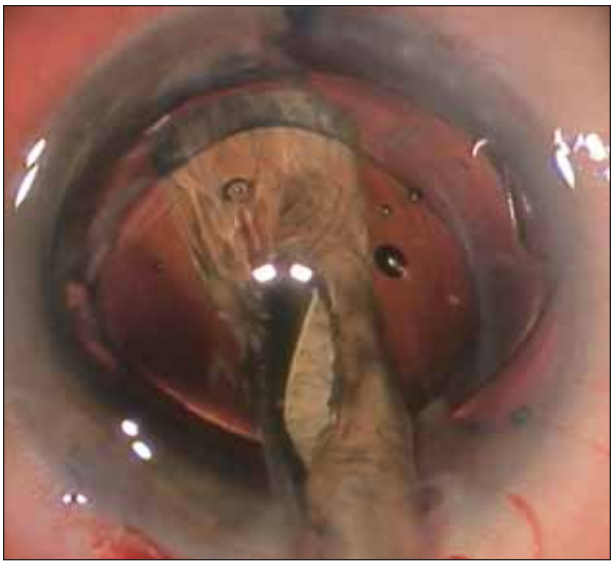

Figure 3. Staining of the anterior capsule with trypan blue aids visualization, as Dr. Snyder injects the CustomFlex iris device into the capsular bag.

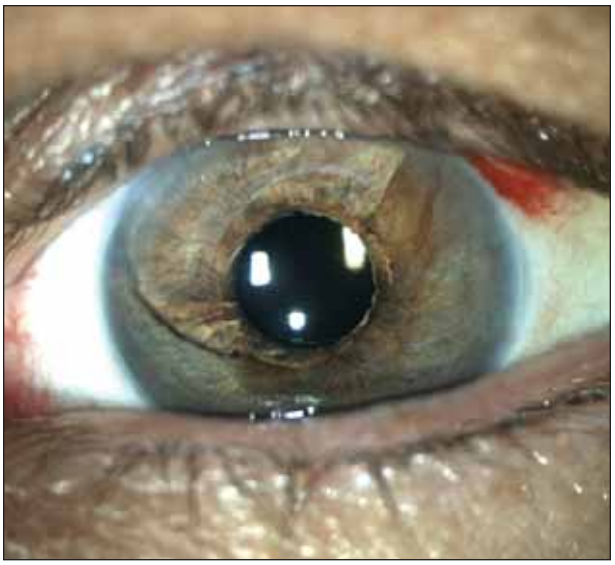

Figure 4. At the slit lamp 1 week postoperatively, the CustomFlex iris prosthesis within the capsular bag has created a round pseudopupil. The device provides an excellent cosmetic match to the patient's residual iris tissue.

gauge vitreous cutter through a paracentesis. Intraocular carbochol (Miostat; Alcon Laboratories, Inc.) was instilled to minimize the potential for a postoperative rise in IOP, since it would be reasonable to expect some of the OVD to remain in the interstices between the IOL and the CustomFlex iris device within the capsular bag complex.

OUTCOME

Postoperatively, the patient's troublesome symptoms vanished completely. She was thrilled with her final UCVA of 20/20+2 and lack of photic symptoms, which she reported as "just amazing." Her improved cosmesis was a happy byproduct of the procedure (Figure 4). The expected hyperopic shift occurred when the PCIOL was displaced posteriorly within the capsular bag complex due to the added volume of the iris device anteriorly within the bag.

TAKE-HOME TIPS

It is easy to lift the edge of a sealed capsulorhexis from the IOL's surface by bending the tip of a 25-gauge needle toward the bevel and using the curved back edge to lift off the capsule, thereby creating space for the OVD cannula to enter. This technique can be useful for any in-the-bag IOL exchange, regardless of the time that has elapsed since surgery—even many years.

Staining of the anterior capsule with vital dyes is crucial for visualizing the capsule once an iris device has been placed in the eye. The red reflex will be lost where the device is present.

I find it more reliable to leave a toric IOL on its given axis and adjust the residual astigmatism based on the manifest refraction with a limbal relaxing incision rather than to try to reorient the IOL to a new axis.

We surgeons must remember that 20/20 is not always "20/happy." We need to listen to each patient's complaints and try to understand what they can do to alleviate the problems. New tools can address a wide array of uncommon pathologies. I hope to have an FDA-approved option in the future.

Finally, cosmesis counts. Many patients with photic complaints from a functional or anatomic iris deficiency will readily describe their visual symptoms. They often will mention the effects on their self-esteem and body image postoperatively only if and when the problem is resolved. The impact on patients' quality of life should not be underestimated. ■

A video of this case is available at http://eyetube.net/?v=booni.

Michael E. Snyder, MD, is a voluntary assistant professor of ophthalmology at the University of Cincinnati, and he is in private practice at the Cincinnati Eye Institute. He is a consultant to and medical monitor for HumanOptics AG in the company's upcoming FDA IDE trial of the CustomFlex Artificial Iris. Dr. Snyder may be reached at (513) 984-5133; msnyder@cincinnatieye.com.