

Pars Plana Vitrectomy Approach for the Anterior Segment Surgeon

This technique offers significant advantages, and learning it is fairly straightforward.

BY LOUIS D. "SKIP" NICHAMIN, MD

Arguably, the single most significant complication faced by today's phaco surgeon continues to be rupture of the posterior capsule.¹ When the posterior capsule is breached, vitreous that presents anterior to the plane of the capsule must be removed. Fortunately, in the setting of small-incision surgery, if the ophthalmologist adheres to certain fundamental principles and employs proper instrumentation and surgical technique, the outcome in the vast majority of these complicated cases will differ little from that of an uncomplicated case.²

ADVANTAGES OF A PARS PLANA APPROACH

The key steps to managing a torn posterior capsule include quickly recognizing the problem, avoiding hypotony, and maintaining a truly closed-chamber environment. They are predicated upon the use of watertight incisions. As such, surgeons may use a much lower rate and volume of infusion, thereby reducing intraocular turbulence. To further enhance control of the intraocular environment and reduce vitreoretinal traction, a separated or *bimanual* vitrectomy should be utilized. In this way, the location and vector force of the infusion are displaced from the point where one is attempting to delicately remove vitreous. A reasonable approach is to place both instruments through limbal incisions (Figure 1).

I would submit that a much more efficient and potentially safer approach is to perform the vitrectomy through a pars plana incision (Figure 2). It allows the surgeon to "pull down" prolapsed vitreous from the anterior chamber, thus markedly reducing the amount of vitreous that is removed from the eye. When working from the limbus and bringing vitreous *upward*, it is much more difficult to find an end point, so one often unintentionally removes a considerable portion of the vitreous body and must then deal with a hypotonous eye.

Another significant advantage to working through a

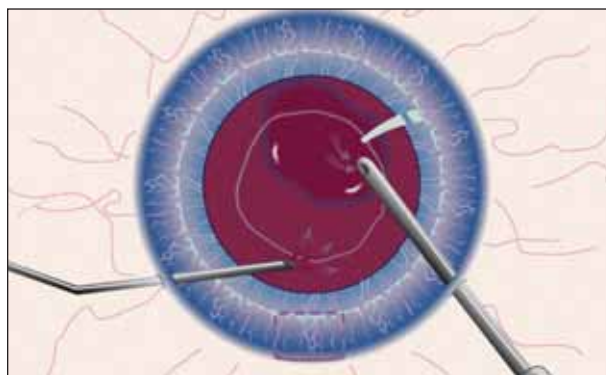


Figure 1. Bimanual vitrectomy performed through limbal incisions. (Reprinted with permission from Slack Incorporated. Nichamin LD. Posterior capsule rupture and vitreous loss: advanced approaches. In: Chang DF, ed. *Phaco Chop: Mastering Techniques, Optimizing Technology, and Avoiding Complications*. Thorofare, NJ: Slack Incorporated; 2004.)

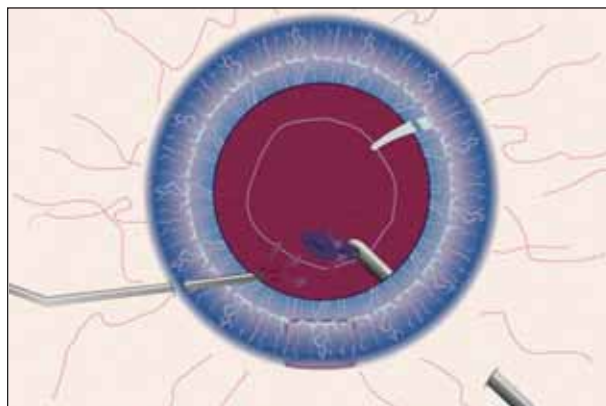


Figure 2. Bimanual vitrectomy with vitreous cutter placed through the pars plana. (Reprinted with permission from Slack Incorporated. Nichamin LD. Posterior capsule rupture and vitreous loss: advanced approaches. In: Chang DF, ed. *Phaco Chop: Mastering Techniques, Optimizing Technology, and Avoiding Complications*. Thorofare, NJ: Slack Incorporated; 2004.)



Figure 3. Nichamin A.C. Infusion Cannula No. E4421-S21. (Reprinted with permission from Slack Incorporated. Nichamin LD. Posterior capsule rupture and vitreous loss: advanced approaches. In: Chang DF, ed. *Phaco Chop: Mastering Techniques, Optimizing Technology, and Avoiding Complications*. Thorofare, NJ: Slack Incorporated; 2004.)

pars plana incision is the enhanced access one has to residual lenticular material. The surgeon may remove cortex, epinucleus, and even fairly dense nuclear material with the vitrector by gradually increasing vacuum and reducing the cutting rate. When addressing vitreous, the surgeon should use the highest cutting rate with the lowest possible vacuum that will permit vitreous aspiration. In this way, he or she can achieve a more complete cleanup and thereby reduce secondary complications such as increased IOP, inflammation, and cystoid macular edema.

LEARNING THE TECHNIQUE

It goes without saying that care and effort must be directed toward the learning and acquisition of any new surgical technique, but in reality, the pars plana approach is quite straightforward. Typically, one first takes down the conjunctiva and applies light cautery at the site of the intended sclerotomy, although some surgeons will incise directly through the conjunctiva. The cardinal meridians should be avoided due to increased vascularity. Given that the posterior capsule is open, infusion may be placed either through a limbal paracentesis incision or a second pars plana incision. A useful infusion cannula for this technique is available from Storz (Bausch + Lomb, Rochester, NY) (Figure 3). The surgeon should select the clock hour of the vitrectomy incision to best access remaining lenticular material.

The pars plana is anatomically located between 3 and 4 mm posterior to the limbus, so most commonly, the incision is placed 3.5 mm from the limbus, although an adjustment may be made for unusual axial lengths. Depending upon the surgeon's preference, wounds are created to accommodate either 19- or 20-gauge instruments. A dedicated disposable microvitreoretinal blade should be used to create properly sized and therefore watertight incisions for both pars plana and limbal inci-

sions. To make the pars plana incision, the blade is held perpendicular to the scleral surface and usually oriented in a limbus-parallel fashion. The blade is directed toward the center of the globe with a simple in-and-out motion.

As mentioned, when removing vitreous, the surgeon should use the highest possible cutting rate along with the lowest possible vacuum setting. He or she can titrate up the vacuum and reduce the cutting rate in order to remove remaining lenticular material. It is important to preserve as much of the capsule as possible, especially the anterior capsular rim in order to facilitate the lens implant's placement. Infusion should be minimal—just enough to maintain adequate IOP. The generous use of appropriate (often several different) viscoelastic agents will aid in maintaining volume, further decreasing the need for infusion. A dispersive agent works best to tamponade the hyaloid face, while a more cohesive viscoelastic maintains space.

The surgeon should carefully clean and close the pars plana incision. The choices for suture closure include 9-0 nylon or 8-0 Vicryl (Ethicon, Inc., Somerville, NJ). Recently, 25-gauge instrumentation has become available that, in some settings, may allow for sutureless surgery. Its insertion, however, requires a firm globe. These instruments can be used in a complicated setting if the surgeon first creates small incisions with a sharp blade as opposed to the usual trochar system. One downside is the instruments' lack of tensile rigidity and, therefore, the surgeon's reduced ability to manipulate the position of the globe.

CONCLUSION

Prudence dictates that surgeons not perform a pars plana vitrectomy for the first time while under duress during a live complication. I recommend carefully studying the technique and practicing it in a laboratory setting. I firmly believe that, by adhering to the surgical principles set forth in this article, anterior segment surgeons can achieve a salutary outcome despite the occurrence of one of the most troublesome complications of cataract surgery. ■

Louis D. "Skip" Nichamin, MD, is the medical director of Laurel Eye Clinic in Brookville, Pennsylvania. He is the medical monitor for Bausch + Lomb but acknowledged no financial interest in the instruments mentioned herein. Dr. Nichamin may be reached at (814) 849-8344; nichamin@laureleye.com.



1. Wu MC, Bhandari A. Managing broken capsule. *Curr Opin Ophthalmol*. 2008;19(1):36-40.
2. Nichamin LD. Posterior capsule rupture and vitreous loss: advanced approaches. In: Chang DF, ed. *Phaco Chop: Mastering Techniques, Optimizing Technology & Avoiding Complications*. Thorofare, NJ: Slack Incorporated; 2004:199-202.