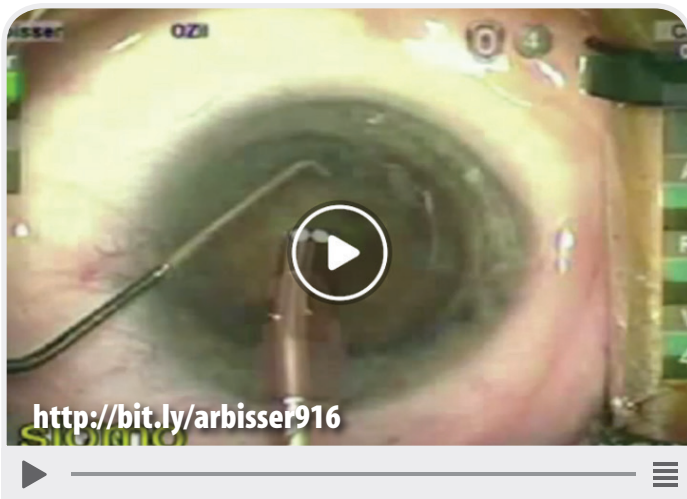




# THIS MONTH ON EYETUBE.NET



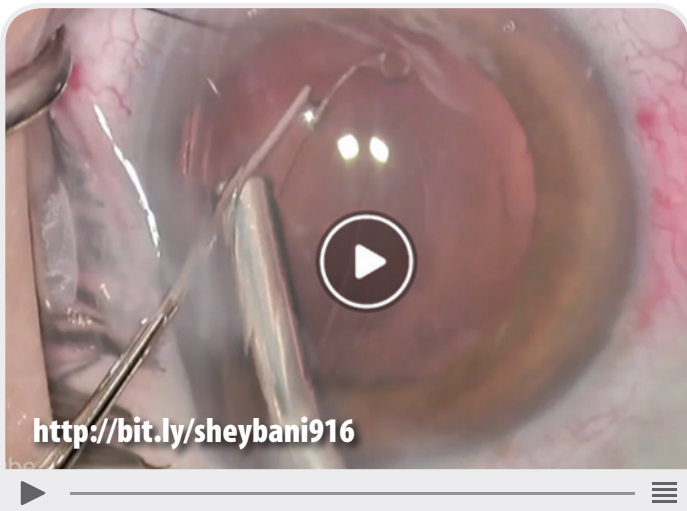
Pearls for Stable Chamber in Vitrectomized Eye

LISA ARBISSER, MD



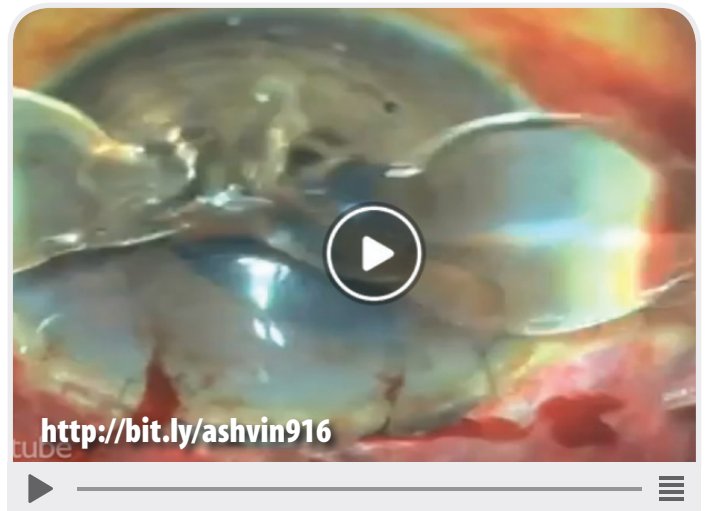An Anterior Chamber Angle-Fixated IOL Exchange for a Crystalens

STEVEN SIEPSE, MD



Using ReSure Sealant to Prevent Wound Leakage

ARSHAM SHEYBANI, MD



Conjoined IOL

ASHVIN AGARWAL, MD