

THE EFFECT OF LASIK ON DRY EYE DISEASE

Preoperatively, patients' tear film must be optimized for any refractive surgery to achieve a superior outcome.

BY CHRISTOPHER E. STARR, MD



The tear film is one of the eye's most important refracting surfaces. It is refreshed with each blink. If the tear film is not functioning properly and there are dry spots on the cornea, however, a patient may experience fluctuating, suboptimal, blurred vision. Preoperative dry eye disease (DED) can adversely affect outcomes after

any refractive surgery. High-quality postoperative vision requires the tear film to function normally.

The American Society of Cataract and Refractive Surgery clinical survey asked eye care professionals what percentage of their patients who underwent LASIK had significantly increased levels of DED, in 2013, the number was 36%.¹ In the past decade, there have been some exciting evolutions in the diagnosis and treatment of DED.

THE NEW ERA OF DED

My approach in the new era of DED management is to rely heavily on objective metrics via point-of-care diagnostic testing. These diagnostics include traditional tests like staining the ocular surface with lissamine green and fluorescein, measuring tear breakup time, and occasionally using Schirmer strips as well as newer, more sophisticated tests. These modern tests have greatly enhanced my ability to diagnose and grade the severity of DED and other forms of ocular surface disease. My technicians are trained to identify DED based on suggestive symptoms (validated questionnaires and verbal history), and when these are present, the staff performs the diagnostic tests before any drops or bright lights disrupt the patient's tear film. Occasionally, DED patients will have neurotrophic corneas and therefore may not have symptoms. For these patients, we rely on clinical signs to drive the diagnostic testing. When symptoms and/or signs are identified, the technician conducts a tear osmolarity test (TearLab) first, followed by the matrix metalloproteinase 9 (MMP-9) test (InflammaDry; Rapid Pathogen Screening). MMP-9 is an inflammatory marker that is elevated in patients with DED.²

“ Before newer tests became available, many patients were erroneously diagnosed with DED and told to use artificial tears as needed.”

These first-line tests have a high sensitivity, specificity, and positive predictive value for DED.^{2,3} They assess severity and help guide treatment. When test results are negative in otherwise symptomatic patients, we often find other diagnoses such as allergies, corneal basement membrane dystrophies, conjunctivochalasis, and so on that account for the symptoms. Before newer tests became available, many patients were erroneously diagnosed with DED and told to use artificial tears as needed for their symptoms.

If a patient has hyperosmolar tears (eg, a reading of > 308 mOsm/L or an intereye difference of at least 8 mOsm/L), then he or she, by definition, has DED.⁴ Because the osmolarity number is linearly related to disease severity, as the number increases, so does the severity of the dryness. If the patient also tests positive for MMP-9, then significant levels of ocular surface inflammation are present. In my practice, we then prescribe anti-inflammatory medications. Osmolarity and MMP-9 tests, in conjunction with our traditional metrics, are a good start for any modern practice. Other novel diagnostics such as lipid interferometry, tear film optical coherence tomography, confocal microscopy, noninvasive tear breakup time, lactoferrin, and blood biomarkers can also help to fine-tune diagnostic accuracy and guide treatment. With objective data, I know if DED is present before I walk into the examination room, which ultimately saves me significant chair time. If the patient will undergo refractive surgery (cataract or laser vision correction), then my goal

(Continued on page 44)

CORNEAL TRANSPLANTATION BEYOND BORDERS: A STORY ABOUT GELATINOUS DROP-LIKE CORNEAL DYSTROPHY

Two generations test positive for a new genetic mutation and undergo simultaneous corneal transplantation.

BY ENRIQUE O. GRAUE-HERNÁNDEZ, MD, MSc, AND JESUS CABRAL-MACIAS, MD



Gelatinous drop-like corneal dystrophy (GDLD) is predominantly found in people of Japanese descent. This autosomal recessive disorder typically manifests as a jelly-like form on the cornea, results in severely impaired

visual acuity (VA), and likely requires corneal transplantation. Most often, the disorder appears in the first decade of life and is bilateral.

We report on a consanguineous Mexican family affected in two generations by GDLD. We subsequently performed three simultaneous corneal transplants on the family at Instituto de Oftalmología “Conde de Valenciana” in Mexico City, courtesy of corneal tissue donation from the Foundation of the Lions Eye Institute for Transplant and Research (LEITR).

THE FAMILY

We heard about the first patient when she presented to us because she had undergone penetrating keratoplasty in her right eye that was now failing 2 years postoperatively. Adelina was 35 years old at the time and had a VA of light perception in both eyes. Her main complaints (aside from failing vision) were photophobia and foreign body sensation. We performed a differential diagnosis on her to exclude other corneal dystrophies, but we were confident based on her physical presentation—white-yellowish nodular opacities on the visual axis

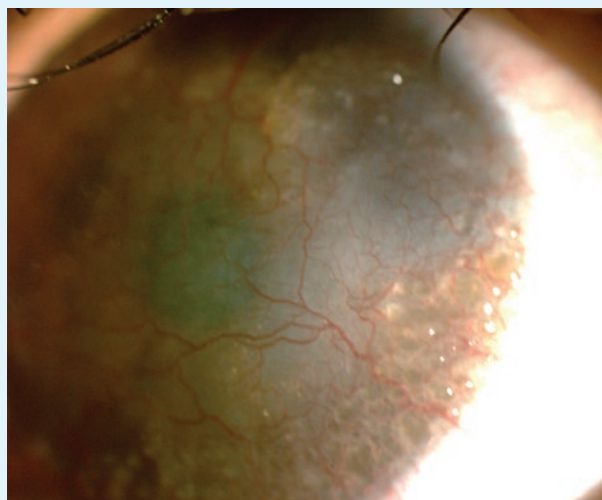


Figure 1. Preoperatively, the female sibling had obvious signs of GDLD, including the mulberry-like pattern opacities. (Note: all images are of the two siblings and not the first family members identified with GDLD.)

and anterior stromal neovascularization—that it was GDLD. Meanwhile, her left eye showed vascularization and stromal amyloid deposits with yellowish-white nodular lesions in a mulberry pattern and opacity involving the visual axis.

Once we confirmed our suspicions of corneal dystrophy, Adelina told us she had siblings and a son who suffered the same symptoms. This family lives in a remote region of the

GIVING THE GIFT OF SIGHT

Established in 2005, the Lions Eye Institute Foundation (Tampa, Florida) is grounded in the belief that everyone deserves the gift of sight. Of the \$1 million the Foundation donates yearly, more than \$52,000 this year alone has been used for tissue donations “to ensure that any person in need of sight-saving/sight-restoring surgery has access to care, regardless of their ability to pay,” said Angela Pottinger, foundation development coordinator. The Foundation also funds programs designed to improve quality of life for 45 million blind and visually impaired people of all ages throughout the world. For more information, visit www.lionseyeinstitute.org.

Oaxaca region in the Mexican mountains and do not speak Spanish (they speak an indigenous language). Adelina’s community is very poor, so we traveled to her village to determine if we could restore some sight and help improve their lives. We convinced her family to come to our facility (at our cost) to be tested and treated.

Adelina’s brother was 21 years old, presenting with poor vision, photophobia, and longstanding foreign body sensation. His VA was 20/200 OU. Adelina’s sister was 19 years old, with a VA of 20/100 OD and 5/200 OS. On slit-lamp examination, both siblings had the same clinical findings as Adelina. (Figure 1 is Adelina’s female sibling, and Figure 2 is Adelina’s male sibling.) Adelina’s son was 14 years old and had a VA of 20/30 OD and 20/40 OS. On slit-lamp examination, both eyes showed incipient yellowish-white lesions, but the visual axis was involved in the right eye only. We found a novel *TACSTD2* gene mutation after performing a genomic analysis for all affected family members in the genetics department at our facility.

THE LOGISTICS

After confirming the diagnosis, the logistics of coordinating transportation to our facility meant we wanted to

“Graft survival is usually reduced in GDL. However, our results to date are short term, but 3 months after surgery, all corneal grafts were transparent.”

perform simultaneous surgeries on the three family members who were eligible. Our facility serves the entire country as the main site for corneal repair, but it is located 10 hours from Adelina’s village.

We contacted LEITR to request donor corneas, as it is rare for us to have three available corneas at one time. LEITR also performs background screenings on all of its donor tissue via slit lamp (to confirm corneal health) and specular

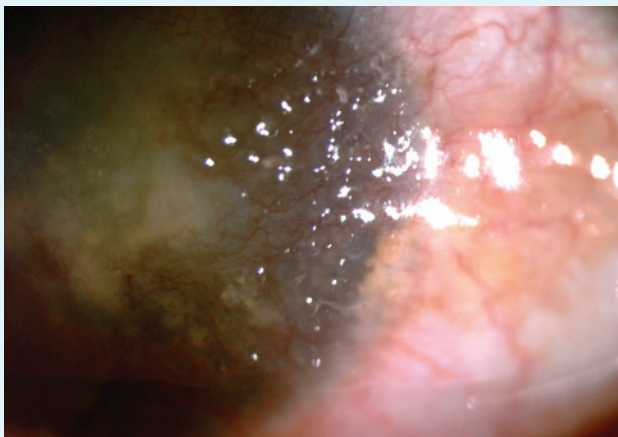


Figure 2. The male sibling also had obvious signs of GDL, including the yellowish nodular lesions.

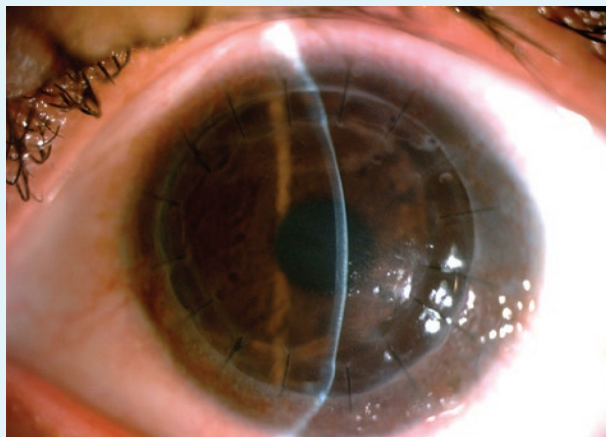


Figure 3. In postoperative month 3, the graft remains clear on the female sibling.

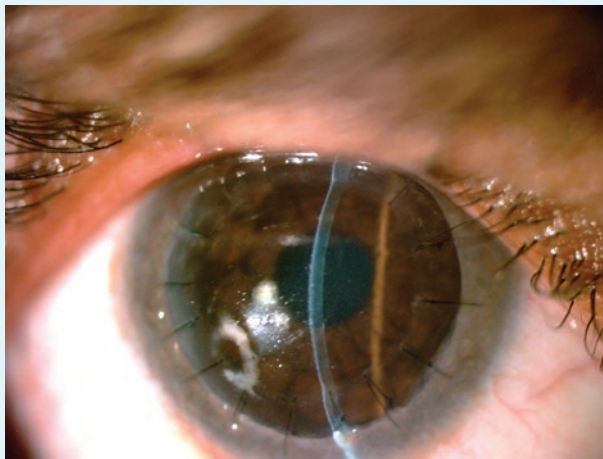


Figure 4. Postoperatively at the slit lamp, the male sibling's graft looks clear.

microscope (to ensure an adequate number of cells). For these surgeries, we needed three corneas to be roughly the same death-to-preservation time, and the corneas we had at our facility did not meet our criteria for this family.

SURGICAL OUTCOMES AND PLANNED FOLLOW-UP

Graft survival is usually reduced in GDL. Our results to date are short term, but 3 months after surgery, all corneal grafts were transparent. We are hoping to avoid graft failure by being somewhat vigilant and scheduling follow-up visits every few months.

So far, everyone in Adelina's family is doing well; they are able to contribute to their village again with housework and working in the fields. They are able to get on a bus to our facility on their own. The improvement in their quality of life has been outstanding (Figure 3 is Adelina's sister postoperatively, and Figure 4 is Adelina's brother after surgery.)

In short, LEITR's corneas and our surgical expertise resulted in a family's being able to participate fully in society again, be relatively autonomous again, and be a productive part of their community. ■

Enrique O. Graue-Hernández, MD, MSc

- chief of the Cornea & Refractive Surgery Department, Instituto de Oftalmología Conde de Valenciana, Universidad Nacional Autónoma de México, Mexico
- +521 554 369 1300; egraueh@gmail.com

Jesús Cabral-Macias, MD

- fellow of the Cornea and Refractive Surgery Department, Instituto de Oftalmología Conde de Valenciana, Universidad Nacional Autónoma de México, Mexico
- +521 554 369 1300; jcabralmacias@hotmail.com

(Continued from page 40)

is to normalize the tear film, ocular surface, and diagnostic testing results before proceeding.

Certainly, the effect that DED has on the quality of our preoperative measurements translates to patients' postoperative satisfaction. Preoperative DED, especially when corneal staining is present, will often lead to inaccurate preoperative measurements such as the refraction and keratometry, topography, and aberrometry readings. The effects of the surgical incisions on the cornea (the LASIK flap and limbal relaxing incisions in cataract surgery) can also worsen DED, which negatively affects patients' satisfaction. It thus behooves practitioners to identify dryness preoperatively, treat it aggressively, and reverse it prior to recording preoperative measurements for refractive surgeries. Physicians must also continue treatment during the postoperative phase with the assumption that most patients will experience even more dryness afterward.⁵

CONCLUSION

DED is widespread in patients seeking laser vision correction and other refractive surgeries. In my practice, it is a common reason patients become contact lens intolerant and seek alternate means of vision correction. As a result, refractive surgeons must have a high suspicion of DED in contact lens wearers. My rule of thumb is not to finalize preoperative measurements or perform surgery until the DED is treated fully. That means tear osmolarity measurements must be normal, the patient must test negative for MMP-9, the tear film must be completely stable in between blinks with a normal tear breakup time, and the corneal epithelium should be smooth. Refractive surgery is a largely elective surgery, so I take the time to treat DED fully before proceeding with final measurements and surgery. Aggressive treatment and close surveillance for worsening should continue throughout the postoperative period and beyond. ■

1. ASCRS Clinical Survey 2013. Eyeworld. <http://supplements.eyeworld.org/203235-ascrs-clinical-survey-2013>. Accessed June 26, 2015.

2. Sambursky R, Davitt WF 3rd, Latkany R, et al. Sensitivity and specificity of a point-of-care matrix metalloproteinase 9 immunoassay for diagnosing inflammation related to dry eye. *JAMA Ophthalmol*. 2013;131(1):24-28.

3. Versura P, Profazio V, Campos EC. Performance of tear osmolarity compared to previous diagnostic tests for dry eye diseases. *Curr Eye Res*. 2010;35(7):553-564.

4. The definition and classification of dry eye disease: report of the Definition and Classification Subcommittee of the International Dry Eye Workshop (2007). *Ocul Surf*. 2007; 5:75-92.

5. Li XM, Hu L, Hu J, Wang W. Investigation of dry eye disease and analysis of the pathogenic factors in patients after cataract surgery. *Cornea*. 2007;26(9 suppl 1):S16-20.

Christopher E. Starr, MD

- associate professor of ophthalmology at Weill Cornell Medical College in New York
- director of the Refractive Surgery Service, director of ophthalmic education, and director of the Cornea, Cataract, and Refractive Surgery Fellowship at Weill Cornell Medical College
- cestarr@med.cornell.edu
- financial disclosure: consultant to Allergan, Bausch + Lomb, TearLab, Rapid Pathogen Screening, and Shire