

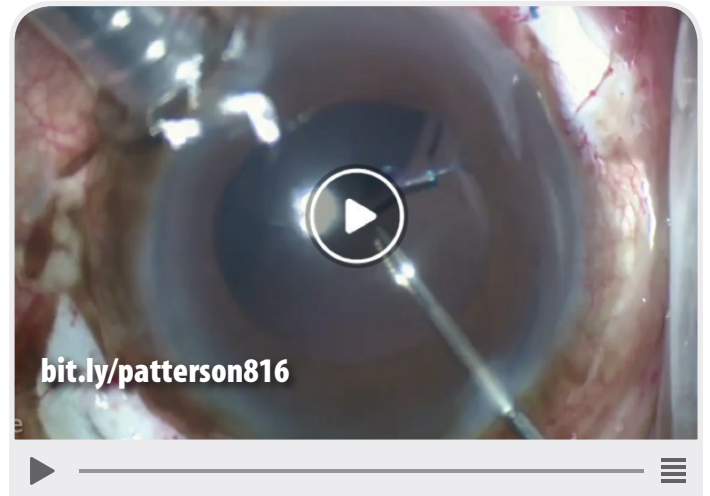


# THIS MONTH ON EYETUBE.NET



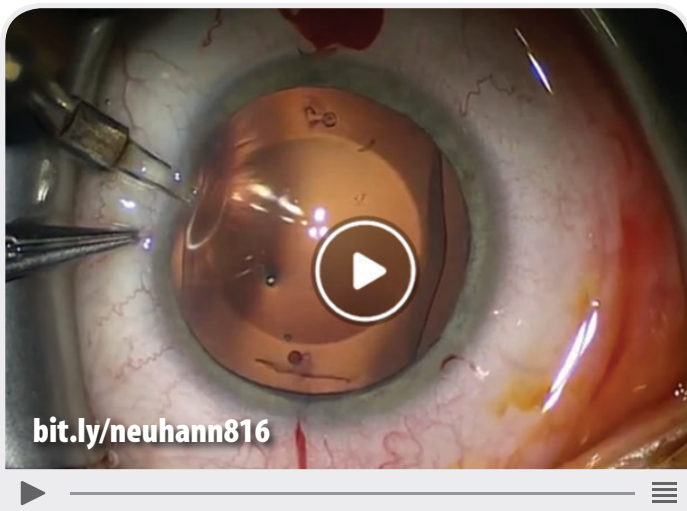
Implantation of a Combined Iris Prosthesis  
and IOL Through a 2.4-mm Incision

ULRICH SPANAU, MD, PhD



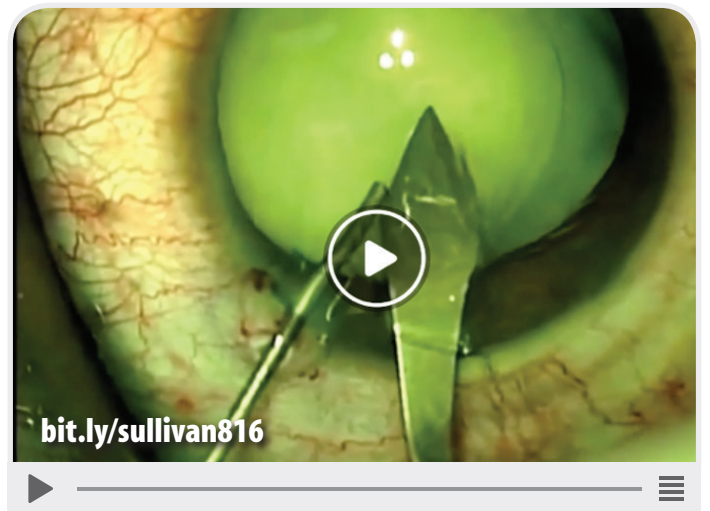
Repeat IOL Dislocation

MICHAEL PATTERSON, DO



ICL Removal and Replacement With a  
Toric EVO Visian ICL

TOBIAS H. NEUHANN, MD



Femtosecond Laser in White  
Cataract Case

LAURIE SULLIVAN, FRANZCO