

Retropupillary IOL for Aphakia: Surgical Technique

BY MARIA ALEJANDRA TORO MILLAN, MD; CARLOS MARIO PINILLA, MD;
AND ANDRES AMAYA ESPINOZA, MD

Many techniques have been described for correcting aphakia with inadequate capsular support. The most common IOLs that are used include anterior chamber, posterior chamber, iris-fixated, and scleral-sutured IOLs; however, there is no current agreement on the ideal technique or technology.

The Artisan aphakia lens (Ophtec; marketed as the Verisyse in the United States [Abbott Medical Optics]) was the first iris-fixated IOL. The Artisan IOL was introduced in the 1980s by Worst and colleagues and was designed for anterior chamber placement. Anterior chamber IOL implantation is considered a simple, effective, and safe technique with predictable visual results (Figure).¹⁻³

Scleral-sutured lenses have some inconveniences, such as difficult technique and prolonged operating time.² Several complications have been reported, such as lens decentring, retinal detachment, suprachoroidal hemorrhage, suture erosion, and rupture of the sutures with posterior dislocation.⁴⁻⁶

In this article, we describe a technique for the implantation of Artisan aphakic IOLs placed retropupillary, illustrating the safety and efficacy of this method of placement.

SURGICAL TECHNIQUE

A complete 23-gauge posterior vitrectomy is performed. Lateral paracenteses (nasal in right eyes and temporal in left eyes) are made, and viscoelastic is injected into the anterior chamber. Following the creation of a 5.5-mm scleral tunnel, the Artisan aphakia IOL is implanted. The IOL is introduced upside down in the anterior chamber and rotated to the desired position (which is usually horizontal, depending on the stromal iris condition).

Two 10-0 nylon sutures are placed in the corneoscleral wound to keep the anterior chamber steady during lens positioning. Subsequently, the IOL is placed in the posterior chamber through the pupil, using DO2-70/72/74 Artisan Implantation Forceps (Ophtec). Once the IOL is positioned as intended, the haptics are locked into the back of the iris stroma using a Drysdale spatula. Finally, a superior iridectomy is performed, and the incision is sutured with 10-0 nylon. This procedure is indicated for patients with

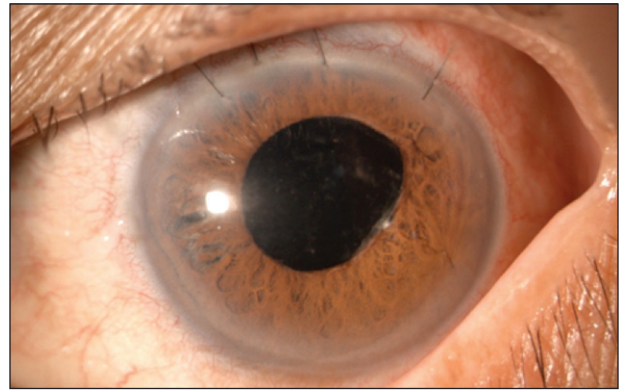


Figure. Patient 6 weeks after the implantation of the Artisan aphakia IOL.

adequate iris stroma that, although not necessarily intact, is composed of at least 180° of healthy tissue.

DISCUSSION

Posterior capsular rupture is a relatively rare complication, occurring in 0.9% of patients undergoing cataract surgery.⁷ Postsurgical aphakia and traumatic and nontraumatic dislocation of the IOL continue to be challenges for ophthalmologists when surgical correction is intended.^{8,9}

Different techniques and lens designs exist for the management of aphakia without capsular support. Anterior chamber IOLs, scleral-sutured lenses, posterior chamber iris-sutured IOLs, and anterior and posterior chamber iris-fixated IOLs are the most widely used.^{2,4,8,10}

Anterior chamber IOLs are technically simple to place, but they are associated with a considerable risk of trabecular damage, secondary glaucoma, and corneal decompensation.⁹ The currently used open-loop anterior chamber IOLs have lowered these complications, but a preoperative endothelial cell count and a measurement of anterior chamber depth are mandatory.¹⁰⁻¹²

In 2000, Zeh and Price described a technique for posterior chamber iris IOL suturing.⁸ This technique begins with a pars plana vitrectomy. A superior limbal 8-mm incision is then created at 12 o'clock, and a 9-0 poly-

propylene suture is passed from the iris at the 3-o'clock meridian, first toward the silicone IOL's optic and then toward the initial iris suture without adjusting the knot. These steps are repeated again at 180° from the starting point, after which the IOL is inserted through the limbal incision and the knots are adjusted, centering the IOL in the posterior chamber. The authors mention the risk of tangling the sutures and note that the sutures can be adjusted only when the lens is properly positioned.⁸ One of the main concerns is IOL dislocation. Rates have been reported to be between 0% and 10%, which is lower than reported for scleral-sutured IOLs (7.8%-27.9%).¹³

Dislocation of iris-fixated IOLs is most likely due to inadequate gripping of iris tissue, while scleral-sutured IOLs are most likely to dislocate due to suture rupture.^{8,12} Another concern is the technical difficulty of the procedure.

Different techniques have been described for scleral-sutured IOLs, but the insertion is generally performed with sutures passing from the outside to the inside of the eye, fixing the IOL to the ciliary sulcus at a determined distance from the limbus. Polypropylene 8-0, 9-0, or 10-0 double-armed sutures with straight or curved needles are commonly used, passed through eyelets located in the IOL haptics. Flaps or scleral tunnels are usually created to facilitate access to the ciliary sulcus, and conjunctival dissection can be performed.¹³ A 6-mm limbal incision is made to introduce the lens. Wagoner et al reported in a review in 2002 that more than 70% of patients implanted with scleral-sutured lenses achieved 20/40 or better visual acuity.¹¹ Nevertheless, this technique is more demanding and invasive, carrying the risk of complications such as retinal detachment, choroidal hemorrhage, suture erosion, endophthalmitis, and IOL dislocation.^{8,11,12}

The Artisan aphakia IOL was designed to be implanted in the anterior chamber, fixated at the iris midperiphery by hooks that theoretically do not alter the physiology of the iris and anterior chamber angle. The middle portion of the iris is characterized by almost no mobility, providing greater stability.¹⁰⁻¹² Moreover, the arched design of this lens separates the optic from the iris, thus decreasing the risk of pupillary block.^{12,14} In 2005, Güell et al described a technique for implanting the Artisan IOL in the anterior chamber of aphakic patients.¹⁵ The procedure's relative simplicity and reduced surgical time lend this technique some advantages. This technique, however, requires that patients have deep anterior chambers, adequate pupillary size, stable irises, and healthy endothelial cell counts.⁴

In 2011, De Silva et al reported on a series of 116 eyes of 104 patients,¹⁰ and in 2012, Gonnermann et al reported on 137 eyes of 126 patients in whom Artisan lenses were placed in the posterior chamber¹²; both reports offered pearls for improving technique and decreasing surgical

time. Complications included wound dehiscence, IOL decentration, iris tissue dehiscence, increased IOP, and cystoid macular edema. These complications were less frequent than or similar to those reported for anterior chamber or scleral-sutured lenses.

Using our technique, we have seen similar visual acuity results to those reported in the literature, with significantly less surgical time and postoperative astigmatism.

CONCLUSION

Aphakia without capsular support continues to be a challenge for ophthalmic surgeons. Iris-fixated retropupillary IOLs have emerged as an effective and safe alternative, achieving results comparable to conventional techniques of IOL placement. Long-term studies are needed to determine the role of posterior iris-fixated IOLs in the management of aphakia with inadequate capsular support. ■

This article is reprinted with permission from the March 2014 issue of Retina Today.

Andres Amaya Espinosa, MD, is chief of the Retina Department at Hospital Universitario La Samaritana, Universidad de la Sabana, in Bogotá, Colombia. He acknowledged no financial interest in the products or companies mentioned herein. Dr. Espinosa may be reached at andresamayaaae@hotmail.com.



Maria Alejandra Toro Millan, MD, is a third-year resident, and Carlos Mario Pinilla, MD, is a second-year resident in ophthalmology at Hospital Universitario de la Samaritana, Universidad de la Sabana.



1. Fechner PU, van der Heijde GL, Worst JG. IOL for myopia of the phakic eye. *Am J Ophthalmol*. 1989;107(6):659-663.
2. Baykara M, Özçetin H, Yilmaz S, Tirmuçu OB. Posterior iris fixation of the iris-claw intraocular lens implantation through a scleral tunnel incision. *Am J Ophthalmol*. 2007;144(4):586-591.
3. Chen Y, Liu Q, Xue C, Huang Z, Chen Y. Three-year follow-up of secondary anterior iris fixation of an aphakic intraocular lens to correct aphakia. *J Cataract Refract Surg*. 2012;38(9):1595-1601.
4. Moawad AI, Ghanem AA. One-haptic fixation of PCIOL without scleral flaps. *J Ophthalmol*. 2012;2012:891-893.
5. McAllister AS, Hirst LW. Visual outcomes and complications of scleral-fixated posterior chamber intraocular lenses. *J Cataract Refract Surg*. 2011;37(7):1263-1269.
6. Kjekæ O, Bohnstedt J, Meberg K, Seland JH. Implantation of scleral-fixated posterior chamber intraocular lenses in adults. *Acta Ophthalmol*. 2008;86(5):537-542.
7. Donaldson KE, Gorscak JJ, Budenz DL, Feuer WJ, Benz MS, Forster RK. Anterior chamber and sutured posterior chamber intraocular lenses in eyes with poor capsular support. *J Cataract Refract Surg*. 2005;31(5):903-909.
8. Zeh WG, Price FW Jr. Iris fixation of posterior chamber intraocular lenses. *J Cataract Refract Surg*. 2000;26(7):1028-1034.
9. Apple DJ, Brems RN, Park RB, et al. Anterior chamber lenses. Part I: Complications and pathology and a review of designs. *J Cataract Refract Surg*. 1987;13(2):157-174.
10. De Silva SR, Arun K, Anandan M, Glover N, Patel CK, Rosen P. Iris-claw intraocular lenses to correct aphakia in the absence of capsule support. *J Cataract Refract Surg*. 2011;37(9):1667-1672.
11. Wagoner MD, Cox TA, Ariyasu RG, et al. Intraocular lens implantation in the absence of capsular support: a report by the American Academy of Ophthalmology. *Ophthalmology*. 2003;110(4):840-859.
12. Gonnermann J, Klamann MK, Maier AK, et al. Visual outcome and complications after posterior iris-claw aphakic intraocular lens implantation. *J Cataract Refract Surg*. 2012;38(12):2139-2143.
13. Holt DG, Young J, Stagg B, Ambati BK. Anterior chamber intraocular lens, sutured posterior chamber intraocular lens, or glued intraocular lens: where do we stand? *Curr Opin Ophthalmol*. 2012;23(1):62-67.
14. Galvis V, Tello A, Miotto G, Rangel CM. Artisan aphakic lens for cataract surgery in anterior megalophthalmos. *Case Rep Ophthalmol*. 2012;3(3):428-433.
15. Güell JL, Velasco F, Malecaze F, Vázquez M, Gris O, Manero F. Secondary Artisan-Veytise aphakic lens implantation. *J Cataract Refract Surg*. 2005;31(12):2266-2271.