

Progressive Cataract, Elevated IOP, and Flat Anterior Chamber After PPV and Trabeculectomy

BY GARRY P. CONDON, MD; ALAN S. CRANDALL, MD; SUSAN M. MacDONALD, MD; CATHLEEN M. McCABE, MD; AND LISA BROTHERS ARBISSER, MD

CASE PRESENTATION

A 45-year-old woman with type 1 diabetes presented to a retinal specialist with a nonclearing vitreous hemorrhage in her phakic left eye. The patient underwent an uncomplicated pars plana vitrectomy (PPV), but her IOP was uncontrolled during the postoperative period despite maximum medication. The etiology of her elevated IOP was unclear, and ultimately, she was referred to a glaucoma specialist for trabeculectomy.

In the first postoperative week, the patient presented with a flat bleb and decreasing vision due to a progressive

cataract. The physician prescribed two glaucoma medications and promptly referred the patient to me. I saw her 1 day later.

The patient's visual acuity was hand motion with projection. She had a fixed, irregularly dilated pupil and a flat anterior chamber with flocculent white lens material centrally against the endothelium. Her IOP measured 30 mm Hg.

What do you think is the etiology of the presenting problem, and how would you care for this patient?

—Case prepared by Lisa Brothers Arbisser, MD.

GARRY P. CONDON, MD

This case is rather puzzling. In imagining the clinical appearance on the last presentation, I envision a large, rather opacified, swollen crystalline lens that is obliterating the anterior chamber, possibly associated with a release of white, flocculent lens material into the anterior chamber.

Based on the patient's visual acuity, I suspect there is no good view of the posterior segment, so the first order in management would be to obtain B-scan ultrasonography to determine whether or not there is any choroidal elevation posteriorly. I think this is unlikely with an IOP of 30 mm Hg. The fact that the glaucoma surgeon referred the patient to a cataract surgeon strongly suggests that the lens is the major problem. I suspect that lenticular trauma or rupture of the posterior lens capsule occurred during the original vitrectomy and caused the IOP to rise, followed by a progressive cataract, marked

“It would be critical to rule out any choroidal elevation. Assuming there is none, the treatment plan would be to remove the lens.”

—Garry P. Condon, MD

lenticular enlargement, and eventual “shallowing” of the anterior chamber. In addition, cortical lens material may be appearing in the anterior and posterior chambers. It would be critical to rule out any choroidal elevation. Assuming there is none, the treatment plan would be to remove the lens.

If the posterior segment anatomy is unremarkable, I would suggest a pars plana lensectomy with a long infusion cannula (eg, a 19-gauge needle) directed into the crystalline lens itself. This approach would preserve the anterior lens capsule, and once the lens material cleared, the anterior chamber would deepen dramatically and allow the placement of an IOL in the sulcus. An option would be to combine the efforts of an anterior segment and a posterior segment surgeon, with the former's placing the lens implant in the sulcus at the end of the procedure. Consideration could also be given to a primary anterior capsulotomy at that point to allow capture of the three-piece IOL's optic. Certainly, these procedures could be separated, with the lensectomy performed first, followed by a period of anti-inflammatory therapy and a secondary lens implant at a later date combined with additional glaucoma surgery as needed.

ALAN S. CRANDALL, MD

When attempting to analyze the mechanism of an elevation in IOP, it is tempting to make a single diagnosis, but that may not be accurate in this case. Pressure-related problems are unusual immediately after uncomplicated PPV unless there is preexisting glaucoma or pseudoexfoliation, for example. The confounding issue here, of course, is the diabetic retinopathy with vitreous hemorrhage. Preoperatively, the surgeon must look carefully for neovascular tissue on gonioscopy as well as for blood that may be blocking the trabecular meshwork. It is unclear from the history whether that assessment was done.

The patient could also have misdirection syndrome. It now appears, however, that she has a ruptured capsule (or, rarely, an intumescent cataract may leak) and a flat chamber. Ultrasound biomicroscopy or anterior segment optical coherence tomography might help to define the lens' position, whether or not the capsule is open, and whether or not the ciliary processes have rotated.

Cataract extraction is needed. If there is anterior rotation of the ciliary body, the surgeon could consider combining the procedure with endocyclophotocoagulation. Usually, the crystalline lens of a 45-year-old is soft, but that may not be the case in a diabetic patient after PPV. The surgeon must consider using low flow and no pressure to push back the lens. He or she may wish to combine the surgery with posterior segment surgery by the retina team.

SUSAN M. MacDONALD, MD

This complex case needs a multispecialty discussion to tease out the underlying diagnosis and to debate the treat-

“When attempting to analyze the mechanism of an elevation in IOP, it is tempting to make a single diagnosis, but that may not be accurate in this case.”

—Alan S. Crandall, MD

ment approach. I asked my colleagues Paul Cotran, MD, and Fina Barrouch, MD, to participate.

All of us wanted more information. Does this patient have an underlying systemic disease that might have contributed to her initial vitreous hemorrhage? We would suggest an evaluation for diabetes, hypertension, or sickle cell disease. Then, we would order a B-scan to gauge the status of the posterior segment in order to rule out choroidals and a retinal detachment.

Based on the history of the patient's present illness, we suspect that the crystalline lens was damaged during the vitrectomy. This would explain why the elevated IOP was unresponsive to maximal medical therapy. The inflammation was caused by leaching lens material and phacomorphic glaucoma from the swelling lens, leading to a shallow anterior chamber. A failed bleb is common in inflamed eyes. It is also possible that the chamber is so shallow and there is so much lens material in the anterior chamber that iris or lens material is physically blocking the sclerostomy.

The treatment is surgical. After peribulbar anesthesia, I would deepen the chamber with an ophthalmic viscosurgical device (OVD) to coat the endothelium and create a 2.2-mm clear corneal incision. The I/A could be used to gently clear the cortical debris from the anterior chamber. After staining the capsule with trypan blue, I would again deepen the chamber with a cohesive OVD to maintain space while decompressing the lens with a 25-gauge needle. I would pierce the anterior capsule, aspirate the cortical material, and then perform the capsulorhexis. Gentle hydrodelineation would allow manipulation of the lens and anticipation of a possibly damaged posterior capsule. Ultrasound could then be used to remove the lens, but I would expect to need very little phaco power for a 45-year-old nucleus.

If a capsular rent were identified, a posterior capsulorhexis would be helpful. The choice of IOL would depend on placement. My preference for sulcus fixation with optic capture is an AcrySof MA50BM lens (Alcon). I would then remove the OVD and suture the incision.

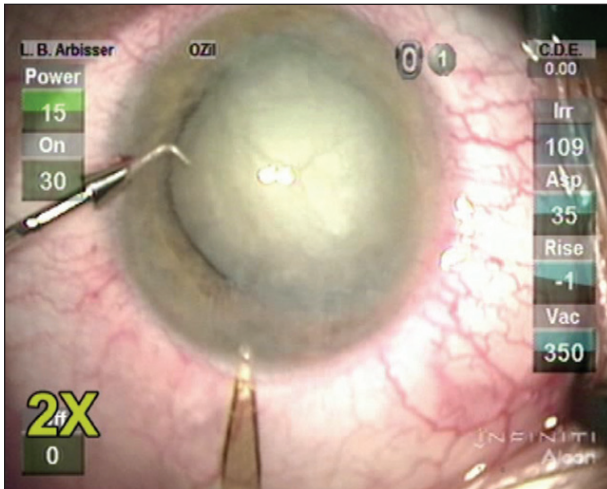


Figure 1. Small-incision entry for control of anterior chamber.

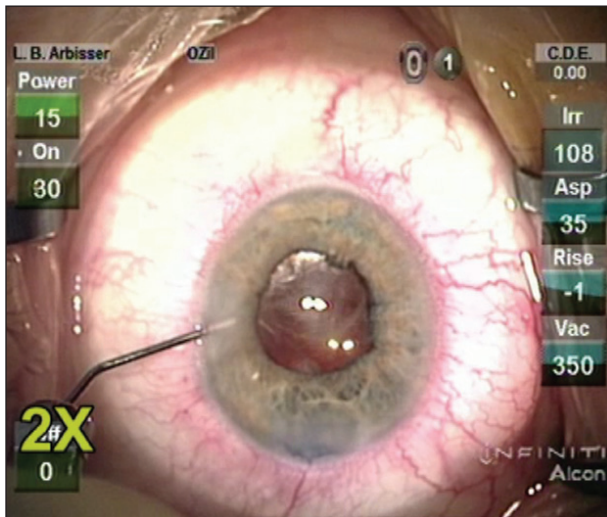


Figure 2. The IOL is implanted with an intracameral injection of triamcinolone acetonide to confirm an absence of vitreous and for the agent’s anti-inflammatory effect.

CATHLEEN M. McCABE, MD

This challenging case has several notable features: the flat anterior chamber, flat bleb, high IOP, and white lens material against the cornea, all after a PPV and trabeculectomy. The combination of a high IOP, flat bleb, and flat chamber is very suggestive of aqueous misdirection, although pupillary block and suprachoroidal hemorrhage must be ruled out. The lens material and rapidly progressive cataract suggest violation of the lens capsule and a phacolytic component. Although not normally considered in a vitrectomized eye, misdirection can happen in eyes that have undergone a phacic vitrectomy, because the crystalline lens’ presence can prevent complete removal of the anterior vitreous skirt.

The aqueous misdirection must be remedied, and the lens must be removed. In the short term, a combination of mydriatics, topical steroids, and glaucoma medications might help to break the misdirection, control the inflammation, and lower the IOP. Intravenous mannitol given at the time of surgery will help soften the eye, control the pressure, and deepen the anterior chamber. The lens could then be removed with care taken to preserve as much capsule as possible, followed by in-the-bag (if the capsular rupture is small and the edge fibrosed) or sulcus or suture fixation of a posterior chamber IOL. The surgeon would then remove the residual anterior vitreous and improve aqueous flow in the anterior/posterior chamber by creating a peripheral zonulohyaloidectomy and iridectomy with the vitrector. In addition to anti-biotic drops, oral aqueous suppressants and frequently dosed topical steroids could be administered to control the IOP and inflammation.

WHAT I DID: LISA BROTHERS ARBISSER, MD

Not knowing the state of the lens capsule, I counseled the patient on the possibility of postoperative aphakia with a secondary implant. I explained that she might require a sutured pupilloplasty and possibly a repeat trabeculectomy in the future.

I administered acetazolamide (Diamox; Duramed Pharmaceuticals) preoperatively and mannitol 1/4 g/kg intravenous push 15 minutes prior to surgery. I made a paracentesis, through which I formed the chamber with an OVD. I then sequentially aspirated lens material and added trypan blue dye to find the capsule. By not creating turbulence and never allowing the anterior chamber to shallow, I was able to prevent the ruptured anterior capsule from tearing around the equator while I cleared all lens material in a “dry” fashion (Figure 1).

The trick lay in finding the superior edge of the anterior lens capsule (as seen in the video). Intense staining of the pupillary edge led me to infer that the anterior capsule had fused with the iris pigment epithelium and scrolled up at the edge. I was able to restore the normal planes of tissue with blunt and sharp dissection. I made a demi-curvilinear capsulorhexis on the inferior side to clear the visual axis. I was then able to leave an envelope-like superior bag into which I could place a single-piece acrylic IOL with its haptics safely sequestered. Once the hidden posterior synechiae were released, the pupil came to a normal shape and acceptable size. I used intracameral triamcinolone acetonide (Triesence; Alcon) and prescribed a long, tapering course of a topical steroid and nonsteroidal



drug (Figure 2). The patient achieved a 20/20 result, and her IOP was controlled on one medication.

I suspect that the anterior capsule was inadvertently breached during the trabeculectomy in a shallow chamber due to rotation of the ciliary body. Rapid intumescence and, in effect, an Argentinian flag sign ensued in the day between the postoperative glaucoma check and her presentation to me. ■

Section Editor Lisa Brothers Arbisser, MD, holds an emeritus position at Eye Surgeons Associates, located in the Iowa and Illinois Quad Cities. She is also an adjunct associate professor at the John A. Moran Eye Center of the University of Utah in Salt Lake City. She has received honoraria from Abbott Medical Optics and Bausch + Lomb, and she is on the speakers' bureau of Alcon. Dr. Arbisser may be reached at (563) 343-8896; dralisa@arbisser.com.



Section Editor Tal Raviv, MD, is the founder and director of the Eye Center of New York and a clinical associate professor of ophthalmology at the New York Eye and Ear Infirmary of Mount Sinai.

Section Editor Audrey R. Talley Rostov, MD, is in private practice with Northwest Eye Surgeons in Seattle.

Garry P. Condon, MD, is chairman of the Department of Ophthalmology and director of the Glaucoma Division at Allegheny General Hospital in Pittsburgh. Dr. Condon may be reached at (412) 359-6298; garrycondon@gmail.com.



Alan S. Crandall, MD, is the John A. Moran presidential professor, the Val A. and Edith D. Green presidential endowed chair of ophthalmology and visual sciences, the director of glaucoma and cataract, and the codirector of the International Division for the John A. Moran Eye Center at the University of Utah in Salt Lake City. Dr. Crandall may be reached at (801) 585-3071; alan.crandall@hsc.utah.edu.



Susan M. MacDonald, MD, is an assistant clinical professor at Tufts School of Medicine in Boston and director of comprehensive ophthalmology at the Lahey Clinic in Burlington and Peabody, Massachusetts. She is a consultant to Alcon. Dr. MacDonald may be reached at (978) 538-4400; susan.m.macdonald@lahey.org.



Cathleen M. McCabe, MD, is a cataract and refractive specialist practicing at The Eye Associates in Bradenton and Sarasota, Florida. Dr. McCabe may be reached at (941) 792-2020; cmccabe13@hotmail.com.

