

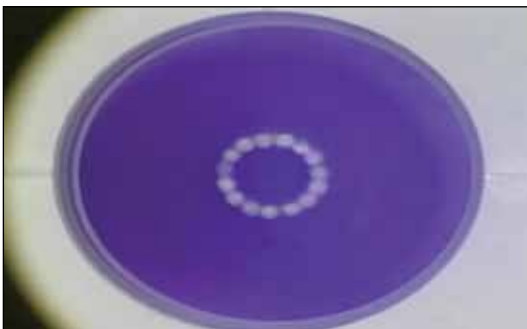
This Month's Videos on Eyetube.net



CATARACT REMOVAL IN AN EYE WITH A SMALL PUPIL AND AN AHMED GLAUCOMA VALVE

By A. John Kanellopoulos MD

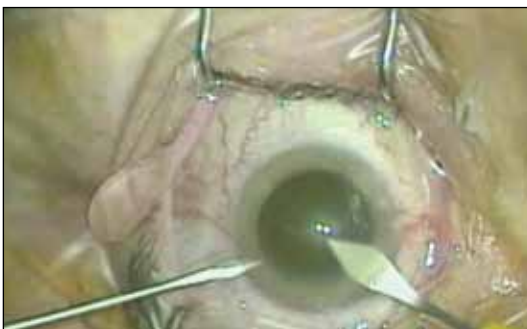A. John Kanellopoulos, MD, shares a challenging cataract case that involves a small pupil, synechiae on the anterior capsule, and a previously placed Ahmed Glaucoma Valve (New World Medical, Inc.).



REFRACTIVE SURGERY WITH THE 500-HZ WAVELIGHT EX500 EXCIMER LASER

By George O. Waring IV, MD

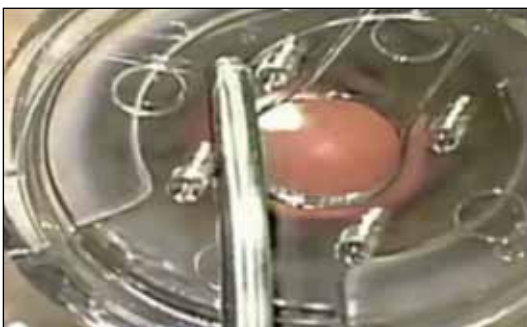George O. Waring IV, MD, performs the first US case with the 500-Hz Wavelight EX500 excimer laser (Alcon Laboratories, Inc.). The laser features advanced tracking capabilities and on-board pachymetry. According to Dr. Waring, the speed of the laser may yield less stromal dehydration and possibly faster recovery times for patients.



BIMANUAL SIMULTANEOUS CORNEAL INCISIONS PLUS CAPSULAR PUNCTURE

By Rogério Moreira, MD

Rogério Moreira, MD, presents a fast and safe technique to simultaneously construct corneal incisions and puncture the anterior capsule during phacoemulsification. Dr. Moreira's video shows his first 25 consecutive cases using this technique.



ENDOCAPSULAR SUPPORT DEVICE FOR LOCALIZED ZONULAR WEAKNESS

By Allon Barsam, MD; Rebecca Davie, MD; and Eric D. Donnenfeld, MD

The surgeons introduce a device designed for use in instances of zonular weakness to provide capsular support during complex cataract surgery. ■

