

A New Approach to the Rhino in the Room

Integrin peptide therapy offers the hope of a better treatment of two of the most significant and sight-threatening conditions in ophthalmology: AMD and DME.

BY BARUCH D. KUPPERMANN, MD, PhD

All of us in ophthalmology recognize the huge impact of diabetes and age-related macular degeneration (AMD) on our patients. In the United States alone, there are about 1 million patients with sight-threatening diabetic retinopathy, and that number is rising along with the incidence of diabetes.¹ The prevalence of AMD is also growing: by 2020, 3 million people will have advanced forms of AMD.² These diseases are among the leading causes of blindness in adults and significantly affect their ability to work, maintain their independence, and enjoy a high quality of life.

Unfortunately, we cannot yet offer nearly as good a “fix” for AMD or diabetic macular edema (DME) as we can for cataract formation. The current standard of care in AMD and DME, treatment with anti-vascular endothelial growth factor (anti-VEGF) agents, is remarkably effective, but it is not enough. Many patients plateau or fail to respond to anti-VEGF therapy, and for others, injections repeated every 4 to 8 weeks are too burdensome. Additionally, there is compelling evidence that inhibiting VEGF, which also has some neuroprotective qualities, may actually increase the risk of geographic atrophy.³

Clearly, this is an area ripe for further pharmaceutical development. A number of new compounds and unique drug delivery methods in the pipeline could improve our ability to treat patients with AMD and DME in the future. One of these is ALG-1001 (Allegro Ophthalmics).

INTEGRIN PEPTIDE THERAPY

ALG-1001 is the first in a new class of drugs called *integrin peptide therapy*. The agent targets multiple integrin receptor sites associated with neovascularization and endothelial

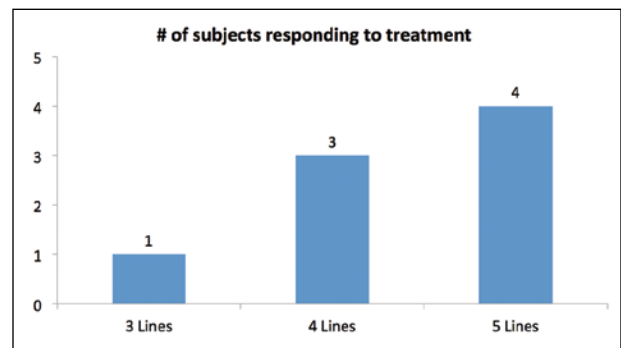


Figure 1. Eight of 15 subjects with chronic DME in a phase 1 safety study experienced an improvement in visual acuity of 3 to 5 lines after three monthly injections of ALG-1001. The gain was maintained for 3 months off treatment.

cell proliferation in wet AMD and diabetic retinopathy. Like anti-VEGF agents, ALG-1001 is administered by intravitreal injection. Because the drug attacks completely different portions of the angiogenic cascade, however, it has the potential to be an alternative or complement to current therapies.

EARLY DATA

Diabetic Macular Edema

The results of animal and early-stage human clinical studies of ALG-1001 have been very encouraging. There is no evidence of toxicity or safety concerns thus far. In phase 1/2 studies, ALG-1001 has demonstrated efficacy in a significant percentage of the limited number of patients in whom it has been tested. More intriguingly, a durable effect has been observed in patients who benefit from therapy. Improvements in vision and central

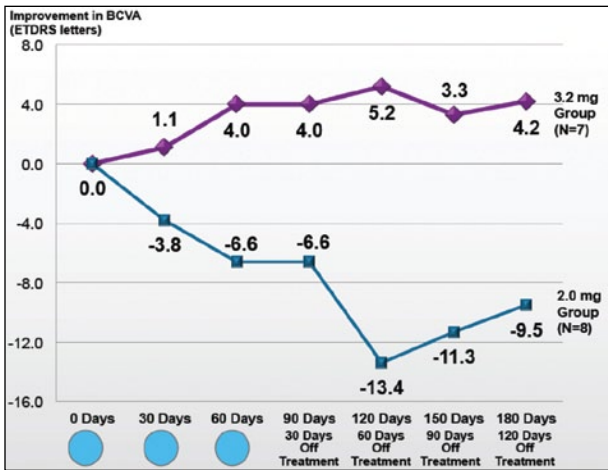


Figure 2. Subjects given the higher dose of ALG-1001 experienced a gain in BCVA that lasted for 4 months off treatment.

macular thickness (CMT) have lasted several months beyond the last injection of the drug.

In a phase 1 safety study involving 15 patients with chronic advanced DME, there was a mean improvement of 2 lines of vision, and more than half the subjects experienced a 3- to 5-line improvement (Figure 1), meaning they regained functional vision in the 20/40 to 20/60 range (data on file with Allegro Ophthalmics). Subjects in the study were enrolled after a 90-day washout period. They were then given a monthly 2-mg dose of ALG-1001 by intravitreal injection for 3 months, followed by 3 months of off-treatment follow-up. The improvements in visual acuity (and a corresponding reduction in CMT) lasted for 3 months off treatment. This was a monotherapy study with no anti-VEGF treatment.

It is also encouraging that, in the DME trial for ALG-1001, six of the 11 subjects with incomplete posterior vitreous detachment (PVD) at the start of the trial had developed total PVD by day 90—an endpoint in and of itself. That can be beneficial in changing the natural progression of the disease.

Wet AMD

A wet AMD study produced similar results. This phase 1b/2a monotherapy study was also designed primarily to evaluate the safety and optimal dosage of ALG-1001. After a 45-day washout period, 15 patients with wet AMD received three monthly injections of the drug (at doses of 2 or 3.2 mg, with an additional cohort of five patients enrolled at a dose of 5 mg, for whom no data are yet available). There were significant improvements in visual acuity (Figure 2) and CMT in the 3.2-mg dose group that held in most patients 4 months off treatment.

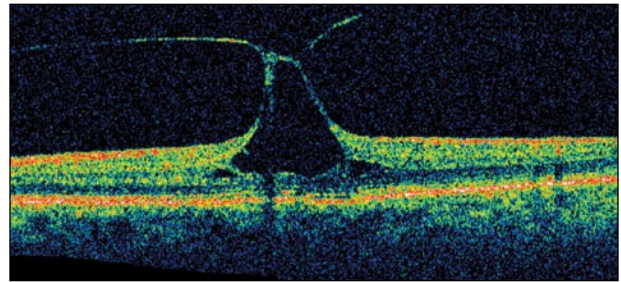


Figure 3. In eyes with VMT, the posterior vitreous adheres to the retina and exerts traction on the macula.

Discussion

Although these were limited studies with small numbers, the duration of effect was promising. The research also suggests another potential indication for ALG-1001: release of vitreomacular traction (VMT; Figure 3). VMT is less prevalent than AMD and DME but can be sight threatening and occurs when the posterior vitreous adheres to the retina and pulls on the macula.

Three additional phase 2 placebo-controlled studies are underway or have been cleared to begin. They will evaluate the efficacy of ALG-1001 for resolving VMT; as monotherapy treatment of wet AMD; and in combination with anti-VEGF agents for the treatment of DME. Larger enrollment in these studies is needed to confirm the drug's safety and efficacy, identify the ideal dosage and frequency of administration, and increase investigators' confidence in the durability of the therapy's effect in AMD and DME.

CONCLUSION

Ultimately, we all want to help patients maintain good vision throughout their lives. In the absence of a cure for AMD and DME—truly a distant goal—we can hope for treatments that work better, last longer, and help a greater percentage of patients than what is available today. The more weapons we have in our arsenal against these conditions, the closer we get to achieving that goal. ■

Baruch D. Kuppermann, MD, PhD, is a professor of ophthalmology and biomedical engineering, chief of the Retina Service, and vice-chair of clinical research in ophthalmology at the Gavin Herbert Eye Institute at the University of California-Irvine School of Medicine. He is a member of the Allegro Ophthalmics Scientific Advisory Board. Dr. Kuppermann may be reached at (949) 824-6256; bdkupper@uci.edu.



1. Kempen JH, O'Colmain BJ, Leske MC, et al for the Eye Diseases Prevalence Research Group. The prevalence of diabetic retinopathy among adults in the United States. *Arch Ophthalmol.* 2004;122(4):552-563.
 2. Friedman DS, O'Colmain BJ, Muñoz B, et al for the Eye Diseases Prevalence Research Group. Prevalence of age-related macular degeneration in the United States. *Arch Ophthalmol.* 2004;122:564-572.
 3. Grunwald JE, Daniel E, Huang J, et al for the CATT Research Group. Risk of geographic atrophy in the comparison of age-related macular degeneration treatments trials. *Ophthalmology.* 2014;121(1):150-161.