LASIK or a Phakic IOL?

BY CRAIG BEYER, DO; ALAN R. FAULKNER, MD; AND MARK KONTOS, MD

CASE PRESENTATION

A 35-year-old man wears soft contact lenses and is interested in vision correction surgery. He has a commercial airline pilot's license but currently flies only small, private planes. The patient denies dry eyes. He has no family history of keratoconus and does not take any oral medications. On examination, his eyes are healthy. He reports that he is medically healthy. He has manifest refractions of -7.50 +0.50 X 105 = 20/25 OD and -8.00 +0.50 X 88 = 20/20 OS (Figures 1-5).

The patient states that he has heard about both LASIK and phakic IOLs and is willing to undergo either procedure. How would you advise him?

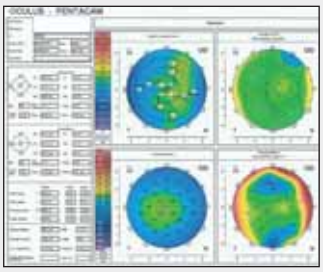

Figure 1. Image of the patient's right eye obtained with the Pentacam Comprehensive Eye Scanner (Oculus, Inc., Lynnwood, WA).

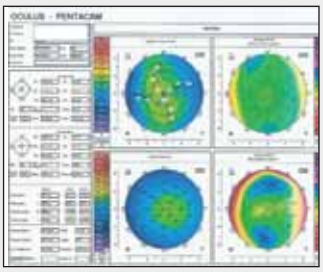

Figure 2. Image of the patient's left eye obtained with the Pentacam.

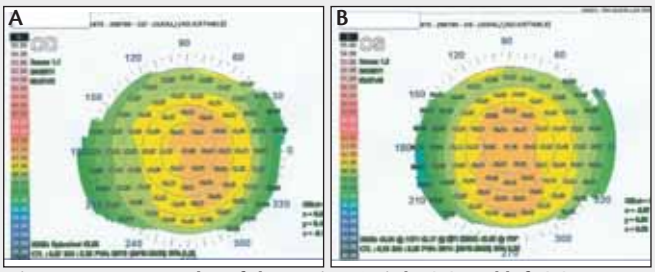

Figure 3. Topography of the patient's right (A) and left (B) eyes.



Figure 4. Wavefront measurements of the patient's right eye.



Figure 5. Wavefront measurements of the patient's left eye.

CRAIG BEYER, DO

This relatively young patient likely requires high-quality night vision while flying private planes. There does not appear to be a reason for the BSCVA in his right eye to be only 20/25, because all of the provided clinical and diagnostic data are normal and relatively symmetrical between both eyes. Also, the degree of anisometropia would not favor refractive amblyopia in his right eye. A repeat refraction of his right eye may be warranted. Probably of greatest concern are the relatively flat central keratometry (K) readings (< 42.50 D OU).

According to Arffa and colleagues,[1] the resulting dioptric change in the cornea is 11.14% less than the refractive dioptric power treated. Therefore, if the surgeon performed LASIK on this patient's right eye and treated a -7.25 D spherical equivalent, the final central K reading would be approximately 36.06 D. Similarly, treating -7.75 D OS would result in a final central K measurement of approximately 35.61 D OS. No doubt, this patient would experience increased glare and halos due to positively induced spherical aberration and moderately sized (6.5 mm) pupils, at least for the short-to-intermediate term.

My advice in this case would be to implant a Visian ICL (STAAR Surgical Company, Monrovia, CA) in both of the patient's eyes. Compared with LASIK, his recovery would be more immediate and more predictable. In addition, the phakic IOLs would induce less nighttime glare (especially in the near term) and would thus more likely meet the patient's expectations. Because of preliminary data recently presented by Stephen Klyce, PhD,[2] however, my advice is guarded. Dr. Klyce's analysis suggested that ICLs can cause a continuous decline in corneal endothelial cell counts equivalent to that reported for cataract extraction. If this finding proves to be true, then by recommending ICLs over LASIK, I would be no better than the typical US politician who sweetens the results for his or her constituents in the short term only to make them pay more dearly in the long term.

ALAN R. FAULKNER, MD

Upon cursory review, this patient appears to be a candidate for either LASIK or the implanta-

tion of a Visian ICL. There are, however, a number of subtleties that I feel are important to counseling him, obtaining informed consent, and choosing the treatment.

Certainly, the depth of stromal tissue is sufficient for LASIK. Nonetheless, I am concerned about the BCVA of 20/25 OD and the topography, which shows some keratometric irregularity as well as corresponding elevations of the anterior and posterior float nasally. The wavefront map is consistent with a corneal abnormality showing increased higher-order aberrations, specifically increased trefoil. With preoperative K readings of around 42.00 D, the postoperative K readings would be near 35.00 D. Anterior chamber depth is excellent for implantation of an ICL.

Due to the magnitude of the correction, the preexisting corneal abnormalities in the patient's right eye, and the resultant postoperative K readings, I would recommend bilateral Visian ICLs. Published data have shown that these lenses perform as well if not better than LASIK for the treatment of high myopia. I have implanted the ICL in a similar patient and achieved an excellent outcome.

I would caution the patient, however, that his right eye might not achieve the same visual acuity or quality of vision as his left eye. If the higher-order aberrations had visual significance after implantation of the ICL, a wavefront-guided enhancement might be an option, as would topography-guided treatment when it becomes available. I feel that ICL surgery would also leave the patient with more options for future treatment than LASIK, because the implant is removable and the cornea is not flattened to a degree that many consider near the limit of acceptability.

MARK KONTOS, MD

Counseling patients who are considering refractive surgery and have visually demanding jobs or hobbies such as flying can be complex. A postoperative complication in this setting could result in a permanent loss of flight status. This individual currently holds a commercial license but is not flying professionally. To maintain a commercial license, one needs a class 3 medical certificate, which requires the person's vision to be correctable to 20/20 in each eye. The patient's current visual acuity is 20/25 OD. I would want to know whether he had 20/20 visual acuity when he received his commercial license, whether he received a wavier for his vision, or if this measurement is a new finding. The reason for and permanence of this acuity would need to be explored prior to any surgical plan, and it would be necessary to ascertain whether this patient plans to fly professionally again.

The remainder of the patient's examination shows a healthy individual with moderately high myopia and minimal astigmatism. The corneal evaluation demonstrates normal thickness bilaterally, slight asymmetry of the anterior surface in his right eye, and a fairly symmetrical astigmatic posterior surface in both eyes. Wavefront examinations show significant trefoil in his right eye with a significantly higher root mean square value. This finding may account for the reduced visual acuity in his right eye.

The choice of surgical intervention depends largely on whether this patient plans to return to commercial aviation. If so, I would recommend implantation of the Visian ICL because of its potential reversibility if nighttime glare or other problems occurred. A wavefront-guided treatment could be preformed secondarily to his right eye if it did not achieve 20/20 BCVA. Contrarily, if maintaining his flight status is not paramount, I expect wavefront-guided LASIK will achieve a good outcome with minimal risk. It goes without saying that this patient needs to have a clear understanding of the risks of refractive surgery before making any decisions. ■

Stephen Coleman, MD, would like to thank William Trattler, MD, for supplying this case.

Section Editor Stephen Coleman, MD, is the director of Coleman Vision in Albuquerque, New Mexico. Parag A. Majmudar, MD, is an associate professor, Cornea Service, Rush University Medical Center, Chicago Cornea Consultants, Ltd. Karl G. Stonecipher, MD, is the director of refractive surgery at TLC in Greensboro, North Carolina. Dr. Coleman may be reached at (505) 821-8880; stephen@colemanvision.com.

Craig Beyer, DO, is the medical director of Beyer Laser Center, and he is in private practice with BoulderEyes, both in Boulder, Colorado. He acknowledged no financial interest in the product or company he mentioned. Dr. Beyer may be reached at cbeyer@bouldereyes.com.

Alan R. Faulkner, MD, is the founder of and is in private practice with Aloha Laser Vision in Honolulu, Hawaii. He is a paid member of the Refractive Clinical Advisory Board of Alcon Laboratories, Inc., but stated that he holds no financial interest in the products or other companies he mentioned. Dr. Faulkner may be reached at (808) 792-3937; dralan@alohalaser.com.

Mark Kontos, MD, is a partner of Empire Eye Physicians, PS, of Washington and Idaho. He acknowledged no financial interest in the product or company he mentioned. Dr. Kontos may be reached at (509) 928-8040; mark.kontos@empireeye.com.

1. Arffa RC, Klyce SD, Busin M. Keratometry in epikeratophakia. *J Refract Surg*. 1986;2:61-64.
2. Klyce SD. Challenges to corneal inlays. Presented at: The Aspen Invitational Refractive Symposium; February 28, 2011; Aspen, CO.