

Centering IOLs Using Purkinje Images

The information from these often-ignored reflections can help solve a fundamental challenge of the IOL's implantation. This article is the first in a three-part series.

BY DANIEL H. CHANG, MD

For years, centering IOLs has largely been an afterthought during cataract surgery. Insert the IOL, let the haptics unfold, and watch the optic settle into place. As long as the edge of the optic remained out of the undilated pupil, surgeons considered the IOL to be well centered. Ophthalmologists' attention to the IOL's centration increased with the advent of aspheric designs, which require decentration of less than 0.4 mm to perform well.^{1,2} Although most studies find mean decentration to be less than 0.4 mm, outliers are often misaligned by up to 1 mm.³⁻⁶ Nevertheless, without a simple and reliable way to determine the accuracy of the IOL's centration, the problem remained largely unaddressed. Now, with the introduction of diffractive multifocal IOLs, the issue of centration has taken on greater importance. With these presbyopia-correcting implants, even submillimeter "decentrations" can readily be seen on routine slit-lamp examinations. More than just a cosmetic problem, a decentered IOL can significantly reduce quality of vision, increase night vision symptoms, and

reduce patients' satisfaction.

Unfortunately, there has not been a consistent way to line up an IOL with the center of the patient's undilated pupil (as seen in the clinic and in the patient's daily life) while working through a dilated pupil (as seen during surgery). Not only is it difficult to find the optical center of a dilated pupil, but pupils can also shift by up to 0.6 mm with pharmacologic dilation.⁷ Suggested solutions to this problem have included marking the cornea prior to pupillary dilation or the use of intraoperative miotics. Postoperative iridoplasty to adjust the pupil has also been advocated. Issues of surgical workflow, parallax, pupil centroid shifting with miotics, cost, and the need to explain and to perform another procedure are potential drawbacks to these approaches. A new method involving Purkinje images offers a powerful alternative.

PERFECT MARKERS FOR CENTRATION

I have been using Purkinje images as real-time markers of the eye's and IOL's positions. Purkinje images were

TABLE 1. BASIC CHARACTERISTICS OF PURKINJE IMAGES^a

	PI	PII	PIII	PIV
Source	Cornea, anterior surface	Cornea, posterior surface	Lens/IOL, anterior surface	Lens/IOL, posterior surface
Seen clinically	Yes	No	Yes	Yes
Location	Anterior lens/IOL	—	Anterior vitreous	Corneal surface
Size	Smallest	—	Largest	Medium
Brightness	Bright	—	Dim to very bright	Medium
Orientation	Upright	—	Upright	Inverted
Movement	Slow	—	Rapid	Medium

^aPurkinje images are numbered in order of their originating surface, not their apparent location. The relative size and brightness depend on the optical properties of individual IOLs and can vary widely across the range of commonly used IOLs. In particular, PIII can be very bright in low-powered IOLs with flat anterior curvatures.

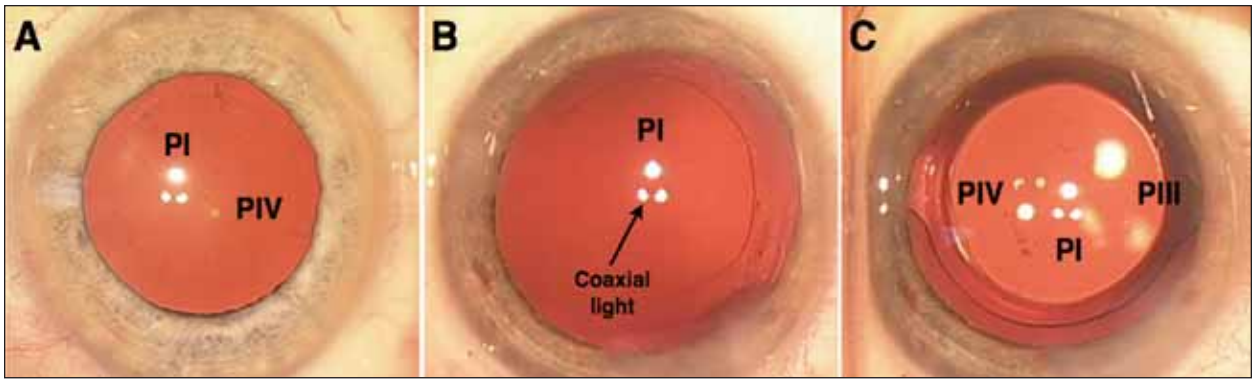


Figure 1. Purkinje images in a phakic (A), aphakic (B), and pseudophakic (C) eye. The bottom left light (of PI) is coaxial to the camera taking these photographs.

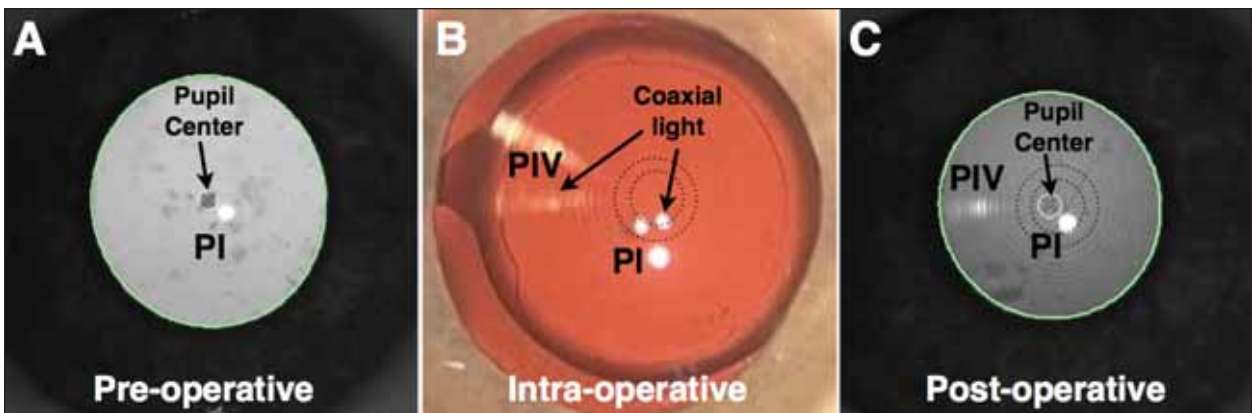


Figure 2. This preoperative image of the pupil demonstrates the location of PI relative to the center of the scotopic pupil, marked by an “x” (A). The same eye intraoperatively (rotated 180° to match the orientation of the pre- and postoperative images of the pupil) after implantation of a one-piece Tecnis Multifocal IOL (Abbott Medical Optics Inc., Santa Ana, CA). The patient was asked to fixate on the upper-right (coaxial) light (B). A postoperative image of the pupil shows good IOL centration (C). Note that the pupillary center is consistently superotemporal (in this right eye) to PI from before to after surgery. Note also that the IOL’s center is consistently superotemporal to PI from during to after surgery.

named after the early 19th century Czech physiologist who first identified them. When light passes through an interface (eg, air-cornea or aqueous-IOL), some of that light is transmitted, and some is reflected. Purkinje images result from light’s reflecting off the ocular interface. The detailed analysis of Purkinje images with customized instrumentation can provide high-resolution information about the optical state of the eye and the IOL, including decentration and tilt.^{5,6,8,9} It is possible to make practical and effective use of these images with nothing more than the diagnostic instruments routinely used in clinical practice.

There are four Purkinje images, numbered PI to PIV, according to the interface from which they originate. Only three (PI, PIII, and PIV) are seen clinically (Table 1). The numbering does not correlate to the image’s observed Z-axis location. Figure 1 shows the appearance of the Purkinje

images with the Opmi Lumera surgical microscope (Carl Zeiss Meditec, Inc., Dublin, CA). Because the Lumera projects three separate lights, each Purkinje image is actually a cluster of three lights. This pattern helps to demonstrate the orientation of the reflections but is not necessary for the identification of the Purkinje images. Table 1 outlines relative characteristics of the four Purkinje images. Each parameter (location, size, and brightness) depends on a variety of factors, including the IOL’s power, material, steps, and chromophores. A few basic concepts can help a surgeon derive significant information about an IOL simply from its Purkinje images.

The X and Y locations of the Purkinje images depend on the relative positions of the light source and the observer to the eye. As the eye and the IOL move, the Purkinje images move in complex yet precisely defined patterns. To serve as markers of an IOL’s centration, the Purkinje images must be

“The primary Purkinje marker for assessing centration is PI. It stays near the center of the eye and moves minimally with the eye; it also floats in the IOL plane, which is important, because it prevents issues of parallax.”

viewed in a reproducible fashion pre- and intraoperatively. The patient’s fixation on a light source coaxial to the viewer creates this reproducible alignment.

The primary Purkinje marker for assessing centration is PI. It stays near the center of the eye and moves minimally with the eye; it also floats in the IOL plane, which is important, because it prevents issues of parallax. PIII and PIV can be used to confirm the patient’s fixation, which is important for accurate positioning of PI.

THE METHOD IN DETAIL

Preoperatively, I perform corneal topography on every eye that will receive a presbyopia-correcting IOL. From the corneal topographer, I print out an image of the pupil that shows the location of PI relative to the center of the undilated pupil (Figure 2A). This image is created by an illumination/fixation light source that is coaxial to the camera. I use an Atlas 9000 topographer (Carl Zeiss Meditec, Inc.), which captures both scotopic and photopic pupillary images. If a particular topographer does not have a special pupil-image report, a “rings image” or “eye image” map on any topographer will demonstrate the location of a coaxial PI relative to the center of the pupil. Because the ring images from the Placido disks are first Purkinje reflections, the PI that will be needed for centration is the geometric center of the ring reflections. Incidentally, a topographer can focus on a corneal image (the rings) and the iris simultaneously, because the rings’ images (first Purkinje reflections) lie in the lens-iris plane.

With the Lumera operating microscope with Stereo Coaxial Illumination, each Purkinje image consists of three light reflections (Figure 1). Other microscopes may have one or two lights. In my PI triangle of reflections, the larger top light is the main illumination light, and the two smaller bottom lights are coaxial to my two oculars. Because the camera is attached to the left ocular, the bottom left light (in PI and PIII, top right in PIV) is the coaxial reflection (Figure 1B).

When the patient fixates on the coaxial light source intraoperatively, I am reproducing the position of PI as seen in my preoperative coaxial image of the undilated pupil.

Because I know the location of the center of the undilated pupil relative to the location of PI, I can move the center of the IOL to that same position intraoperatively (Figure 2B).

I can confirm the patient’s fixation with the X and Y locations of PIII and PIV and my knowledge of angle kappa. The temporal location of PIV (to the left in the rotated Figure 2B) confirms good fixation by the patient.

As part of the postoperative examination, I can verify that the IOL is well centered at the slit lamp by looking at the diffractive rings and the pupil. However, since the slit lamp is subject to the patient’s fixation and parallax, I can repeat a pupillary image with my topographer for a more precise assessment (Figure 2C).

CONCLUSION

Purkinje images provide a tremendous amount of continuous feedback that surgeons have been largely ignoring. By using this information, Purkinje images can become ideal markers for improving an IOL’s centration. The technique described herein can also help to eliminate the decentrations of greater than 0.6 or 0.7 mm that can cause negative visual symptoms in patients.

Many questions remain. Should an IOL be centered on the scotopic, mesopic, or photopic pupil? Should an IOL be centered on the pupil at all? What about the visual axis or line of sight? Purkinje images can help to answer these questions, because they can provide an accurate method for locating these various positions intraoperatively. By paying closer attention to these ubiquitous reflections, surgeons may not only be able to improve the precision with which they center an IOL, but they may also be able to improve the quality of life of more of their patients. ■

Daniel H. Chang, MD, is a partner at Empire Eye and Laser Center in Bakersfield, California. He is a consultant to Abbott Medical Optics Inc. Dr. Chang may be reached at (661) 325-3937; dchang@empireeyelandlaser.com.



- Holladay JT, Piers PA, Koranyi G, et al. A new intraocular lens design to reduce spherical aberration of pseudophakic eyes. *J Refract Surg*. 2002;18(6):683-691.
- Wang L, Koch DD. Effect of decentration of wavefront-corrected intraocular lenses on the higher-order aberrations of the eye. *Arch Ophthalmol*. 2005;123:1226-1230.
- Ram J, Apple DJ, Peng Q, et al. Update on fixation of rigid and foldable posterior chamber intraocular lenses. Part I: elimination of fixation-induced decentration to achieve precise optical correction and visual rehabilitation. *Ophthalmology*. 1999;106:883-890.
- Mutlu FM, Erdurman C, Sobaci G, Bayraktar MZ. Comparison of tilt and decentration of 1-piece and 3-piece hydrophobic acrylic intraocular lenses. *J Cataract Refract Surg*. 2005;31:343-347.
- de Castro A, Rosales P, Marcos S. Tilt and decentration of intraocular lenses in vivo from Purkinje and Scheimpflug imaging. *J Cataract Refract Surg*. 2007;33:418-429.
- Rosales P, de Castro A, Jiménez-Alfaro I, Marcos S. Intraocular lens alignment from Purkinje and Scheimpflug imaging. *Clin Exp Optom*. 2010;93(6):400-408.
- Yang Y, Thompson K, Burns SA. Pupil location under mesopic, photopic, and pharmacologically dilated conditions. *Invest Ophthalmol Vis Sci*. 2002;43:2508-2512.
- Taberero J, Piers P, Benito A, et al. Predicting the optical performance of eyes implanted with IOLs to correct spherical aberration. *Invest Ophthalmol Vis Sci*. 2006;47:4651-4658.
- Nishi Y, Hirmschall N, Crnej A, et al. Reproducibility of intraocular lens decentration and tilt measurement using a clinical Purkinje meter. *J Cataract Refract Surg*. 2010;36:1529-1535.