

# Solving the Problem of Negative Dysphotopsia

A new IOL design might be the answer.

BY SAMUEL MASKET, MD

**D**ysphotopsias represent subjective and undesired optical images that are associated with uncomplicated cataract surgery. In essence, positive and negative dysphotopsias (PD and ND) are unanticipated photic consequences. Patients describe PD as streaks and arcs of light, central light flashes, and starbursts. They describe ND as a temporal dark shadow similar to the effect of wearing horse blinders. The etiology and symptomatology of PD and ND differ, but there can be some crossover. Moreover, both conditions can coexist in the same patient.<sup>1</sup> No objective tests to qualify or quantify patients' symptoms are available; ophthalmologists rely solely on patient-reported outcomes.

Dysphotopsia is the chief cause of patients' dissatisfaction after routine cataract surgery, with 49% of patients having some degree of ND or PD postoperatively in one study.<sup>2</sup> According to Bournas et al, 19.5% of cataract patients complained of dysphotopsia on the first postoperative day,<sup>3</sup> a study by Osher found that 15.2% of cataract patients described symptoms of ND on the first postoperative day, and 3.2% did so 1 year after surgery.<sup>4</sup>

Given the annual volume of cataract surgery in the United States, between 30,000 and 100,000 new cases of dysphotopsia will occur each year. Evaluating a patient with dysphotopsia is very difficult, but in the optical laboratory setting, ray-tracing analysis and reflectometry of the materials, surfaces, shapes, and edge designs of IOLs can be helpful.

Dysphotopic complaints should be distinguished from Purkinje images, which are a series of reflections from the surface of the cornea and lens. Accentuated Purkinje images may be associated with IOLs and represent a cosmetic blemish, but they are not associated with functional vision deficits. Additionally, patients may notice a Maddox rod effect (with point sources of light) from

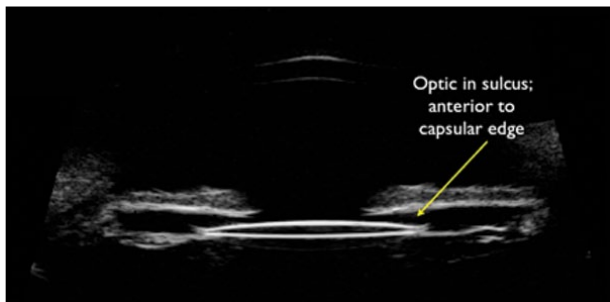


Figure 1. Oblique slit-lamp view of an acrylic square-edged IOL. The angulated beam of light enhances illumination of the edge due to internal reflection.

striae in the posterior capsule; this undesired optical phenomenon is not specific to any IOL and may be managed by a laser capsulotomy, as necessary.

## PD AND IOL DESIGN

Traditionally, nonsequential ray tracing with Zemax software (Zemax Development) has been used to analyze IOLs' optical pathways, surfaces, and edges. A square edge is associated with halos, rings, and arcs of light<sup>5</sup>; PD due to the truncated square edge of ovoid IOLs was first reported in 1993.<sup>6</sup> In the 1990s, before the widespread acceptance and distribution of foldable IOLs, oval PMMA lenses with round or thin (knife) edges were marketed as a means to reduce incision size. Oval IOLs were created by truncating parallel edges of the optic and reducing one dimension from 6 mm to 5 mm. A flat surface that can induce an



**Figure 2.** Ultrasound biomicroscopy demonstration of reverse optic capture. The optic of the IOL lies anterior to the anterior capsulotomy. The haptics are placed in the capsular bag.

internal reflection from oblique illumination is created when the IOL's edge is truncated.<sup>6</sup> Figure 1 demonstrates a clinical example of an internal light reflection, whereby the oblique slit-lamp beam strikes the surface of an acrylic square-edged IOL, causing it to become highly luminescent.

A square edge design reduces posterior capsular opacification by inhibiting migration of equatorial lens epithelial cells along the posterior capsule.<sup>7</sup> For this reason, most IOLs have a (posterior) square edge. The trade-off can be the induction of PD. An internal reflection from the posterior surface of the front of the IOL can also cause PD,<sup>8</sup> suggesting that PD is more likely to occur with IOLs that have relatively flat surfaces and a high index of refraction.

The ophthalmic industry has responded to PD by

- Reducing the thickness of square-edged IOLs and rounding the anterior edge
- Leaving the edge unpolished or frosted. One wonders, however, how this modification reduces internal light reflection.
- Moving more of the IOL's optical power to the anterior rather than posterior surface of the optic

Other opportunities to reduce PD include using materials with a lower index of refraction or reduced surface reflectivity. The latter property has not been addressed by the manufacturing sector and may be an important consideration for reducing both PD and ND.

### COMMON TRENDS ASSOCIATED WITH ND

ND is not as well understood as PD. Interestingly, PD symptoms may improve with pharmacologic pupillary constriction, but the opposite is true for ND, which almost invariably improves with pupillary dilation. The etiology of ND is unclear. Osher suggested that edema surrounding a temporal corneal incision could be responsible for the high early incidence of ND,<sup>4</sup> but this theory may not be true, given that ND has been reported with superior cataract incisions.<sup>9,10</sup> ND has not been

reported with radial or arcuate keratotomies, penetrating keratoplasty, or LASIK flaps.

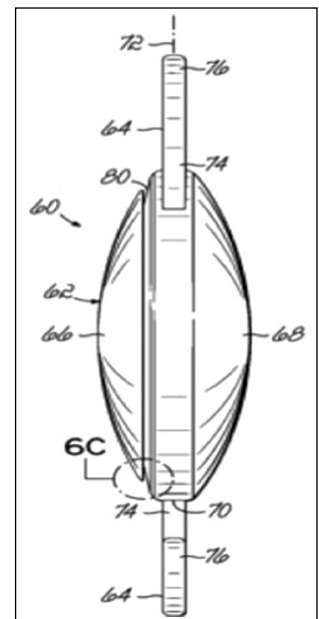
ND symptoms improve over time, possibly due to neuroadaptation. Holladay et al contend that ND represents an enigmatic penumbra related primarily to an IOL's edge design and secondarily to posterior chamber depth and the IOL material's index of refraction.<sup>11</sup> Conversely, Fram and I reported that ND results from the IOL's confinement in the capsular bag, regardless of a lens' material or design.<sup>12,13</sup>

Frustrating for both the surgeon and the patient is that ND only occurs after a "perfect" cataract surgery with a well-centered IOL whose edge is fully covered by the anterior capsulotomy. ND has not been associated with anterior chamber IOLs or sulcus-fixated IOLs.

Based on the studies that I conducted with Nicole Fram, MD, ND symptoms can be relieved surgically by elevating the IOL from the capsular bag to the sulcus,<sup>14</sup> which has been true in my experience. When an acrylic square-edged IOL was exchanged for a silicone round-edged IOL, our patient's ND symptoms persisted. They abated when, in a subsequent surgery, the square-edged IOL was brought anterior to the capsular bag.

Implanting a piggyback IOL has relieved ND symptoms in 75% of our patients. We have also had success with reverse optic capture (Figure 2). This technique has proven to be beneficial in the fellow eyes of patients who were significantly bothered by ND in the previously operated eye, although we cannot be certain that the fellow eye would be equally symptomatic.

Based on our observations with ultrasound biomicroscopy, we believe that the optical interaction between the anterior capsulotomy and the IOL's anterior surface is a contributing factor to or cause of ND. An Nd:YAG laser anterior capsulectomy over the nasal aspect of the IOL has been shown to relieve ND symptoms,<sup>15,16</sup> a finding that corroborates the theory that the interaction between the anterior capsule and the IOL's interface may cause ND.



**Figure 3.** In this artist's drawing of Dr. Masket's IOL design, point 6C indicates the groove designed to capture the anterior capsulotomy.

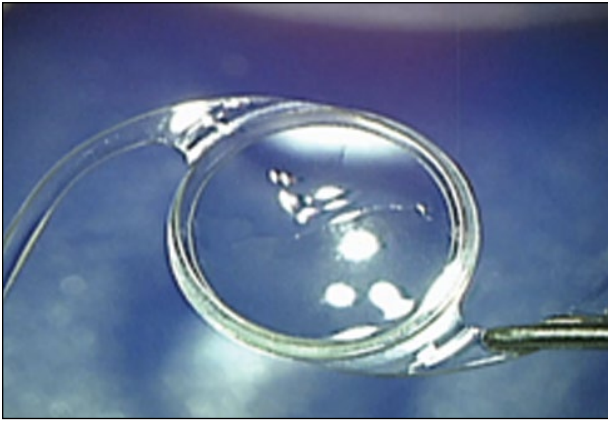


Figure 4. An overview of the Masket ND IOL.

**NEW IOL DESIGN**

The ophthalmic industry has not manufactured an IOL designed to reduce the incidence of ND. There have been anecdotal reports that an oval IOL currently on the market precludes ND, but there are no meaningful studies to support this claim. The risk of oval IOLs' causing PD remains problematic.

I have been granted a US patent for an IOL that is specifically designed to prevent ND (Figure 3). The design concept is based on reverse optic capture. To prevent ND, a peripheral groove is placed anteriorly to accept the anterior capsulotomy, and a lip of the optic overrides the anterior capsule. Other aspects of the IOL's design should allow for any preferred haptic or optic design (toric, multifocal, etc.).

The Masket ND IOL (Morcher) received CE Mark approval in 2013, and a small number of patients have received the lens in a preliminary European clinical trial. (Figure 4). H. Burkhard Dick, MD, PhD, and Tim Schultz, MD, performed the surgeries in Germany; they created the anterior capsulotomy with a femtosec-

(Courtesy of H. Burkhard Dick, MD, PhD, and Tim Schultz, MD.)

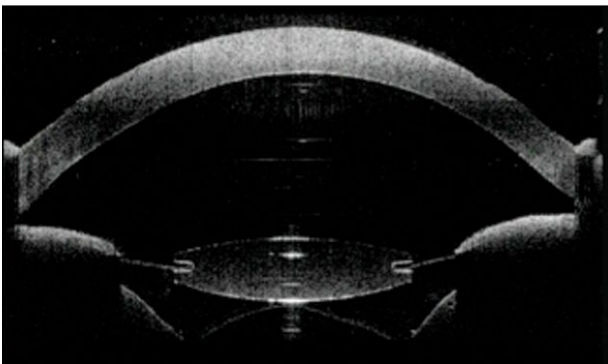
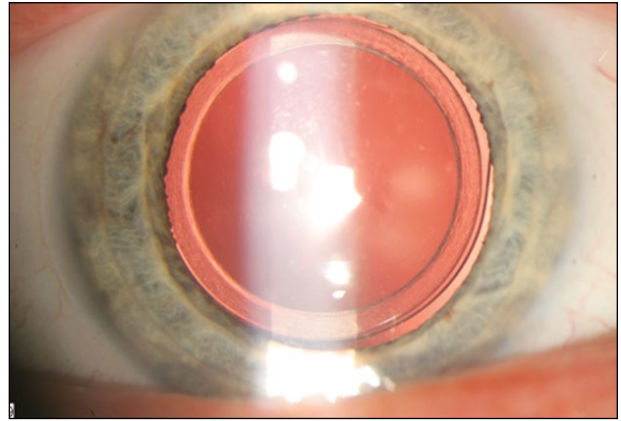


Figure 6. An intraoperative optical coherence tomography scan of the Masket ND IOL demonstrates a groove in the optic holding the anterior capsulotomy.



(Courtesy of H. Burkhard Dick, MD, PhD, and Tim Schultz, MD.)

Figure 5. Postoperative appearance of an eye implanted with the Masket ND IOL.

ond laser (Figures 5 and 6). All five patients who received the IOL have not complained of ND or PD. Based upon this small pilot study, additional clinical trials will be planned, and the IOL will be available for use in Europe in the near term.

Belgian ophthalmologist Marie-Jose Tassignon's "bag-in-the-lens" (BIL) technique adds credence to our theory that ND will be prevented if the anterior portion of the optic overlies the anterior capsular edge. The BIL procedure features a round-edged IOL that has a 5-mm optic surrounded by a peripheral groove and elliptical haptics to receive anterior and posterior capsular leaflets. In an unpublished investigation of 30 patients who underwent the BIL technique, none has experienced ND postoperatively (Bostanci Ceran, MD, personal communication, 2011).

**CONCLUSION**

Dysphotopsia represents a significant source of dissatisfaction for patients after uncomplicated cataract surgery. The incidence and significance should not be overlooked. I remain hopeful that new IOL design concepts will prove valuable toward that end. ■

*Section Editor George O. Waring IV, MD, is the director of refractive surgery and an assistant professor of ophthalmology at the Storm Eye Institute, Medical University of South Carolina. He is also the medical director of the Magill Vision Center in Mt. Pleasant, South Carolina. Dr. Waring may be reached at waringgg@musc.edu.*

*Samuel Masket, MD, is a clinical professor at the David Geffen School of Medicine, Jules Stein Eye Institute, UCLA, and is in private practice in Los Angeles. He has a financial interest in the Masket ND IOL. Dr. Masket may be reached at (310) 229-1220; avcmasket@aol.com.*



1. Davison JA. Positive and negative dysphotopsias in patients with acrylic intraocular lenses. *J Cataract Refract Surg.* 2000;26:1346-1355.
2. Tester R, Pace NL, Samore M, Olson RJ. Dysphotopsia in phakic and pseudophakic patients: incidence and relation to intraocular lens type. *J Cataract Refract Surg.* 2000;26(6):810-816.
3. Bournas P, Drazinos S, Kanellas D, et al. Dysphotopsia after cataract surgery: comparison of four different intraocular lenses. *Ophthalmologica.* 2007;221(6):378-383.
4. Osher RH. Negative dysphotopsia: long-term study and possible explanation for transient symptoms. *J Cataract Refract Surg.* 2008;34(10):1699-1707.
5. Franchini A, Gallarati BZ, Vaccari E. Computerized analysis of the effects of intraocular lens edge design on the quality of vision in pseudophakic patients. *J Cataract Refract Surg.* 2003;29(2):342-347.
6. Masket S, Geraghty E, Crandall AS, et al. Undesired light images associated with ovoid intraocular lenses. *J Cataract Refract Surg.* 1993;19(6):690-694.
7. Nishi O, Nishi K, Wickström K. Preventing lens epithelial cell migration using intraocular lenses with sharp rectangular edges. *J Cataract Refract Surg.* 2000;26(10):1543-1549.
8. Erie JC, Bandhauer MH, McLaren JW. Analysis of postoperative glare and intraocular lens design. *J Cataract Refract Surg.* 2001;27(4):614-621.
9. Masket S, ed. Consultation section. Cataract surgical problem. *J Cataract Refract Surg.* 2005; 31:651-660.
10. Cooke DL. Negative dysphotopsia after temporal corneal incisions. *J Cataract Refract Surg.* 2010; 36:671-672.
11. Holladay JT, Zhao H, Reisin CR. Negative dysphotopsias: the enigmatic penumbra. *J Cataract Refract Surg.* 2012;38:1251-1265.
12. Masket S, Fram N. Pseudophakic negative dysphotopsia: surgical management and new theory of etiology. *J Cataract Refract Surg.* 2011;37:1199-1207.
13. Trattler WB, Whitsett JC, Simone PA. Negative dysphotopsia after intraocular lens implantation irrespective of design and material. *J Cataract Refract Surg.* 2005;31(4):841-845.
14. Vámosi P1, Csákány B, Németh J. Intraocular lens exchange in patients with negative dysphotopsia symptoms. *J Cataract Refract Surg.* 2010;36(3):418-424.
15. Folden DV. Neodymium:YAG laser anterior capsulectomy: surgical option in the management of negative dysphotopsia. *J Cataract Refract Surg.* 2013;39:1110-1115.
16. Cooke DL, Kasko S, Platt LO. Resolution of negative dysphotopsia after laser anterior capsulotomy. *J Cataract Refract Surg.* 2013; 39:1107-1109.