

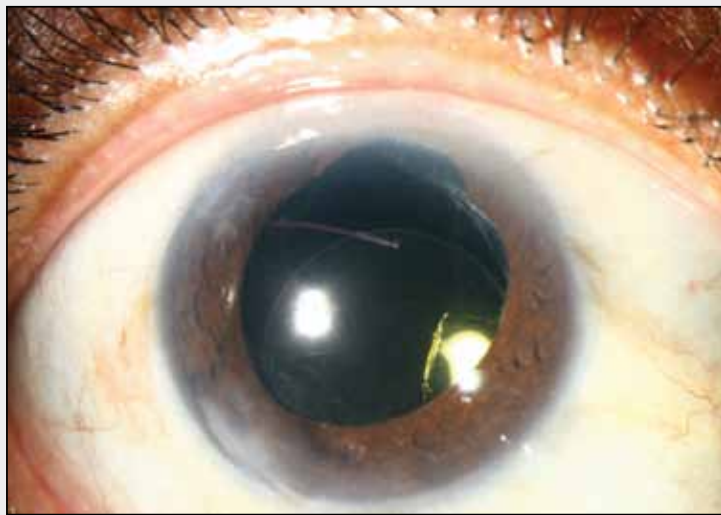
Damaged Iris and Marred, Unstable IOL

BY JAMES T. BANTA, MD; SOOSAN JACOB, MS, FRCS, DNB; AND DIAMOND Y. TAM, MD, DABO

CASE PRESENTATION

A 50-year-old man with no past history of inflammation or known trauma underwent complicated cataract surgery on his right eye. The anterior capsule was fibrotic and did not allow for a continuous capsulotomy. A radial tear of the capsule went posterior. The IOL was placed in the sulcus but has not been stable. An attempted repositioning of the IOL that included an anterior vitrectomy resulted in iatrogenic damage to the superior iris and continued concerns regarding the IOL's instability.

Figure 1 shows the patient's current presentation. The IOL is inferior, and some vitreous is present superiorly into the anterior chamber. Marring of the three-piece acrylic IOL near the visual axis appears to go through the entire lens. The superior iris defect leaves the pupil at about 5 mm undilated. The patient has pigmentary glaucoma, most likely secondary to the sulcus-fixed IOL, and an IOP of 25 mm Hg on maximal medical therapy. He is taking prednisolone, which may also contribute to the elevated IOP.



(Courtesy of Thomas A. Oetting, MS, MD)

Figure 1. A slit-lamp examination shows the marred, dislocated IOL and an iris defect at about 12 o'clock.

How would you manage this case? How do you judge if a defect in an IOL is significant? How would you secure the IOL, or would you exchange it for another IOL?

—Case prepared by Thomas A. Oetting, MS, MD.

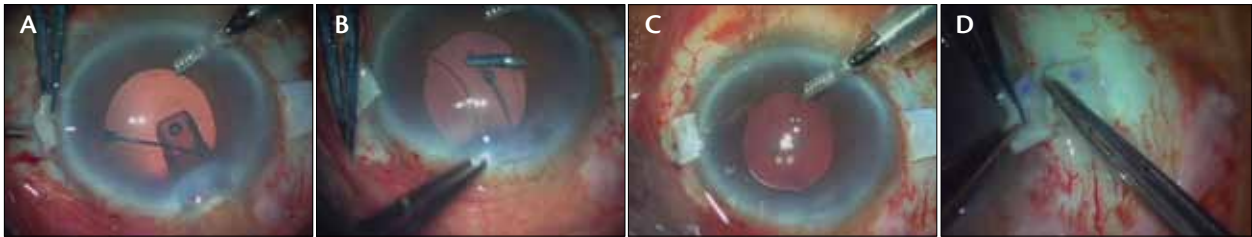
JAMES T. BANTA, MD

Third time is the charm, right? There are multiple issues in the case: vitreous prolapse, IOL subluxation, iris defect, IOL scratches, and ocular hypertension, potentially exacerbated by the sulcus-fixed IOL.

This case is difficult, but it does seem that surgery will be necessary to improve the patient's situation. The level of glare is likely unmanageable. I would prefer to perform a core anterior vitrectomy, explant the IOL and what is left of the capsular bag, repair the iris defect superiorly, and finally iris fixate a new IOL. I would start by creating two 20-gauge paracenteses

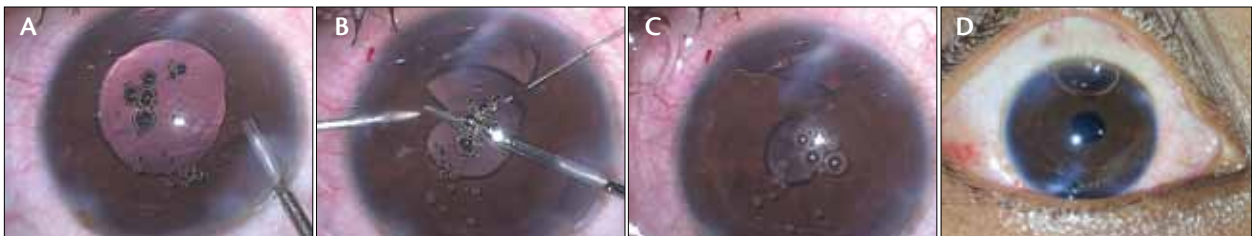
and perform a bimanual anterior vitrectomy. After creating a 2.5-mm temporal wound, I would prolapse the IOL into the anterior chamber, bisect it using Packer/Chang IOL cutters (MicroSurgical Technology; the instrument is delicate but cuts acrylic like butter), and remove the IOL from the eye. I would then perform further vitrectomy and remove the capsular bag.

Using a 10-0 Prolene suture on a CIF-4 needle (Ethicon, Inc.), I would repair the superior iris defect with one or two Siesper sliding knots. After instilling a miotic (eg, acetylcholine) to bring down the pupil, I would mustache fold a three-piece IOL and carefully



(Courtesy of Soosan Jacob, MS, FRCS, DNB)

Figure 2. The haptic of the IOL is grasped at its tip by a glued IOL forceps introduced through the sclerotomy under the scleral flap (A). The trailing haptic is flexed into the anterior chamber and is also grasped in a similar manner (B). Both of the IOL's haptics are thus exteriorized (C). Both of the haptics are tucked into intrascleral Schiøtz tunnels made at the edge of the scleral flap (D).



(Courtesy of Soosan Jacob, MS, FRCS, DNB)

Figure 3. A posttraumatic cataract with inferior iris coloboma. After phacoemulsification, the surgeon implants the IOL in the bag (A). Vertical cuts are followed by suturing of the central iris leaflets (B). The first knot is followed by a series of additional knots down the length of the iris defect (C). The sutured iris and a pleasing round contour of the pupil are visible on the first postoperative day (D).

prolapse the optics through the pupil, thereby capturing the optic anterior to the iris. A second instrument such as a cyclodialysis spatula can be utilized through a paracentesis opposite the site of the incision to prevent the accidental loss of the IOL into the posterior segment.

Next, I would use another 10–0 Prolene suture on a CIF-4 needle to secure each haptic, again using a Siepser sliding knot. Great care must be taken when making the passes of this long curved needle through the anterior chamber. As the needle is being removed from the eye, if any upward movement of the distal aspect is made, the proximal portion of the needle that is still in the anterior chamber can actually push the optic through the pupil and into the posterior segment. The eye sometimes needs to be grasped with a forceps and rotated away from the exit point of the needle to allow a gentle, planar exit from the eye. Once the suture ties are complete, the IOL optic is prolapsed into its new position. The IOL tends to hang back a bit from the iris, which should prevent any iris chafing. I typically aim for bag power (not sulcus, which tends to create myopic outcomes).

A longer course of postoperative steroids (6-8 weeks) is indicated, because a mild iritis is not unusual after iris fixation.

SOOSAN JACOB, MS, FRCS, DNB

Taking into consideration the inadequate sulcus support, my preference would be a glued IOL that provides stable transscleral sutureless IOL fixation.¹ With a three-piece IOL, it would have been a relatively simple procedure to translocate the same lens by a closed-globe technique via only two sclerotomy incisions.² In this case, however, I would favor IOL explantation combined with a glued IOL, owing to the full-thickness crack in the IOL somewhat close to the visual axis and the fact that this would be the third and possibly final surgery (both the patient and the eye's being unlikely to react favorably to any further corrective surgery).

First, I would fix an anterior chamber maintainer and perform an anterior vitrectomy assisted by triamcinolone acetonide (Tricort; Cadila Pharmaceuticals Ltd.). I would also remove any vitreous strands keeping the pupil fixed. Next, I would partially cut the IOL with Packer/Chang IOL cutters and explant it after coating the corneal endothelium with a dispersive viscoelastic.³ I would then create scleral flaps and underlying sclerotomies and implant a three-piece foldable glued IOL through the main port using the handshake technique (Figure 2).⁴



I would try to fix the iris, which appears to have been inadvertently chewed up and looks similar to an iris coloboma. I would use Robert Osher's technique of coloboma repair with two vertical cuts at the edges followed by a modified Siepser's sliding knot technique (Figure 3).^{5,6}



Postoperatively, I would prescribe a very short course of topical steroids followed by topical nonsteroidal antiinflammatory drugs. I would manage the patient's glaucoma medically because of the chance of spontaneous improvement after the removal of the possible inciting factors (sulcus-fixed IOL, vitreous in the anterior chamber, and steroids).

DIAMOND Y. TAM, MD, DABO

This challenging case begins with a careful preoperative evaluation and planning. Because this patient has undergone multiple surgical procedures, it is essential to assess the status of the cornea, the IOL's position, the optic nerve, and the retina with an endothelial cell count, ultrasound biomicroscopy, automated visual field testing and optical coherence tomography of the anterior and posterior segments. The results of these tests are important, because they may alter the surgical procedure and what is done with the IOL.

The objectives in this case are to secure the IOL, repair the damaged iris, and clear the anterior chamber of vitreous. The results of the optic nerve assessment and visual field testing would dictate whether I combined any IOL and iris maneuvers with a glaucoma procedure. If the patient has glaucomatous disc damage, I would consider placing one or more iStent Trabecular Micro-Bypass Stents (Glaukos Corporation) into the trabecular meshwork at the time of surgery and, in certain situations of severe or advanced disease, might even consider performing concurrent tube shunt surgery. This patient, however, is not currently on topical antihypertensive agents. It is therefore probable that, once the stimulus for pigment dispersion is removed and the patient is weaned off topical steroids, his IOP will normalize and he will not need surgical intervention for glaucoma.

Turning my attention, then, to the subluxated IOL, my preference in this case would be to remove the existing IOL and implant an iris claw IOL (Artisan; Ophtec BV). Placing the IOL in this position would remove any stimulus for pigment dispersion or of iris or ciliary body tissue irritation, avoid the potential pitfall of unreliable iris tissue to which to suture a PCIOL, and obviate the need for an angle-supported ACIOL, which might further aggravate any problems related to the angle, iris, or glaucoma. Prior to implanting the iris claw IOL, I would perform a suture pupilloplasty to close the superior iris defect, likely with two or three interrupted

10–0 polypropylene sutures. If preoperative imaging and testing revealed a low endothelial cell count, a relative anterior microphthalmos, or a shallow anterior chamber, I would use the scleral, glued technique to fixate a PCIOL.

Pitting of and damage to the lens, for example when performing a laser capsulotomy, frequently are not visually significant, even in a central location. It is my experience, however, that confluent damage that is central or paracentral on the optic can be. In this particular case, given the location and confluent linear pattern of the damage to the optic, whatever surgical approach I used, I would remove this IOL. ■

The Artisan lens is not FDA approved for use in aphakic eyes.

Section Editor Thomas A. Oetting, MS, MD, is a clinical professor at the University of Iowa in Iowa City. Dr. Oetting may be reached at (319) 384-9958; thomas-oetting@uiowa.edu.

Section Editor Tal Raviv, MD, is an attending cornea and refractive surgeon at the New York Eye and Ear Infirmary and an assistant professor of ophthalmology at New York Medical College in Valhalla.

Section Editor Audrey R. Talley Rostov, MD, is in private practice with Northwest Eye Surgeons, PC, in Seattle.

James T. Banta, MD, is an associate professor of clinical ophthalmology at Bascom Palmer Eye Institute, University of Miami Miller School of Medicine. He acknowledged no financial interest in the products or companies he mentioned. Dr. Banta may be reached at (305) 326-6185; jtbanta@med.miami.edu.



Soosan Jacob, MS, FRCS, DNB, is a senior consultant ophthalmologist at Dr. Agarwal's Eye Hospital and Eye Research Centre in Chennai, India. She acknowledged no financial interest in the products or companies she mentioned. Dr. Jacob may be reached at dr_soosan@hotmai.com.



Diamond Y. Tam, MD, DABO, is in private practice in Toronto. He acknowledged no financial interest in the products or companies he mentioned. Dr. Tam may be reached at diamondtam@gmail.com.



1. Agarwal A, Kumar DA, Jacob S, et al. Fibrin glue-assisted sutureless posterior chamber intraocular lens implantation in eyes with deficient posterior capsules. *J Cataract Refract Surg.* 2008;34(9):1433-1438.
2. Prakash G, Agarwal A, Jacob S, et al. Translocation of malpositioned posterior chamber intraocular lens from anterior to posterior chamber along with fibrin glue-assisted transscleral fixation. *Eye Contact Lens.* 2010;36(1):45-48.
3. IOL cutter small size, strength boons to IOL explantation procedure. *Ophthalmology Times.* Published September 15, 2008.
4. Agarwal A, Jacob S, Kumar DA, et al. Handshake technique for glued intrascleral haptic fixation of a posterior chamber intraocular lens. *J Cataract Refract Surg.* 2013;39(3):317-322.
5. Cionni RJ, Karatza EC, Osher RH, Shah M. Surgical technique for congenital iris coloboma repair. *J Cataract Refract Surg.* 2006;32(11):1913-1916.
6. Osher RH, Snyder ME, Cionni RJ. Modification of the Siepser slipknot technique. *J Cataract Refract Surg.* 2005;31:1098-1100.