

Update on Capsular Tension Rings

Identifying zonular weakness during the preoperative examination will reduce the likelihood of intraoperative complications.

BY MITCHELL A. JACKSON, MD

Capsular tension rings (CTRs), well known to ophthalmic surgeons, are C-shaped devices used to stabilize the capsular bag of the crystalline lens during cataract surgery in eyes with zonular weakness. This problem is most often seen in cases of trauma, pseudoexfoliation syndrome, previous ocular surgery (eg, vitrectomized eyes), mature/hypermature cataracts, and high myopia. Less common causes of zonular weakness include Marfan's syndrome, homocystinurea, Weill-Marchesani syndrome, microspherophakia, retinitis pigmentosa, lens coloboma, scleroderma, porphyria, hyperlysinemia, and intraocular neoplasms.¹⁻³ Zonular weakness can increase the risk of capsular tears, retained lens material, vitreous prolapse, and a decentered and/or unstable lens postoperatively.

HISTORY

The CTR was first introduced in 1991 by Hara et al and was implanted in the first human eye during cataract surgery in 1993 by Witschel and Legler.^{4,5} CTRs of various designs (eg, standard, Cionni Rings for Sclera Fixation, Ahmed Capsular Tension Segments [CTSs]) are

now available for use in eyes with weak zonules. All of these products are manufactured by Morcher GmbH (Stuttgart, Germany) and are distributed in the United States by FCI Ophthalmics, Inc. (Marshfield Hills, MA) (Figures 1 through 5).

Identifying zonular weakness during the preoperative examination will reduce the likelihood of intraoperative complications. Signs of zonular weakness may include a subtle iridodonesis, phacodonesis, a subluxated crystalline lens, or vitreous herniation into the anterior chamber. All are visible preoperatively at the slit lamp. Intraoperatively, anterior capsular wrinkling during the initial capsulorhexis puncture or movement of the capsular bag during the capsulorhexis may indicate where the zonules are the weakest. Surgical planning should include the placement of a CTR when the clinical history or slit-lamp findings suggest an increased risk of zonular compromise.

STANDARD CONSTRUCTION

The standard CTR is a C-shaped, open ring made of polymethylmethacrylate. It features eyelets at both ends

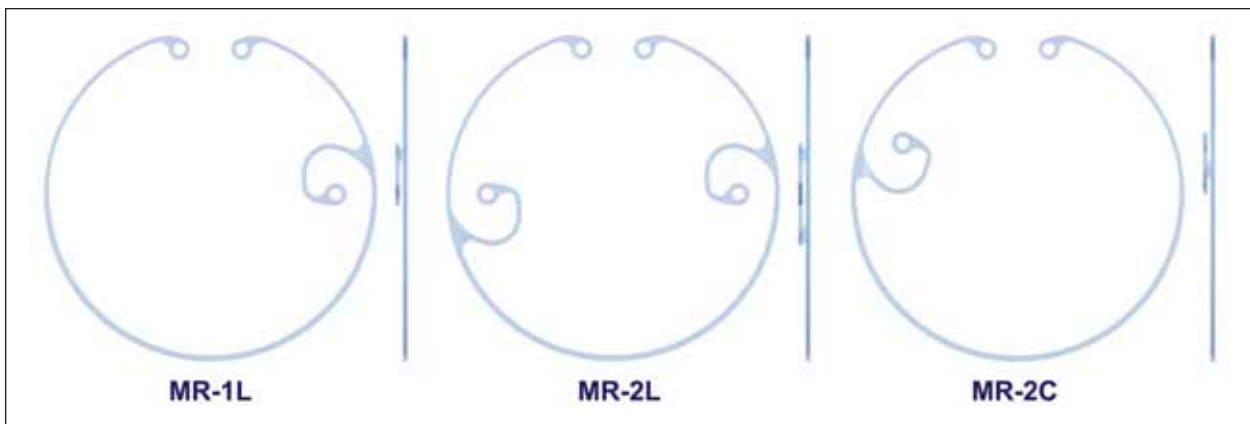


Figure 1. The Cionni Rings for Sclera Fixation.



Figure 2. The Ahmed CTS.

to avoid entrapment on the capsular equator upon insertion and to facilitate the use of a second instrument. The surgeon chooses the size of a CTR based on the dimensions of the capsular bag (ie, a large capsular bag usually requires a large CTR). Studies have shown the size of the capsular bag correlates with the globe's axial length.⁶

The standard Morcher CTR comes in three sizes based on uncompressed diameter: 12.3 mm (compresses to 10 mm, Morcher 14, used for axial length < 24 mm), 13 mm (compresses to 11 mm, Morcher 14C, used for axial length of 24-28 mm), and 14.5 mm (compresses to 12 mm, Morcher 14A, used for axial length > 28 mm). The Henderson CTR⁷ (from Morcher GmbH, distributed in the United States by FCI Ophthalmics, Inc.) differs from the standard ring in that the former has eight equally spaced indentations of 0.15 mm and an uncompressed diameter of 12.29 mm that is compressible to 11 mm. The main advantage of the Henderson CTR is that it allows for easier removal of nuclear and cortical material while maintaining equal expansion of the capsular bag. The Geuder injector (from Morcher GmbH, distributed in the United States by FCI Ophthalmics, Inc.) is a simple one-handed delivery system for a CTR through small or microincision, and it can be used with the standard or Henderson CTR.

INDICATIONS

Mild Zonular Instability

As stated, a standard Morcher CTR or the Henderson design are best used in cases of mild zonular instability

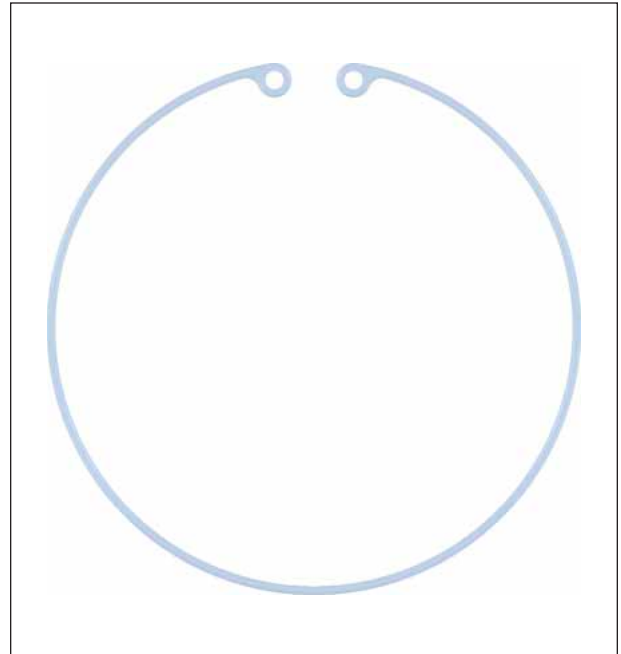


Figure 3. A standard Morcher CTR.

(for example, zonulysis visible for fewer than 4 clock hours), mild pseudoexfoliation, any case of suspected progressive zonular weakness (such as in Marfan's syndrome, as long as there is no lens subluxation), or stable, localized zonular dehiscence (such as in trauma). A CTR is contraindicated for eyes with anterior or posterior radial tears in the capsule that could extend with the device's placement, thus risking its loss in the posterior segment.

Progressive Zonulopathy

In cases of progressive or advanced zonulopathy, a standard or Henderson CTR is unlikely to provide the capsular support needed and will most likely allow the IOL to dislocate postoperatively. In 1998, Robert Cionni, MD, modified the standard CTR to create an open-ring design with one (model 1 L) or two (model 2 L) fixation eyelets attached to the central ring. These eyelets allow the ring to be sutured to the sclera, typically with a 9-0 polypropylene suture. The Cionni Rings for Sclera Fixation can only be placed after nuclear and cortical removal, so they cannot provide intraoperative support during phacoemulsification. These devices allow for excellent lens centration. To prevent iris chafing from the central eyelets, the Cionni CTR should not be used unless the capsulorhexis is at least 5.5 mm.

Superior Zonular Support

In 2002, Iqbal Ike Ahmed, MD, designed partial polymethylmethacrylate ring segments with 120° of arc

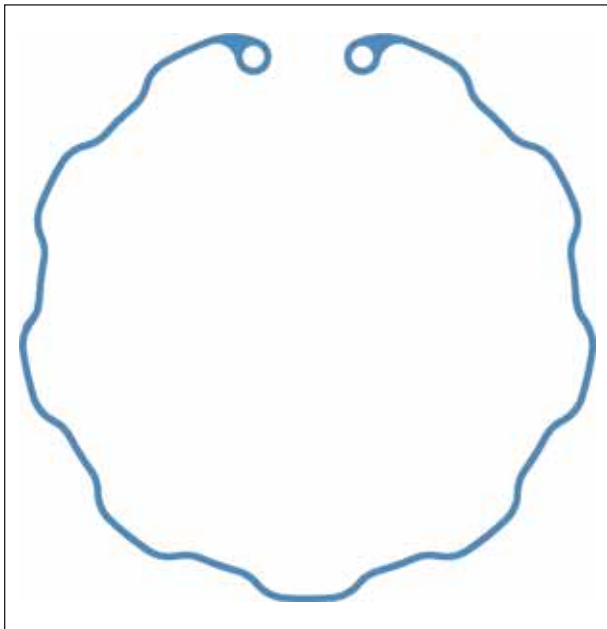


Figure 4. A Henderson CTR.

length and a 5-mm radius of curvature. Like the Cionni CTR, Ahmed CTSs have an anteriorly positioned eyelet for suturing to the sclera. Model MR-6D is 9.61 mm in length, and the MR-6E is 0.14 mm in length.

The advantages of the CTS compared with the CTR are that the former can be implanted without a dialing technique, which minimizes trauma to an already-compromised zonular apparatus. CTSs can be placed after the capsulorhexis and before cataract removal, and they can be slid into the area of greatest zonular weakness. CTSs can be used in cases of a discontinuous capsulorhexis, anterior capsular tears, or posterior capsular rents. Intraoperatively, the main body of the CTS sits within the capsular bag in the quadrant desired. The central eyelet remains in front of the anterior capsule and can be supported with an iris retractor through it during phacoemulsification (ie, coat hanger analogy). After cataract and cortical removal, the CTS can be sutured through the same eyelet to the scleral wall to provide transverse plane support. One or two CTSs can be placed simultaneously and sutured separately to give additional support as needed.

Surgeons can use a CTR in conjunction with CTSs after cataract removal to give additional circumferential support for long-term stability of the IOL in cases of advanced zonulolysis.

SUMMARY

Although cataract surgery has progressed from large-incision lensectomies to microincisional pha-



Figure 5. The Geuder injector.

coemulsification, zonular compromise still raises intraoperative risks and can negatively affect the IOL's long-term stability. CTRs and CTSs provide a useful solution to zonular compromise. ■

Mitchell A. Jackson, MD, is founder and medical director of Jacksoneye in Lake Villa, Illinois. He acknowledged no financial interest in the products or companies mentioned herein. Dr. Jackson may be reached at (847) 356-0700; mjlaserdoc@msn.com.



1. Kohnen T, Baumeister M, Bühren J. Scheimpflug imaging of bilateral foldable in-the-bag intraocular lens implantation assisted by a sclera-sutured capsular tension ring in Marfan's syndrome. *J Cataract Refract Surg.* 2003;29:598-602.
2. Osher RH. History and experience with capsular tension rings. *Cataract and Refractive Surgery Today.* 2005; Jan;5(1):1-5.
3. Hayashi K, Hayashi H, Matsuo K, et al. Anterior capsular contraction and intraocular lens dislocation after implant surgery in eyes with retinitis pigmentosa. *Ophthalmology.* 1998;105:1239-1243.
4. Hara T, Hara T, Yamada Y. "Equator ring" for maintenance of the completely circular contour of the capsular bag equator after cataract removal. *Ophthalmic Surg.* 1991;22:358-359.
5. Witschel B, Legler UFC. The capsular ring. *Video Journal of Cataract and Refractive Surgery.* 1993;9(4).
6. Vass C, Menapace R, Schetterer K, et al. Prediction of pseudophakic capsular bag diameter based on biometric variables. *J Cataract Refract Surg.* 1999;25:1376-1381.
7. Henderson BA, Kim JY. Modified capsular tension ring for cortical removal after implantation. *J Cataract Refract Surg.* 2007;33:1688-1690.

CONTACT US

Send us your thoughts via e-mail to
letters@bmcctoday.com.