

FIVE THINGS EVERY CATARACT SURGEON MUST KNOW ABOUT THE RETINA

An understanding of these issues will help to ensure success in patients with retinal disease.

BY DENNIS P. HAN, MD, AND TEODORO EVANS, MD



Cataract surgery is the most common intraocular procedure performed worldwide. Because cataract surgery is usually performed on elderly patients, many of whom are at risk for retinal disease, it is important that the surgeon

be aware of implications for the retina. This article presents the five things that every cataract surgeon must know about the retina. A thorough understanding of these five points can make the difference between success and disappointment.

No. 1. PROPHYLAXIS AGAINST RETINAL PROBLEMS: WHAT TO PREVENT AND HOW

There are two major adverse events involving the retina that can occur after cataract surgery: retinal detachment and cystoid macular edema (CME).

Retinal detachment is estimated to occur in about 0.7% of patients after cataract surgery, even in the era of phacoemulsification and extracapsular-type procedures.¹ Few studies exist regarding preoperative interventions to manage this risk. Most cataract surgeons try to avoid vitreous loss and attempt to minimize the need for a posterior capsulotomy, both of which are events that increase the risk of retinal detachment.

Is there a role for prophylactic retinal laser photocoagulation? Some studies strongly support the application of retinal laser treatment in certain patients with retinal tears, but none has rigorously evaluated the outcomes of laser treatment in patients about to have cataract surgery.² At minimum, it seems reasonable to apply general guidelines for prophylactic treatment for such patients. The American Academy of Ophthalmology's Preferred Practice Patterns provide such guidelines. We have considered these guidelines in creating our own approach to the cataract patient with retinal breaks or lattice degeneration (see *When Is Prophylactic Laser Treatment Recommended Before Cataract Surgery?*). We strongly prefer laser rather than cryotherapy for prophylaxis.

The incidence of postoperative CME, also called Irvine-Gass

syndrome, seems to be low in uncomplicated cases, ranging from 0.2% to 2%.³⁻⁵ Recommendations vary significantly on topical prophylaxis of CME in the routine cataract patient. However, if there are complications from surgery, such as vitreous presentation, a dropped nucleus, or endophthalmitis that has resolved, a role for CME prevention may exist. In addition, patients with a history of retinal vein occlusion or macular epiretinal membranes have been noted to have a 32-fold and fivefold increase in their risk of CME, respectively. Randomized trials specific to these conditions have not been performed. However, Oetting (see *Sample Regimen for Topical Prophylaxis Against Postoperative CME*) suggests a sample regimen to reduce CME risk in such patients.⁶

In patients with preexisting diabetic retinopathy without diabetic macular edema (DME), the rate of postoperative macular edema approaches 0%.⁷ It is not clear that topical CME prophylaxis is justified in such cases. Patients who undergo treatment with topical corticosteroid therapy should be monitored for elevated IOP.

No. 2. MANAGING THE PATIENT WITH AGE-RELATED MACULAR DEGENERATION

The presence of age-related macular degeneration (AMD) can limit the magnitude and duration of visual improvement after cataract surgery and can even preclude such surgery. To optimize outcome, the ophthalmologist must determine three things: (1) the degree of improvement expected from surgery, (2) the expected duration of improvement, and (3) the impact that this improvement will have on the patient's quality of life.

The Figure helps visualize graphically what can happen after cataract surgery in a patient with AMD progression. The area of the triangle labeled "Vision Value" takes into account the magnitude and duration of improvement. The impact on quality of life could be a third dimension of this triangle. Understanding the concept of maximizing vision value can help with decision making.

Obtaining a thorough history is important. Patients with rapid visual loss, a scotoma, or metamorphopsia should be suspected of having something other than cataract. Always ask the

patient to characterize his or her visual loss. “How would you describe your vision difficulty?” Do not just look at the visual acuity measurement on the chart. If the patient describes visual symptoms as like looking through a fog or a film, it suggests that cataract may be the actual problem, rather than a more focal retinal disturbance in the macula.

The amount of visual improvement possible is usually judged by the density of the cataract and the amount of underlying macular disease, both of which can usually be determined with direct and indirect slit-lamp biomicroscopy. In judging the visual impact of the cataractous lens, retroillumination of the lens is superior to viewing with direct illumination, because the anteriorly directed light scatter with the latter technique can confuse the examiner.

To judge the amount of optical aberration in the lens and cornea, a direct ophthalmoscope at its brightest light setting can be held 2.5 cm from the patient’s eye, focused on the lens and retroilluminating it with the fundus red reflex. The amount of obscuration or disruption of the homogeneity of the red reflex should be consistent with visual acuity impairment. This examination technique can be superior to direct illumination from the slit-lamp examination. For example, not all 2+ nuclear sclerotic cataracts are the same in causing visual loss, and the retroillumination technique can help to make this distinction. In addition, using the direct ophthalmoscope, the examiner can distinguish lenticular from corneal aberrations by moving his or her head from side to side to determine the geometric plane of the abnormality using the parallax effect.

It is controversial whether cataract surgery makes AMD worse.⁸ If a cataract has reached a level of severity sufficient to reduce visual function, such worsening is likely to be insignificant relative to the current state of the macula. It is thus important to recognize lesions that are relevant to visual function in the present or the near future. We have called these lesions “the good, the bad, and the ugly.”

The “good” lesions are consistent with good postoperative visual acuity of lasting duration. They consist of small to intermediate drusen (< 125 μm) or eccentric pigmentary change or atrophy of the retinal pigment epithelium (RPE) distant (> 1 disc diameter) from the macular center. Absence of visual loss from AMD in either eye is also reassuring. Such patients can have years of excellent function.

The “bad” lesions cause moderate to severe visual loss that can nearly immediately counter any beneficial effect from the cataract surgery. They include neovascular pigment epithelial detachments and choroidal neovascular membranes. These lesions can mimic a rapidly worsening cataract, bring a patient to the surgeon’s attention, and then lead to ineffective surgery. They are hard to detect preoperatively, because there is no coloration change in the fundus, and the subtle changes are obscured by the cataract itself.

Patients with these bad lesions who undergo cataract surgery may later say, “I had cataract surgery, and it made me worse.”

WHEN IS PROPHYLACTIC LASER TREATMENT RECOMMENDED BEFORE CATARACT SURGERY?

Laser treatment definitely recommended:

- symptomatic horseshoe tear
- acute traumatic retinal breaks

Controversial, but the authors usually perform treatment:

- symptomatic operculated tear (operculum highly separated from retina may allow observation)
- lattice degeneration when the contralateral eye has had retinal detachment^a
- asymptomatic horseshoe tear

Treatment probably unnecessary but sometimes done:

- asymptomatic operculated tear

Treatment not done:

- asymptomatic atrophic hole (round or oval, nonoperculated)
- lattice degeneration without a history of retinal detachment in the fellow eye
- age-related retinoschisis with or without outer retinal holes¹

^aIn patients with lattice degeneration and a history of retinal detachment in the other eye, prophylactic laser photocoagulation is provided only if there is less than 6.00 D of myopia and fewer than 6 clock hours of involvement of lattice degeneration. Treatment to surround all lattice lesions, as opposed to just selected lesions, appears most effective.²

1. Byer, NE. Long-term natural history study of senile retinoschisis with implications for management. *Ophthalmology*. 1986;93:1127-1137.

2. Folk JC, Arrindell EL, Klugman MR. The fellow eye of patients with phakic lattice retinal detachment. *Ophthalmology* 1989;96:72-79.

It is extremely difficult to restore the confidence of the patient in his or her cataract surgeon. Preoperative optical coherence tomography can be helpful to avoid this scenario, as its use is highly recommended when AMD abnormalities are poorly seen because of the cataract or when the cataract does not seem to fully explain the patient’s visual loss. A fundus fluorescein angiogram may also be justified in highly suspicious cases.

Patients with active choroidal neovascularization exhibit exudative signs of subretinal or intraretinal fluid or hemorrhage, lipid exudates, serous pigment epithelial detachment, or sub-RPE hemorrhage. When a crisp view of the normal RPE granularity or choroidal vasculature is lost, you should suspect exudative change. Intravitreal injection of anti-vascular endothelial growth factor agents is essential to stabilize visual function; this process may take several months and require ongoing anti-vascular endothelial growth factor therapy. Once the neovascularization is stabilized, cataract surgery can be considered, but not until then. Currently, there is no

SAMPLE REGIMEN FOR TOPICAL PROPHYLAXIS AGAINST POSTOPERATIVE CME^a

- Topical nonsteroidal anti-inflammatory drug (eg, ketorolac four times daily, nepafenac twice daily, bromfenac once daily): Begin 1 week prior to surgery, stop for 1 week postoperatively to permit corneal re-epithelialization, and then resume.
- Topical prednisolone acetate 1% four times daily, then taper; if cystoid macular edema appears, resume four times daily until it resolves.
- Continue 4 to 8 weeks after surgery, depending on risk (eg, eyes with previous diabetic macular edema or patients with history of cystoid macular edema in fellow eye are treated longer).

^aAdapted from Oetting.⁶

consensus regarding the issue of timing of intravitreal injection around cataract extraction.

The “ugly” lesions predispose the eye to visual loss over a period of years. Although they may not be a contraindication to surgery, the patient should be informed that visual improvement may have a limited time span. Such lesions consist of large soft drusen ($\geq 125 \mu\text{m}$ in diameter) or pigmentary abnormalities. Patients with both of these lesion types in both eyes have about a 50% chance of severe AMD and visual loss over a period of 5 to 7 years. A simplified scoring system determined by the Age-Related Eye Disease Study Group has stratified the risk of visual loss according to these findings.⁹

Patients with geographic RPE atrophy with lesions near the fovea are also at risk. Growth of such lesions has been estimated at 1.61 mm^2 of surface area per year.¹⁰ This equates to a radial expansion of such lesions by about $600 \mu\text{m}$ per year (ie, more than one-third of a disc diameter, involving about 2° of the visual field). Whether or not this amount is applicable to expansion toward the fovea itself, it is advisable to inform a patient with RPE atrophy near the fovea that the benefit of surgery may not last forever.

No. 3. IMPACT ON QUALITY OF LIFE: DOES THE AMOUNT OF VISUAL IMPROVEMENT MAKE A DIFFERENCE?

Knowing your patient’s lifestyle and activities is important to determine if the potential magnitude and duration of visual improvement justifies the risks of cataract surgery. The visual requirements of an active 60-year-old woman who travels, reads novels, and is the editor of the local gardening club newsletter are much different from those of an 85-year-old man with a history of a hemispheric cerebrovascular accident whose main activity is watching football a couple of times a week.

Take the time to ask your patient how much he or she is impaired and what type of change in visual function it would take to make a difference in his or her life. Find out what the patient’s goals for improvement are and judge whether you will be able to meet his or her expectations. You will gain the patient’s trust and confidence by paying attention to these details. It is not just the “area under the

vision curve” that makes a difference but how much impact it will have on the patient’s life.

Potential acuity testing, although important in selected cases, has numerous limitations that reduce its utility in most patients. Visual potential can be underestimated in eyes with dense cataracts. Potential acuity testing has also been less reliable if the preoperative visual acuity is less than 20/200 or if there is already severe maculopathy present. Psychomotor retardation, communication barriers, and optical aberrations from corneal or ocular surface disease can also limit the utility of potential acuity testing.¹¹ Thus, its greatest value is in eyes in which the clinical examination is inconclusive because of mild to moderate cataracts that approach clinical significance, there are no severe macular abnormalities on fundus exam, and there is uncertain macular function. In such patients, a well-performed potential acuity test may be decisive.

The simplest potential acuity tests are the most reliable. Near visual acuity that exceeds the patient’s distance acuity is the easiest. The potential acuity pinhole test described by Melki offers ease of administration, ready availability of test equipment in most clinics, and reportedly better prediction compared to the potential acuity meter or laser interferometry.^{12,13} For this test, the patient reads a near card illuminated with a muscle light held 14 inches away while looking through a pinhole aperture.

No. 4. CHOICE OF IOL IN RETINA PATIENTS

In patients with macular disease, optical image quality should take higher priority than ease of accommodation. Thus, if you suspect that vision-limiting macular disease is present or is likely to develop, it is best to avoid diffractive multifocal or accommodating IOLs, as these types of lenses will reduce contrast sensitivity, especially in mesopic conditions.¹⁴

In patients with diabetic retinopathy, it is often best to avoid IOLs with small optics that will limit peripheral laser photocoagulation. In addition, polyacrylic lenses are preferred over silicone and PMMA to reduce posterior capsular opacification

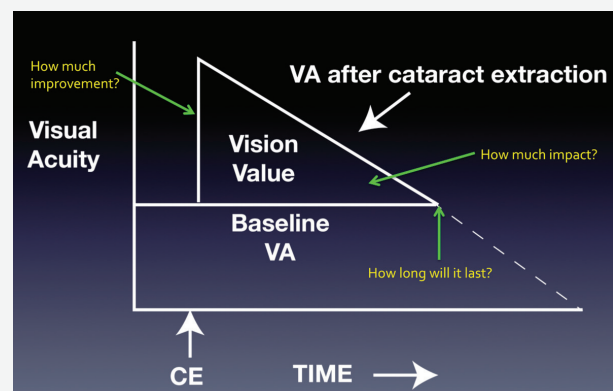


Figure. A graphic representation of what can happen after cataract surgery in a patient with AMD progression.

and the need for subsequent laser capsulotomy,¹⁵ which may predispose the eye to anterior segment neovascularization if severe diabetic retinopathy develops.

In patients who are at risk for retinal detachment, it is best to avoid silicone IOLs due to the potential for lens-oil integration and degradation of the optical quality of the lens. As recommended by Dewey, if an eye is expected to retain silicone oil indefinitely, the ideal IOL is one with an anterior-convex, posterior-plano optic placed in the capsular bag.¹⁶ In addition, retained silicone oil causes a hyperopic shift, so that power must be added to the IOL—typically about 3.00 D.

Removal of a cataract in the presence of retained silicone oil must be performed without capsular rupture or zonular dehiscence to avoid the challenges of silicone oil's migrating forward and clogging the phaco or aspiration needle. Because of the buoyancy of silicone oil, it may continue to migrate into the anterior chamber throughout the procedure. Be prepared to remove all of the silicone oil from the eye if this occurs. Seek consultation with a retina surgeon regarding the implications of such an event before you embark on cataract surgery.

No. 5. TECHNICAL CHALLENGES IN THE POSTVITRECTOMY PATIENT

As indications for pars plana vitrectomy expand, so does the number of patients who will develop postvitrectomy nuclear sclerotic cataract. Dewey describes numerous technical challenges in such patients.¹⁴ Be prepared for a dense, larger-than-expected lens nucleus. For this reason, a slightly larger capsulorhexis than average may be considered.

Because of possible preexisting loss of capsular integrity due to previous vitreous surgery, you should avoid vigorous hydrodissection and instead use hydrodelineation as an endpoint. Because vitreous is no longer present to stabilize the lens and posterior capsule, greater fluctuation of anterior chamber depth may occur, resulting in pupillary miosis. A refined and efficient phaco technique with minimal episodes of instrument removal and reinsertion is the best way to deal with this problem. Nevertheless, it is best to keep a Malyugin Ring (MicroSurgical Technology) or iris retractors available.

Be aware that the posterior capsule may be flaccid and highly mobile due to the absence of supporting vitreous humor behind it. In the event of posterior capsular rupture, the non-viscous fluid in the vitreous cavity can flow unimpeded into the anterior segment and through the phaco wound, suddenly reducing vitreous volume and increasing the risk of a suprachoroidal hemorrhage.¹⁷ Maintaining a closed system with minimal fluctuations of IOP may be appropriate. Preparation for possibly rapid surgical closure of the wound should also be made.

Postoperatively, capsular phimosis may result due to preexisting zonular laxity. For this reason, a three-piece IOL with polypropylene haptics may be preferred over a one-piece IOL with more deformable haptics. In extreme cases, insertion of a capsular tension ring may be needed.

Postvitrectomy eyes should also be considered at higher risk of retinal detachment due to preexisting retinal disease and even the vitrectomy itself. It may be best to avoid insertion of a silicone IOL in postvitrectomy eyes for reasons stated previously.

CONCLUSION

Proceeding to cataract surgery without considering the five things every cataract surgeon must know about the retina is like driving into an unfamiliar city without knowing the route. If you understand these five things, you have the best chances of arriving at the desired destination—an optimized outcome and a happy patient. ■

*Editor's note: If you wish to read a comprehensive text that covers the topic of cataract surgery in patients with retinal disease, consider obtaining the book *Cataract Surgery and Retinal Disease: Optimizing Visual Outcome*, edited and coauthored by Dr. Han, published by Bryn Mawr Communications, and available at Eyetube.net by searching in the Product Videos and Store or at eyetube.net/store/optimizing-visual-outcome-book/index.asp.*

- Coppé AM, Lapucci G. Posterior vitreous detachment and retinal detachment following cataract extraction. *Curr Opin Ophthalmol*. 2008;19(3):239-242. doi: 10.1097/ICU.0b013e3282f69c4a.
- Davis MD. Natural history of retinal breaks without detachment. *Arch Ophthalmol*. 1974;92:183-194.
- Flach AJ. The incidence, pathogenesis and treatment of cystoid macular edema following cataract surgery. *Trans Am Ophthalmol Soc*. 1998;96:557-634.
- Ray S, D'Amico DJ. Pseudophakic cystoid macular edema. *Semin Ophthalmol*. 2002;17(3-4):167-180.
- Henderson BA, Kim JY, Arment CS, et al. Clinical pseudophakic cystoid macular edema. Risk factors for development and duration after treatment. *J Cataract Refract Surg*. 2007;33(9):1550-1558.
- Oetting TA. Reduce risk of postoperative edema. *EyeNet*. July 2014;26.
- Diabetic Retinopathy Clinical Research Network Authors/Writing Committee, Baker CW, Almkhitar T, Bressler NM, et al. Macular edema after cataract surgery in eyes without preoperative central-involved diabetic macular edema. *JAMA Ophthalmol*. 2013;131(7):870-879.
- Casparis H, Lindsley K, Kuo IC, et al. Surgery for cataracts in people with age-related macular degeneration. *Cochrane Database Syst Rev*. 2012;6:CD006757. doi: 10.1002/14651858.CD006757.pub3.
- Ferris FL, Davis MD, Clemons TE, et al; Age-Related Eye Disease Study (AREDS) Research Group. A simplified severity scale for age-related macular degeneration: AREDS Report No. 18. *Arch Ophthalmol*. 2005;123(11):1570-1574.
- Scholl HP, Fleckenstein M, Fritsche LG, et al. CFH, C3 and ARMS2 are significant risk loci for susceptibility but not for disease progression of geographic atrophy due to AMD. *PLoS One*. 2009;4(10):e7418.
- Melki SA, Safar A, Martin J, et al. Potential acuity pinhole: a simple method to measure potential visual acuity in patients with cataracts, comparison to potential acuity meter. *Ophthalmology*. 1999;106(7):1262-1267.
- Singh PSJ, Han DP. Potential acuity testing. In: *Cataract Surgery and Retinal Disease: Optimizing Visual Outcome*. Ed. Han DP. Wayne PA: Bryn Mawr Communications; 2013:167-173.
- Vianya-Estopà M, Douthwaite WA, Noble BA, Elliott DB. Capabilities of potential vision test measurements, clinical evaluation in the presence of cataract or macular disease. *J Cataract Refract Surg*. 2006;32(7):1151-1160.
- Banta JL, Rosenfeld PJ. Cataract surgery and intraocular lens selection in patients with age-related macular degeneration: pearls for success. *Int Ophthalmol Clin*. 2012;52(2):73-80.
- Hollick EJ, Spalton DJ, Ursell PG, et al. The effect of polymethylmethacrylate, silicone, and polyacrylic intraocular lenses on posterior capsular opacification 3 years after cataract surgery. *Ophthalmology*. 1999;106(1):49-55.
- Dewey S. The postvitrectomy patient. In: *Cataract Surgery and Retinal Disease: Optimizing Visual Outcome*. Han DP, ed. Wayne PA: Bryn Mawr Communications; 2013:47-53.
- Moshfeghi DM, Kim BY, Kaiser PK, et al. Appositional suprachoroidal hemorrhage: a case-control study. *Am J Ophthalmol*. 2004;138(6):959-963.

Dennis P. Han, MD

- Jack A. and Elaine D. Klieger Professor at the Medical College of Wisconsin in Milwaukee
- dhan@mcw.edu
- financial disclosure: none acknowledged

Teodoro Evans, MD

- associate professor at University of Costa Rica and an associate surgeon at Clinica 20/20 and Clinica de Ojos in San José, Costa Rica
- teoevans@gmail.com
- financial disclosure: none acknowledged