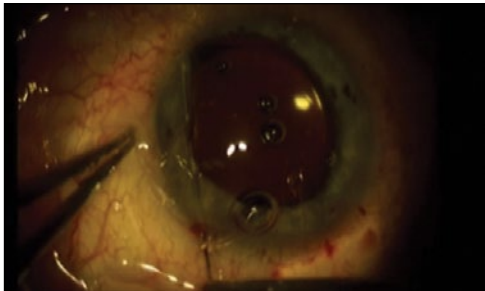


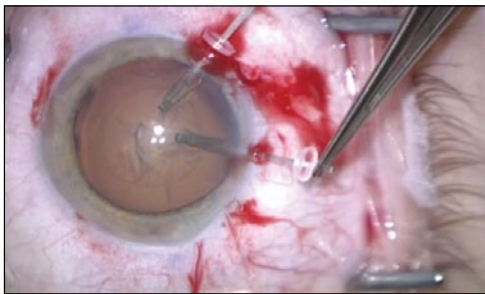
This Month's Videos on Eyetube.net



PUPILLARY CERCLAGE TECHNIQUE FOR A PERMANENTLY DILATED PUPIL

By Alan Carlson, MD

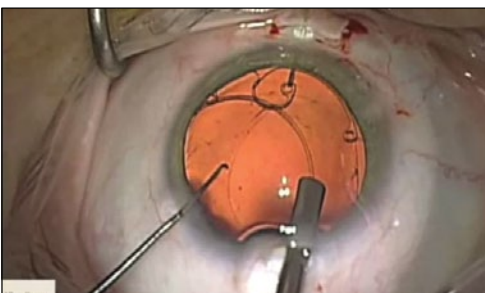Dr. Carlson combines cataract surgery with a pupillary cerclage technique for a 360° repair of a permanently dilated pupil that occurred after previous glaucoma surgery.



CAPSULAR RETRACTORS AND A MALYUGIN RING IN AN EYE WITH MARFAN SYNDROME

By David F. Chang, MD

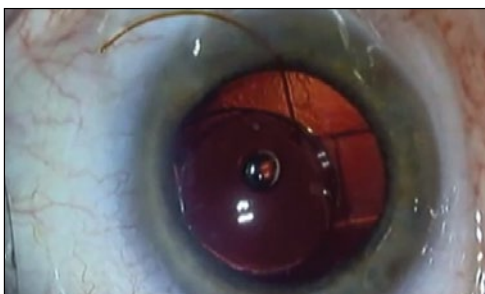Dr. Chang presents a case of a 63-year-old woman with Marfan syndrome. He creates the capsulorhexis away from the area of greatest zonular laxity and then places double-stranded–designed capsular retractors (MicroSurgical Technology) before hydrodissection and hydrodelineation. Next, he places a Malyugin Ring (MicroSurgical Technology) in the capsular bag and sutures it through a Hoffman pocket.



TRAUMATIC CATARACT WITH SEVERE ZONULAR WEAKNESS

By Allon Barsam, MD, MA, FRCOphth

In an eye with traumatic cataract and severe preexisting zonular weakness, Dr. Barsam removes the cataract and repairs the capsular bag to facilitate in-the-bag implantation of an IOL.



INSERTION OF A PIGGYBACK IOL

By Cynthia Matossian, MD

To correct a patient's 1.00 D of myopic refractive surprise, Dr. Matossian implants a STAAR AQ5010V IOL (STAAR Surgical Company) on top of a previously implanted Trulign Toric IOL (Bausch + Lomb). ■

