# Visually Significant Traumatic Cataract

BY PRIYA NARANG, MS; AMAR AGARWAL, MS, FRCS, FRCOPHTH; H. BURKHARD DICK, MD, PHD; TIM SCHULTZ, MD; RICHARD J. MACKOOL, MD; RICHARD J. MACKOOL JR, MD; AND TAL RAVIV, MD

## CASE PRESENTATION

A 50-year-old man presents with a visually significant traumatic cataract (following blunt trauma 5 years ago). About 7 clock hours of zonular loss (Figure 1) and phacodonesis are present. Small wisps of vitreous are visible at the edge of the lens. How would you approach this case?

*—Case prepared by Tal Raviv, MD.*

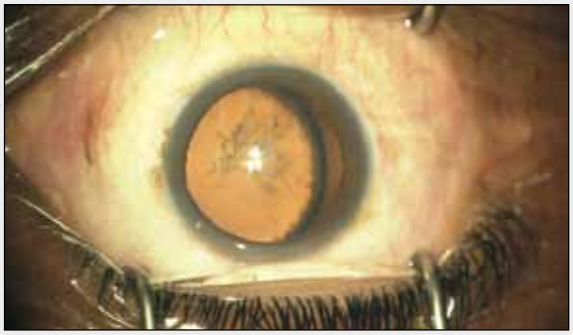

(Courtesy of Tal Raviv, MD.)

**Figure 1. A traumatic cataract with 7 clock hours of zonular loss and mild vitreous prolapse in a young patient.**

## PRIYA NARANG, MS, AND AMAR AGARWAL, MS, FRCS, FRCOPHTH

Figure 1 shows traumatic subluxation of the lens with 7 clock hours of zonular loss. The clinical picture is suggestive of phacodonesis, and small wisps of vitreous are present at the lenticular edge. The initial step involves preservation of the capsular bag with the aid of fixated capsular tension devices, even in eyes with severely subluxated traumatic cataracts.

Cases of significant zonular dehiscence benefit from a glued endocapsular ring (ECR; Epsilon USA) or a Cionni Ring for Sclera Fixation (Morcher GmbH, distributed in the United States by FCI Ophthalmics, Inc.), because they are designed to secure the capsular bag. A glued ECR allows sutureless, fibrin glue-assisted transscleral fixation of the capsular bag, which provides intra- and postoperative stability. The device has two arms that constitute the hemi-ring segment portion and are designed to sit within the fornix of the capsular bag. The scrolls engage the margin of the capsulorhexis, and the haptic anchors the entire bag transsclerally (Figure 2). Once the scrolls have engaged the capsulorhexis' margin, pulling on the exteriorized haptic centers the entire capsular bag complex. Phacoemulsification then commences. The choice and positioning of the IOL depend on the degree and location of zonular disruption. The haptics should be oriented toward the area of incompetence in order to fully expand and stabilize the capsular bag.

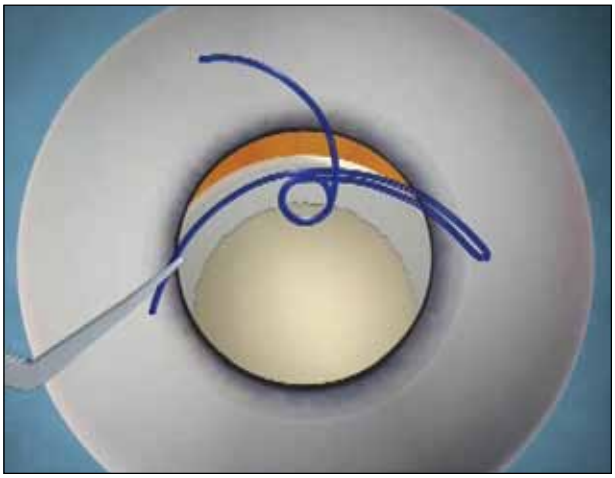

(Courtesy of Priya Narang, MS, and Amar Agarwal, MS, FRCS, FRCOphth.)

**Figure 2. The design of the glued ECR and its positioning in the direction of dialysis.**

If the capsular bag cannot be salvaged, the surgeon can use the glued IOL technique along with lensectomy and vitrectomy. A glued IOL scaffold is another option; it offers the twin advantages of a glued IOL and IOL scaffold technique. First, the surgeon performs the glued IOL procedure, after which the IOL acts as a scaffold, effectively compartmentalizing the anterior and posterior chambers. The surgeon then uses the phaco probe to remove the nuclear fragments under low flow and vacuum settings. A pars plana lensectomy with vitrec-

tomy can be considered in complicated cases involving massive subluxation, in which the nucleus often drops during surgery.

## H. BURKHARD DICK, MD, PHD, AND TIM SCHULTZ, MD

This eye could definitely benefit from laser cataract surgery using the Catalys Precision Laser System (OptiMedica Corporation). After peribulbar anesthesia, the eye is docked using the Liquid Optics Interface with a minimal increase in the IOP.[1] The Catalys automatically detects the intraocular structures, which makes for a straightforward procedure. The system allows the capsulotomy to be centered on the apex of the scanned capsule, which we would prefer to a manual continuous capsulorhexis in this case because of the excessive mobility of the lens. The wide pupil would permit a wide capsulotomy to be centered on the lens' apex after three-dimensional spectral domain optical coherence tomography compensating for the potential tilt of the lens (Figure 3). For this anterior capsulotomy, we would recommend 4 µJ of energy, a 5-mm diameter, and an incisional depth of 600 µm.

Our preference in cases like this one is full lenticular fragmentation with an additional cross-section for prechopping of the nucleus (safety zone to posterior: 500 µm). A 300-µm grid size for prefragmentation would certainly reduce the effective phaco energy to zero.[2,3] Because of the lateral location of the zonular loss, we would place the main incision at 12 o'clock to permit easy access to the lateral side for device fixation. We remove the usually free-floating capsulotomy with a microforceps (Koch; Geuder AG) after homogenously and carefully filling—but not overfilling—the anterior chamber with a dispersive ophthalmic viscosurgical device (OVD). Viscoat (Alcon Laboratories, Inc.) would secure the temporal side from vitreous.[4] An OVD like Healon5 (Abbott Medical Optics Inc.) would be another option, depending on the amount of vitreous prolapse temporally.[5]

For recentration and intermediate fixation of the capsular bag, we would insert several capsule retractors (MicroSurgical Technology) temporally and inferiorly. In our experience, the fragmented lens of a young patient can usually be aspirated bimanually with an I/A device through two paracenteses or with a phaco tip (so-called thin tip on the Stellaris PC Vision Enhancement System [Bausch + Lomb]) through the main incision under a low flow setting.

After cleaning the capsular bag, we would implant one or two capsular tension rings (CTRs; Cionni 1L for a large capsular bag or a Cionni 1G for a small capsular bag) in the capsular bag under OVD protection.[6] We prefer the 1L and 1G devices to the 2L model, because we find that two single 1L/G rings compensate for any surgical error in the placement of Prolene sutures (Ethicon Inc.). The 2L system is more demanding and does not sufficiently compensate for a surgical error. (On a 2L ring, the two eyelets are fixed, whereas two separate 1L eyelets can rotate to compensate for misalignment.)

The Hoffman technique would be very helpful for fixation of the CTR(s), because it uses a scleral pocket initiated through a peripheral clear corneal incision.[7] Full-thickness passage of a double-armed suture through the scleral pocket and conjunctiva, with subsequent retrieval of the suture ends through the external incision for tying,

(Courtesy of H. Burkhard Dick, MD, PhD.)

**Figure 3. Severe preoperative zonular dehiscence. The Catalys Precision Laser System offers automatic full treatment compensation (capsulotomy and lens fragmentation) for a tilted and displaced lens in an OVD-filled eye with a Malyugin Ring (MicroSurgical Technology) in place (axial view, red: safety zones).**

(Courtesy of H. Burkhard Dick, MD, PhD.)

**Figure 4. Intraoperative view of the same eye pictured in Figure 3 after laser pretreatment of a brunescent cataract, including intrastromal arcuate corneal incisions. In addition to the Malyugin Ring, a Capsular Retractor (MicroSurgical Technology) was placed superiorly at 1:30 o'clock to secure the capsular bag. (Note the old, avascular bleb after a trabeculectomy with mitomycin C performed elsewhere.)**

facilitates scleral fixation. This technique offers several advantages. It eliminates the need for conjunctival dissection and scleral cauterization. In addition, the scleral pocket affords a greater surface area for the placement of sutures through an ab externo or ab interno approach. Retrieval of the sutures through the external corneal incision and subsequent tying allow the suture knot to pass under the protective roof of the scleral pocket, negating the need to rotate the suture knot. Moreover, the architecture of the scleral pocket eliminates the need for sutured wound closure, which saves time. Suture retrieval and scleral fixation through a corneoscleral pocket offer a refined method for the fixation of intraocular adjunctive devices like the 1L ring system or IOLs.

After implanting an IOL with a spherical or not fully correcting aspheric optic in the capsular bag and removing the OVD, we would retrieve the capsule retractors and instill acetylcholine (Miochol-E; Bausch + Lomb) to constrict the pupil and make sure there was no vitreous in the anterior chamber.

In our hands, the described technique is minimally invasive, efficient, and effective for complex cataract cases with preexisting, large zonular defects.

## RICHARD J. MACKOOL, MD, AND RICHARD J. MACKOOL JR, MD

First, we would try to work with the area of zonular absence opposite the phaco incision to avoid vitreous prolapse through the incision. We would inject a dispersive OVD in the area of zonular dehiscence to prevent vitreous prolapse.

Next, we would paint the capsule with trypan blue. It is important not to stain the capsule before injecting viscoelastic, because trypan blue that escapes into the posterior segment will alter the red reflex and temporarily decrease postoperative visual acuity.

We would start the capsulorhexis centrally and aim for a small tear. A very loose lens may make starting the capsulorhexis difficult. If this were the case, we would insert two 30-gauge needles from opposing limbal incisions to transfix the lens and create a capsular opening. In a case such as this one, it is often necessary to place capsule retractors at various stages during the creation of the capsulorhexis in order to stabilize the lens. If we could complete the tear without the instruments, we would place them thereafter (Mackool Cataract Support System [Crestpoint Management Ltd. and Impex, Inc.] or retractors from MicroSurgical Technology).

Five retractors usually suffice. We place one every 45° in areas where the zonule is absent and every 90° where it is lax.

Next, we would perform hydrodissection followed by 360° of viscodissection. This step would fill and stabilize the capsular bag and facilitate phacoemulsification, during which we would watch for vitreous. If needed, a one-port pars plana vitrectomy with an anterior chamber maintainer in place could be performed at any time.

After completing phacoemulsification and I/A, we would inject an OVD and then a CTR into the bag. We would direct the leading portion of the device at the zone of greatest zonular laxity. The injection should be performed somewhat rapidly to minimize zonular stress. We would keep the capsule retractors in place while inserting the CTR.

Next, we would loosen the retractors in the area of zonular absence. Then, we would insert one sclera-fixated Ahmed Capsular Tension Segment (CTS; Morcher GmbH, distributed in the United States by FCI Ophthalmics, Inc.) in the area of zonular laxity to stabilize the lens. If the capsular bag remained unstable, a second Ahmed CTS opposite the first might be required.

Finally, with the capsule retractors in position, we would insert the IOL into the capsular sac, remove the retractors, and irrigate the OVD from the eye.

## WHAT I DID: TAL RAVIV, MD


I approached this case with a plan for preemptively addressing the vitreous and then suture fixating the capsule. I performed a one-port 25-gauge transconjunctival vitrectomy to clear any prolapsing vitreous, and I left the access port in place and capped in case further vitrectomy were required.

After completing the capsulorhexis, I stabilized and centered the lens, first with a capsular hook and then an Ahmed CTS on a hook in the area of zonular loss. I prolapsed the nucleus away from the fragile capsule and performed low-flow phacoemulsification using a maximum Venturi vacuum setting of 75 mm Hg on the Whitestar Signature System (Abbott Medical Optics Inc.). After bimanual I/A, I placed a traditional CTR to distribute the forces from the healthy zonules to the absent ones. Finally, I brought the Ahmed CTS centrally in viscoelastic and used an ab externo technique to suture the device to the sclera, thereby centering the bag, and implanted a single-piece IOL. ■

*Section Editor Thomas A. Oetting, MS, MD, is a clinical professor at the University of Iowa in Iowa City.*

*Section Editor Tal Raviv, MD, is an attending cornea and refractive surgeon at the New York Eye and Ear Infirmary and an assistant professor of ophthalmology at New York Medical College in Valhalla. He is a consultant to Abbott Medical Optics Inc. and is on the speakers' bureaus of Alcon Laboratories, Inc., and Baush + Lomb. Dr. Raviv may be reached at (212) 448-1005; tal.raviv@nylasereye.com.*

*Section Editor Audrey R. Talley Rostov, MD, is in private practice with Northwest Eye Surgeons, PC, in Seattle.*

*Amar Agarwal, MS, FRCS, FRCOphth, is professor and chairman at Dr. Agarwal's Eye Hospital and Eye Research Centre in Chennai, India. He acknowledged no financial interest in the products or companies he mentioned. Dr. Agarwal may be reached at + 91 44 2811 6233; dragarwal@vsnl.com.*

*H. Burkhard Dick, MD, PhD, is professor, chairman, and director of the Center for Vision Science at Ruhr University in Bochum, Germany. He is a paid consultant to and a member of the medical advisory board of OptiMedica Corporation. Dr. Dick may be reached at +49 234 299 310; burkhard.dick@kk-bochum.de.*

*Richard J. Mackool, MD, is the director of the Mackool Eye Institute and Laser Center in Astoria, New York. He is a consultant to Alcon Laboratories, Inc., and holds a financial interest in the Mackool Cataract Support System and Capsule Retractors. Dr. Mackool may be reached at (718) 728-3400, ext 256; mackooleye@aol.com.*

*Richard J. Mackool Jr, MD, is the assistant director of the Mackool Eye Institute and Laser Center in Astoria, New York. He acknowledged no financial interest in the products or companies he mentioned. Dr. Mackool may be reached at (718) 728-3400, ext. 256; mackooleye@aol.com.*

*Priya Narang, MS, is chief consultant at Narang Eye Care & Laser Centre in Ahmedabad, Gujarat, India. She acknowledged no financial interest in the products or companies she mentioned. Dr. Narang may be reached at narangpriya19@gmail.com.*

*Tim Schultz, MD, is a scientific coworker at the Center for Vision Science at Ruhr University in Bochum, Germany. He acknowledged no financial interest in the products or companies he mentioned. Dr. Schultz may be reached at +49 234 299 3101; tim.schultz@kk-bohum.de.*

1. Schultz T, Conrad-Hengerer I, Hengerer FH, Dick HB. Intraocular pressure variation during femtosecond laser-assisted cataract surgery using a fluid-filled interface. *J Cataract Refract Surg*. 2013;39(1):22–27.
2. Conrad-Hengerer I, Hengerer FH, Schultz T, Dick HB. Effect of femtosecond laser fragmentation on effective phacoemulsification time in cataract surgery. *J Refract Surg*. 2012;28(12):879–883.
3. Conrad-Hengerer I, Hengerer FH, Schultz T, Dick HB. Effect of femtosecond laser fragmentation of the nucleus with different softening grid sizes on effective phaco time in cataract surgery. *J Cataract Refract Surg*. 2012;38(11):1888–1894.
4. Dick HB, Schwenn O. *Viscoelastics in Ophthalmic Surgery*. New York, NY: Springer; 2000.
5. Dick HB, Krummenauer F, Augustin AJ, et al. Healon5 viscoadaptive formulation: comparison to Healon and Healon GV. *J Cataract Refract Surg*. 2001;27(2):320–326.
6. Cionni RJ, Osher RH, Marques DM, et al. Modified capsular tension ring for patients with congenital loss of zonular support. *J Cataract Refract Surg*. 2003;29(9):1668–1673.
7. Hoffman RS, Fine IH, Packer M. Scleral fixation without conjunctival dissection. *J Cataract Refract Surg*. 2006;32(11):1907–1912.