A Dense Brunescent Cataract With a Thick Fibrotic Membrane

One surgeon's methodic approach to a complicated case.

BY ROBERT J. WEINSTOCK, MD

An 88-year-old man presented for a routine examination. He was an extremely poor historian and lived in a remote area of Florida. When his daughter visited, she noticed he was having trouble seeing and functioning. The examination revealed an extremely dense 4+ brunescent cataract in both of his eyes. One of the cataracts had a thick, white fibrotic membrane attached to the anterior capsule (Figure 1). His best vision in both eyes was count fingers at 3 feet. The retina was not viewable through the cataracts, but ultrasound revealed no evidence of retinal detachment. Based on the examination, I knew I was in for a challenging time in the OR.

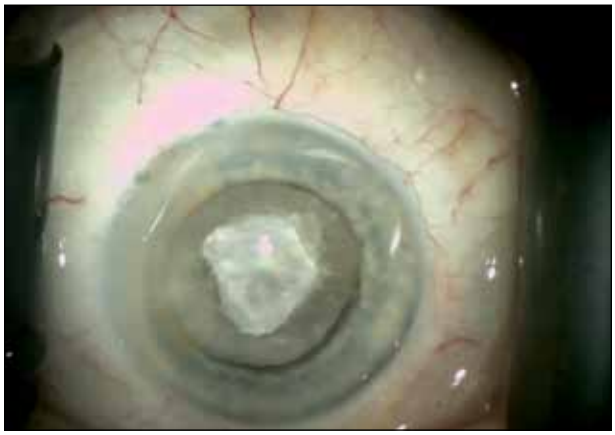

Figure 1. A dense 4+ brunescent cataract with a thick white fibrotic membrane.

PREPARATIONS

I scheduled the case as my last one of the day and blocked 30 minutes for the procedure in anticipation of complications. For challenging cases such as this one, I instruct the OR team to have ready iris retractors, capsular tension rings, trypan blue for staining the anterior capsule, a bimanual and a coaxial vitrectomy pack, acetylcholine chloride (Miochol-E; Bausch + Lomb), extra individually wrapped Kuglen or Sinskey hooks, sutures, a lens loop, and a selection of anterior chamber and sulcus IOLs. I find that these advance preparations tremendously ease my anxiety and stress during complicated cases.

SURGICAL COURSE

Anesthesia

The first challenge I encountered in the OR was obtaining cooperation from the patient due to his impaired mental status and senile dementia. I therefore decided to perform a retrobulbar block, an option I always consider for tough cases that may require additional surgical time. For ophthalmologists who are used to topical anesthesia, when doing a rare block, it is important to apply some form of pressure via a pinky ball or honan balloon after the block to soften the eye and decompress the vitreous. If pressure is not applied to the eye, the anterior chamber can shallow, and posterior pressure will build up, making the case even more difficult.

Staining the Anterior Capsule

Due to the presence of the white fibrotic membrane, I immediately filled the anterior chamber with air after I created the first incision. Next, I injected trypan blue underneath the air to stain the anterior capsule. It is an excellent idea to establish routines for cataract surgery, but when a surgeon is faced with an unusual case, routines can be the enemy. I have had cases in which the scrub technician automatically passed me viscoelastic after I made the incisions,

and, had trypan blue been needed, the viscoelastic would have impaired the agent's ability to stain the anterior capsule. Fortunately, in this particular case, I did not make the mistake of injecting the viscoelastic before the trypan blue.

After staining the anterior capsule with trypan blue, I usually prefer to inject a cohesive viscoelastic, which squeezes the air and the residual dye out of the anterior chamber so that the capsule can be well visualized. I initiate and complete all of my capsulorhexes—in routine or complicated cases—with a microcapsulorhexis forceps (Bausch + Lomb Storz Instruments). In this particular case, the capsulorhexis was challenging because of the fibrotic membrane, so I attempted to stay outside the membrane and to target healthy capsule, where I would be able to perform a more normal anterior capsulotomy. Attempting to puncture a fibrotic membrane on the anterior capsule can be challenging and even lead to a tear due to the stress and force that is required.

Protecting the Endothelium

The next challenge occurred when I realized that the 4+ brunescent density of this cataract was going to require a significant amount of phaco energy and time. I decided to coat the endothelium multiple times during the case with a dispersive viscoelastic. I have had cases such as this one in which even three or four applications of viscoelastic were needed throughout the procedure to protect the endothelium.

Removal of Nuclear Material

eyetube.net

eyetube.net/video/pevop

Partway through the nuclear disassembly, I noticed a very bright red reflex, an immediate sign that a break in the posterior capsule might have occurred, creating a potential site for nuclear particles to fall into the vitreous cavity. Because everything was stable, I did not remove any instruments from the eye but instead continued irrigation so that I could observe the situation. In the past, I have made the mistake of immediately removing the instruments from the eye, which usually shallows the anterior chamber and splits a posterior capsular tear if one is present.

Fortunately, I was able to remove all of the nuclear material without any particles falling back into the posterior segment. Part of the reason for this success was that I used a bimanual technique, which separates irrigation from aspiration and phacoemulsification and allows for a more controlled fluid pattern inside the anterior chamber (Figure 2). It also helped that I did not completely break up the nucleus into multiple quadrants. Instead, I tried to maintain chunks of cataract as large as possible and

Figure 2. Using a bimanual phaco technique, the surgeon sculpts a groove that allows the lens to be rotated 90º. The irrigation chopper and a sleeveless phaco needle are used to chop the nucleus in half.

keep them on the phaco needle at all times so that none would disappear from view and fall posteriorly. This technique also prevented vitreous from becoming incarcerated in the phaco needle. Once the nuclear material was cleared from the phaco tip, I stopped aspiration so that none of the vitreous was pulled up into the phaco needle.

Vitrectomy

After the nucleus was removed, the OR technician set up the bimanual vitrectomy handpiece, and I proceeded with an anterior victrectomy. First, I placed the victrectomy probe into the anterior chamber to remove any vitreous. Next, I moved the vitrectomy probe down to the level of the capsule and into the capsular plane and finally through the hole in the posterior capsule and into the anterior vitreous to remove any vitreous material that was prolapsing forward. I usually perform the vitrectomy before removing the cortical material. If these steps are attempted in reverse, the cortical material cannot be removed easily, and the vitreous clogs the aspiration port, which can put unnecessary traction on the vitreous that can transfer to the retina.

Implantation of an IOL

After a thorough vitrectomy, I returned to bimanual I/A and removed the cortex that was hiding underneath the iris and in the far sulcus areas of the remaining capsule. I chose to implant Bausch + Lomb's LI61AO three-piece IOL, because the cartridge of this lens is well suited for a controlled delivery into the sulcus space. It delivers the lens in a planar fashion so that the leading haptic can be placed into the sulcus without the IOL's flipping or turning or the haptic's flipping down and prolapsing into the vitreous cavity. I usually leave the trailing haptic in the anterior

chamber or the conjunctiva, and with a Kuglen or Sinskey hook, I gently tuck it into the sulcus space under the iris. I instill acetylcholine chloride to make sure that the pupil comes down over the optic of the lens, and sometimes, if the anterior capsule is intact and slightly smaller than the IOL's optic, I will tuck the lens' optic underneath the rim of the anterior capsule to stabilize its position.

Completion of the Case

Acetylcholine chloride usually reveals if there is any pupillary peaking or areas of vitreous prolapse. If the IOL does not center easily, it signifies that vitreous is displacing the optic and coming around the lens into the anterior chamber. If this occurs, I usually perform a further vitrectomy underneath the lens and on top of the implant to remove any vitreous. I also check the incision with a Weck-Cel sponge (Beaver-Visitec International, Inc.) to make sure no vitreous is present. Once I find that the pupil is small and round and covers the optic and that no vitreous is evident in the anterior chamber, I place a suture to maintain the anterior chamber's stability and reduce the incidence of its collapse and vitreous prolapse. I also find it is helpful to use triamcinalone to stain any vitreous in the anterior segment if I am concerned that some remains.

Fortunately, this particular case ended well despite an unintended tear in the posterior capsule. The patient's vision and quality of life improved dramatically. I have tremendous respect for cataract surgeons in parts of the world where cataracts of this severity are dealt with on a daily basis.

CLOSING THOUGHTS

The best advice I can give fellow surgeons on handling complicated cases is to remain calm and to think through the surgical steps. It is always better to take the time needed to clean up the eye properly in the OR instead of hurrying to complete the case. This strategy maximizes the patient's chance for a good visual outcome, avoids a second trip to the OR, and prevents an unsightly image at the slit lamp in the future. Watching complicated cases on Eyetube.net or in video journals is one of the best ways to learn how to handle these tough situations. I also hear from colleagues that medical missions are an excellent way for surgeons to get hands-on experience and help patients in need. This is something I look forward to doing soon. ■

Robert J. Weinstock, MD, is a cataract and refractive surgeon in practice at The Eye Institute of West Florida in Largo, Florida. He is a consultant to Alcon Laboratories, Inc., and Bausch + Lomb. Dr. Weinstock may be reached at (727) 585-6644; rjweinstock@yahoo.com.