Pseudoexfoliation: Small Pupil, Loose Zonules

Techniques and technologies to achieve a successful outcome.

BY JASON JONES, MD

Approximately 20% of my cataract patients have pseudoexfoliation (PXF) and often present with poor pupillary dilation and/or zonular instability. Many of them go through surgery without complication, but severely affected patients present a particular challenge. This article describes how I handled a recent difficult case involving the right eye of a woman in her late 60s with PXF.

THE POORLY DILATED PUPIL

Because the patient's pupil did not dilate well despite pharmacologic and viscoelastic devices, mechanical dilation was indicated. In such situations, I commonly employ the 6-mm Malyugin Ring (MicroSurgical Technology). I used a two-handed insertion technique, with a spatula guiding the positioning of three of the four coils onto the pupil's edge; the subincisional coil I placed with a Kuglen hook.

eyetube.net
eyetube.net/?v=rorod

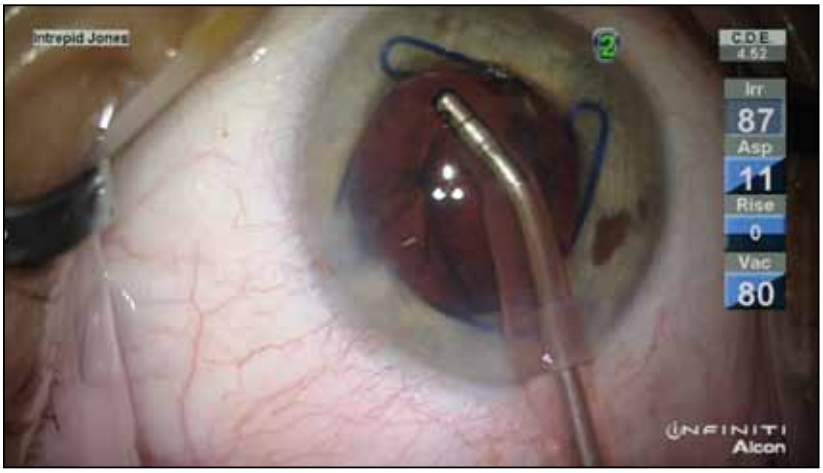

Figure. In an eye with severe zonular laxity, cortical cleanup represents the greatest challenge, because essentially nothing is holding back the capsule.

THE LAX ZONULES

The first indication of loose zonules often comes with the ophthalmic viscosurgical device's (OVD) instillation. The movement of the lens caused by distention of the anterior chamber has a quality that one can judge, and the zonules were fairly loose here. My suspicion was confirmed during the Malyugin Ring's placement and again at the puncturing of the anterior capsule, when wrinkles appeared in a pattern of asymmetric radiation at the start of the capsulorhexis. The continuous capsular opening proceeded routinely despite the zonular laxity. I informed my staff to have at the ready items such as alternate IOLs, extra OVD, a capsular tension ring

> "The biggest challenge with lax zonules is cortical removal. Simply put, there is not much holding back the capsule, and the goal is to provide outward tension on it."

(CTR), and capsule hooks.

Adequate hydrodissection is crucial, and I persisted until a posterior fluid wave appeared. To minimize zonular stress, I settled for the ability to rotate the nucleus (rather than easy and free rotation) before proceeding to phacoemulsification. I used a vertical chopping technique and made sure that the cleavage propagated through the posterior plate. Usually, the lens rotates more easily at this stage. Once I began to evacuate material, the capsular bag started to collapse, and rotational ease diminished. Careful extraction with assistance from my second instrument reduced the nucleus. The fully cleaved segments readily followed out of the bag. When the last fragment remained, I used a dispersive OVD to tamponade the capsular bag and reduce any surge that might occur in the setting of an extremely floppy capsule. Before removing the phaco tip, I exchanged the saline for a dispersive OVD.

THE REAL CHALLENGE: CORTICAL REMOVAL

The biggest challenge with lax zonules is cortical removal. Simply put, there is not much holding back the capsule, and the goal is to provide outward tension on it (Figure). A large syringe of Healon EndoCoat (Abbott Medical Optics Inc.) provided more than enough OVD, even though I replenished it repeatedly. In regions of extreme flaccidity, I grasped the anterior cortex with I/A and simultaneously viscodissected while aspirating cortex from the capsule. This technique proved useful with a posterior handle as well. The remaining cortex was removed with a combination of mobilization using a Terry squeegee, viscodissection, and dry aspiration using a 27-gauge cannula on a saline-filled syringe. I placed a CTR under a cohesive OVD tamponade. I introduced the leading eyelet into the 3-o'clock capsule that functioned as a pivot point to load the ring into the nasal capsule. Using a forceps, I delivered the trailing eyelet into the bag.

THE NEXT HURDLE: CHOICE AND PLACEMENT OF THE IOL

Although I have inserted a single-piece acrylic lens into the bag in these situations, I believe better stability is achieved with a technique championed by David Chang, MD: optic capture through the anterior capsulorhexis of a sulcus-fixated three-piece IOL. This approach stabilizes the capsular bag complex, because the haptics lie on the ciliary body and the capsular bag is tethered to the IOL via optic capture.

I expanded the sulcus with a cohesive OVD and delivered the three-piece lens into the ciliary sulcus with an injector. Optic capture was readily achieved, but the lens did not position well. I rotated the IOL slightly, and it centered correctly. Only later when reviewing the video did I realize that the trailing haptic caught on the left coil of the Malyugin Ring and that the rotation relieved this hang-up. I aspirated OVD in front of the IOL and balloted the lens to encourage OVD to exit the capsular bag. I hydrated the incisions and found them to be watertight. The IOL was nicely centered with evidence of optic capture from the capsular overlap configuration.

POSTOPERATIVE COURSE

Patients such as this one need to be observed for elevated IOP, and I prescribed oral acetazolamide prophylactically. Additionally, given the optic capture, the capsular bag can distend from OVD sequestration. If needed, a small YAG puncture can relieve trapped viscoelastic but was unnecessary here. Most important, the lens' stability must be monitored in the short and long term. Thus far, this patient has done very well. Her IOP normalized soon after surgery, and no pseudophacodonesis is yet apparent.

At present, I do not have extensive experience with this IOL implantation technique, but the sulcus placement of a three-piece lens with optic capture appears to be more stable than bag fixation alone in the presence of marked zonular laxity. Time will tell. The CTR may reduce capsular contraction when the bag does not have an IOL inside it and will also provide a scaffold to sclerally suture fixate the IOL-bag complex if subluxation occurs. ■

Jason Jones, MD, is medical director of Jones Eye Clinic in Sioux City, Iowa, and Sioux Falls, South Dakota. He acknowledged no financial interest in the products or companies mentioned herein. Dr. Jones may be reached at (712) 239-3937; jasonjonesmd@mac.com.