

Dislocated PMMA IOL and Capsular Bag in Eye With Pseudoexfoliation

BY ALAN S. CRANDALL, MD; DEVIN M. GATTEY, MD; HOWARD V. GIMBEL, MD;
AND THOMAS A. OETTING, MS, MD

CASE PRESENTATION

An 80-year-old woman presents after a sudden decrease in the vision in her right eye. She underwent cataract surgery 15 years ago, with the placement of a single-piece PMMA IOL in the bag. She has a history of pseudoexfoliation (PXF) and ocular hypertension, which is controlled by a single agent. The patient has excellent vision in her left eye.

The figure shows the anterior segment of her right eye and the inferior subluxation of the IOL and bag. When the patient is supine, the IOL stays just behind the iris plane and does not tilt or move more posteriorly. She complains of double images, glare, and generally poor vision in this eye. How would you proceed?

—Case prepared by Thomas A. Oetting, MS, MD

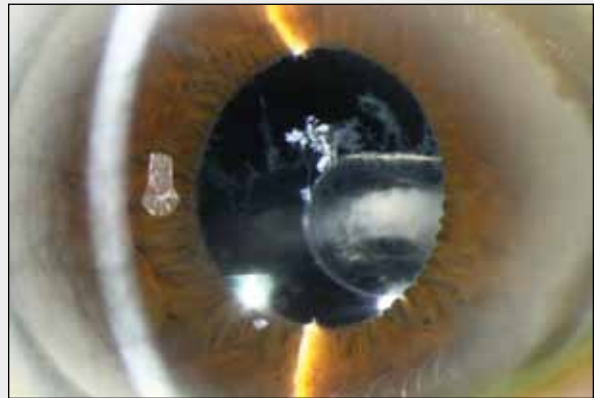


Figure. A slit-lamp examination reveals PXF and a subluxated IOL in the capsular bag.

ALAN S. CRANDALL, MD

This is a classic presentation of spontaneous subluxation of the IOL-capsule complex in a patient with PXF. Since our original publication on this subject,¹ my colleagues and I have collected hundreds of cases and found all types of IOL design and material implicated.

The PXF material on the capsule and a Soemmering ring of lens protein are visible in the figure. Based on the examination findings and because the lens is a single-piece design made of PMMA, the bag-IOL complex is not likely to dislocate completely. (It would be important to lay the patient back to ensure that an anterior approach will be possible.) The first option would be to remove the complex and place a secondary lens, which would require a large incision. Alternatively, the surgeon could fixate the lens to the iris or sclera. I prefer to perform fixation through small incisions, and with this type of lens, I favor scleral fixation with either a Hoffman pocket² or an ab externo technique, which I will describe.

Once the position of the haptics is known, two perito-

mies are made 180° apart and 2 mm posterior to the limbus. The surgeon makes two marks about 2 to 3 mm apart. Using a 23-gauge microvitreal blade, he or she opens four sites (blade visualized to ensure correct anatomy). Through a clear corneal stab incision, a viscoelastic is injected, with the surgeon careful not to use too much. He or she uses a micrograsper (ASICO LLC or MicroSurgical Technology [MST]) to stabilize the complex and punctures it near the haptic with a 25-gauge ILM grasper (Grieshaber; Alcon Laboratories, Inc.). He or she then grasps an 8-0 GoreTex suture (W. L. Gore & Associates, Inc.), pulls it out of one of the scleral sites, and uses a lasso technique. This process is repeated through the other three sites. The eye is pressurized with a chamber maintainer, and the sutures are tied under minimal tension.³

DEVIN M. GATTEY, MD

The primary decision in this case is whether to try to retain the IOL or exchange it for a new one. Removal necessitates the creation of a large incision to

“Remaining zonular attachment to the eye wall is fragile at best, and the vitreous is likely to be quite liquid.”

—*Devin M. Gattley, MD*

accommodate the rigid IOL, explantation of the phimotic lens-bag complex, and insertion of a secondary IOL. To free up the lens-bag complex, I would use an anterior vitrector via an anterior and/or pars plana approach. I would instill triamcinolone acetonide (Triesence; Alcon Laboratories, Inc.) to assist my visualization of the vitreous. The typically small pupil in this case may necessitate the placement of iris hooks or a pupillary expansion device prior to this maneuver. With the large incision already created, it would be simplest to implant an ACIOL, although doing so might exacerbate the patient’s ocular hypertension. An alternative approach that would avoid a large incision by retaining the current IOL involves scleral fixation by passing a suture through the capsular bag and around each haptic. (Garry Condon, MD, presents an excellent example of this technique on Eyetube.net.)

Whatever the approach, remaining zonular attachment to the eye wall is fragile at best, and the vitreous is likely to be quite liquid. For these reasons, the surgeon should be prepared for the lens-bag complex to drop into the posterior vitreous. The surgical plan should therefore include the involvement of a retina colleague if the initial strategy goes awry.

HOWARD V. GIMBEL, MD

In the figure, it appears that the zonules are all missing superiorly, so they must be nearly absent or very weak everywhere. The Soemmering ring is quite thick, with a crescent of white cortex. At the pupil’s edge, there appears to be a fibrotic continuous curvilinear capsulorhexis, and the surgeon will have to assess the degree and completeness of the circle of fibrosis after placing iris hooks at the start of surgery.

My approach would be first to try to fixate the bag-IOL complex to the sclera with three fixation sutures placed 60° apart. This technique could only be used, however, if there were enough circular fibrosis in the capsular membrane around the capsulorhexis to allow suture passes through or around the fibrosis to fix the bag to the sclera. Other options include iris suture fixation or transscleral fixation of the IOL’s haptics, but the thick Soemmering ring would make them challenging.

The scleral fixation sutures could be placed via Hoffman’s scleral tunnel incisions,² thereby preserving the conjunctiva. If the bag-IOL complex could not be fixated to the sclera, an alternative would be to make a large limbal incision, away from any previous incision; remove the IOL en bloc; insert an ACIOL, after an anterior vitrectomy if necessary; instill a miotic; and perform a peripheral iridectomy with the vitreous cutter on I/A cutting mode.

THOMAS A. OETTING, MS, MD: HOW THE CASE WAS MANAGED

We decided to try to keep the existing IOL and secure it with sutures. We used the sliding internal knot technique that we published a few months ago.⁴ Using an iris hook, we exposed the haptic by retracting the iris.

With the sliding internal knot technique, the surgeon uses 9–0 double-armed Prolene with a long, curved CTC-6L needle (Ethicon Inc.) to secure each of the haptics 180° apart to the sclera. First, he or she creates two peritomies 180° across from each other. Using an external approach, one of the arms of the needles is placed through the sclera, under the haptic, through the capsular bag, under the iris, and out where convenient. The other needle is placed in a similar fashion but above the haptic, and it simply passes over the haptic and IOL, under the iris, and out where convenient. Then, the suture is tied with a sliding knot, as described by Sipeser, inside the eye to secure the haptic and capsule to the sclera. The surgeon uses a microforceps (eg, MST Duet) to cinch down the knot and microscissors (eg, MST Duet) to cut the suture at the knot.

We used this technique on both sides. A video with beautiful drawings by Alton Szeto shows a similar case on our blog on cataract surgery at <http://cataractsurgeryforgreenhorns.blogspot.com/2011/12/slik-technique.html#/2011/12/slik-technique.html>. ■

Section Editor Bonnie A. Henderson, MD, is a partner in Ophthalmic Consultants of Boston and an assistant clinical professor at Harvard Medical School.

Section Editor Thomas A. Oetting, MS, MD, is a clinical professor at the University of Iowa in Iowa City. He acknowledged no financial interest in the products or companies he mentioned. Dr. Oetting



WATCH IT NOW ON EYETUBE.NET

Using your smartphone, photograph the QR code to watch the video on Eyetube. If you do not have a QR reader on your phone, you can download one at www.getscanlife.com.

Direct link to Dr. Condon’s video:
<http://eyetube.net/?v=bropro>



may be reached at (319) 384-9958; thomas-oetting@uiowa.edu.

Section Editor Tal Raviv, MD, is an attending cornea and refractive surgeon at the New York Eye and Ear Infirmary and an assistant professor of ophthalmology at New York Medical College in Valhalla.

Alan S. Crandall, MD, is a professor, the senior vice chair of ophthalmology and visual sciences, and the director of glaucoma and cataract for the John A. Moran Eye Center at the University of Utah in Salt Lake City. He is a consultant to Alcon Laboratories, Inc.; ASICO LLC; and Mastel Precision, Inc. Dr. Crandall may be reached at (801) 585-3071; alan.crandall@hsc.utah.edu.



Devin M. Gattey, MD, is a clinical associate professor of ophthalmology, chief of the Comprehensive Division, and associate ophthalmology residency program director with the Casey Eye Institute at Oregon Health & Science University in Portland. He acknowledged no financial interest in the product or company he mentioned. Dr. Gattey may be reached at (503) 494-6838.



Howard V. Gimbel, MD, is a professor in and the chairman of the Department of Ophthalmology at Loma Linda University in Loma Linda, California. He is also medical director and senior surgeon at the Gimbel Eye Center in Calgary, Alberta, Canada. Dr. Gimbel may be reached at (909) 558-2154 or (403) 286-3022; hvgimbel@gimbel.com.



1. Jehan FS, Marmalis N, Crandall AS. Spontaneous late dislocation of intraocular lens within the capsular bag in pseudoexfoliation patients. *Ophthalmology*. 2001;108(10):1727-1731.
2. Hoffman RS, Fine H, Packer M, Rozenberg I. Scleral fixation using suture retrieval through a scleral tunnel. *J Cataract Refract Surg*. 2006;32:1259-1263.
3. Slade DS, Crandall AS, Gianni R, Hater M. Novel technique of ab externo scleral fixation of intraocular lenses. *J Cataract Refract Surg*. In press.
4. Oetting TA, Tsui JY, Szeto AT. Sliding internal knot technique for late in-the-bag intraocular lens decentration. *J Cataract Refract Surg*. 2011;37(5):810-813.