

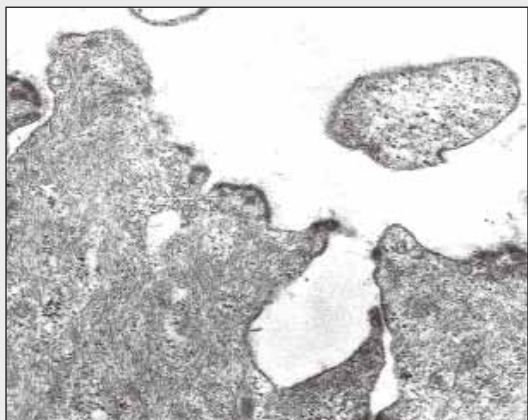
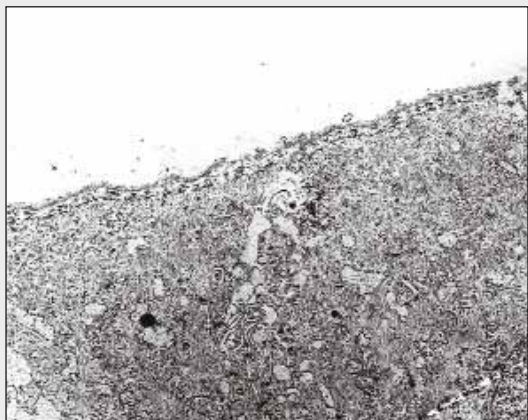
# Cataract & Refractive Surgery

## TODAY

May 2005

## Epi-LASIK: A Roundtable Discussion

Thought leaders in vision correction discuss their experience with Epi-LASIK and the procedure's application in clinical practice.



Histopathological images show the physiological differences between the Epi-LASIK (top) and LASEK (bottom) procedures.

**Ioannis Pallikaris, MD, PhD:** My research on the Norwood EyeCare Epikeratome has established that the short-term viability of the cells of the epithelial sheet separated by Epi-LASIK is far greater than those separated with alcohol.

**Marguerite B. McDonald, MD, FACS:** Because Epi-LASIK does not cut the corneal stroma, it avoids most of the complications associated with laser vision correction.

**Warren D. Cross, MD:** Epi-LASIK is extremely predictable. I feel it is the best procedure on the market, because its safety profile for the patient is truly remarkable.

**Daniel S. Durrie, MD:** Epi-LASIK protects the cornea better than PRK and has the potential for faster epithelial healing and less haze compared with PRK.

**Massimo Camellin, MD:** Epi-LASIK has an advantage in wavefront-guided procedures, because it respects the biomechanics of the cornea and does not introduce variations into its shape.

**Paolo Vinciguerra, MD:** Epi-LASIK has improved and expanded my perspective on surface ablation through its (1) safety, (2) preservation of corneal tissue, and (3) lack of cutting.

**Vikentia Katsanevaki, MD, PhD:** When LASIK and Epi-LASIK patients were matched by their attempted correction and treatment zone and compared, Epi-LASIK patients returned to preoperative sensitivity levels by 3 months and remained at that level. In contrast, LASIK patients' sensitivity began to approach preoperative levels at 3 months but had declined significantly by 6 months.

**Mark Volpicelli, MD:** Compared with the other options, the Norwood EyeCare Epikeratome has good "surgeon feel"; it is light and ergonomic.

**Robert L. Kantor, MD:** Because of its safety factor, I feel that Epi-LASIK should replace LASIK almost completely in my practice.

# Epi-LASIK: A Roundtable Discussion

Thought leaders in vision correction weigh in.

*Epi-LASIK (epi-laser in situ keratomileusis) refers to an advanced refractive surgical approach for epithelial separation by means of a mechanical device known as an epikeratome. With this technique, epithelial separation is accomplished using an instrument that was initially designed at the University of Crete by Ioannis Pallikaris, MD, PhD, and that operates in a manner similar to a microkeratome.*

*Epi-LASIK is a surgical modality for the advanced surface ablation treatment of myopia and hyperopia. Prior to photoablation, the corneal epithelium is gently separated by means of a customized epikeratome that features a unique, non-sharp separator. Separation is created mechanically without the use of alcohol. Once the photoablation treatment is accomplished, the epithelial sheet is replaced onto the ablated cornea and protected by a bandage contact lens.*

## WHAT IS EPI-LASIK, AND WHY IS THERE SUCH STRONG INTEREST IN IT?

**Dr. Pallikaris:** In 2000, we improved on the LASIK and PRK procedures with a new procedure called *Epi-LASIK*, which eliminates the need to cut the corneal stroma or use alcohol. Instead of a microkeratome, the surgeon uses a unique instrument called an *epikeratome* (Figure 1) to separate a sheet of epithelium only along a natural cleavage point (above Bowman's layer and below the basement membrane) before applying the laser ablation. After the ablation, the surgeon lays the thin epithelial sheet back into place.

**Dr. McDonald:** Because Epi-LASIK does not cut the corneal stroma, it avoids most of the complications associated with laser vision correction, including epithelial ingrowth, striae, interface infections, diffuse lamellar keratitis, etc. Epithelial separators (Figure 2) travel across the eye more slowly than microkeratomers, thus providing better control over the separation.

**Dr. Vinciguerra:** Epi-LASIK has improved and expanded my perspective on surface ablation through its (1)

safety, (2) preservation of corneal tissue, and (3) lack of cutting (but instead separation of the epithelium with a non-sharp blade).

**Dr. Durrie:** Epi-LASIK offers advantages over PRK. The majority of physicians practicing surface ablation agree that this is an improved method, because it protects the cornea better than PRK and has the potential for faster epithelial healing and less haze compared with PRK.

**Dr. Camellin:** LASIK still has some unavoidable risks. Epi-LASIK provides all surgeons the opportunity to get a healthy epithelial sheet. The great advantage is to create the epithelial sheet in an easy manner.

**Dr. Cross:** I have performed Epi-LASIK on more than 150 eyes over the last 15 to 16 months, a figure that constitutes 10% to 20% percent of my practice. Epi-LASIK is extremely predictable. I feel it is the best procedure on the market, because its safety profile for the patient is truly remarkable. With Epi-LASIK, you can almost do no harm. It is safe, and ultimately the patients do extremely well.



Figure 1. The Norwood EyeCare Epikeratome handpiece.



Figure 2. The Norwood EyeCare Epi-LASIK Separator.

**Dr. Kantor:** So many patients have Orbscans (Bausch & Lomb, Rochester, NY) that show a “little irregularity” or forme fruste keratoconus on which I would not perform LASIK. Now I can perform Epi-LASIK on these patients with confidence.

**Dr. McDonald:** Because Epi-LASIK separates the epithelial layer along a natural cleavage plane, the surgeon has injured the cells but has not killed them immediately, as in PRK. The epithelial cells live for an additional 4 to 5 days, as the stroma immediately begins to heal. Our operating theory is that, when the epithelial cell membranes finally become permeable and begin to leak cytokines, the stroma has long since begun uneventful healing and is much less vulnerable to their adverse influence. Of course, the surgeon applies a contact lens at the end of the procedure, but the separated sheet protects the healing surface for the first few postoperative days to facilitate better and faster healing than with PRK.

**Dr. Pallikaris:** My data from Crete show that patients experience less pain and recover faster with Epi-LASIK than with PRK. My research on the Norwood EyeCare Epikeratome (Norwood EyeCare, Inc., Duluth, Georgia) has established that the short-term viability of the cells of the epithelial sheet separated by Epi-LASIK is far greater than for those separated with alcohol. This is important, because the epithelial sheet may act as a mechanical barrier between the ablated stroma and the tear film and thus aid the corneal healing response. With Epi-LASIK, the epithelium will still need to regenerate in 3 to 4 days, but the separated sheet will protect the healing surface for the first few postoperative days

and thereby enable faster wound healing and lead to a better quality of vision.

**Dr. McDonald:** As I have mentioned, the epithelial sheet finally dies 4 to 5 days after the surgery, but by the time these cells release their cytokines, the stroma has long since passed its moment of vulnerability, so that stromal healing has a greater chance of proceeding without haze and regression. Many experts, including Professor John Marshall of London, theorize that separating these two events in time—the death of the epithelial sheet and the surgical insult to the stroma—will provide better clinical results for surface ablation.

#### WHY IS IT IMPORTANT TO PRESERVE THE INTEGRITY OF THE CORNEAL TISSUE?

**Dr. McDonald:** When the epithelial cells are crushed, as in PRK, the cell membranes release cytokines that stimulate a cascade of inflammatory reactions, which can lead to haze and regression. Also, as in both LASEK and PRK, Bowman's layer—a thin, transparent anterior corneal membrane—is removed centrally in Epi-LASIK, although it is still intact peripherally. Epi-LASIK differs from other surgical procedures in that it accurately separates the epithelial sheet above Bowman's layer but below the basement membrane.

The function of Bowman's layer is unknown; most mammals do not have one. This densely packed layer of collagen is thought by some researchers to be part of the basement membrane of the corneal epithelium. The basement membrane is thought to provide the support that preserves the integrity of the entire epithelium, and its maintenance is associated with more rapid healing.

**Dr. Durrie:** With an intact basement layer, fewer signals are sent to the keratocytes. Because PRK removes the epithelium, signals reach the cornea to stimulate wound healing and pain. Leaving the epithelium on the eye, including the basement membrane, blocks some of those inflammatory pathways. In a sense, Epi-LASIK leaves a bandage on the eye instead of an open sore.

**Dr. Pallikaris:** Research I conducted at the Vardinoyannion Eye Institute of Crete, University of Crete, with a colleague of mine, Vikentia J. Katsanevaki, MD, has formed the basis of a growing body of knowledge about how Epi-LASIK preserves the tissue's integrity.

In one study, we compared the effect of mechanical separation via the Norwood EyeCare Epikeratome with

alcohol-assisted excision on the histological ultrastructure of epithelial disks from the corneas of 10 patients.<sup>1</sup> We found that Epi-LASIK did not affect the normal epithelial cell morphology and was less invasive to epithelial integrity. Transmission electron microscopy showed that when the epithelial sheets were separated via Epi-LASIK, the lamina densa and lamina lucida were preserved, and the hemidesmosomes had normal morphology along almost the entire length of the basement membrane. The basal epithelial cells of the separated epithelial disks showed minimal trauma and edema (Figure 3).

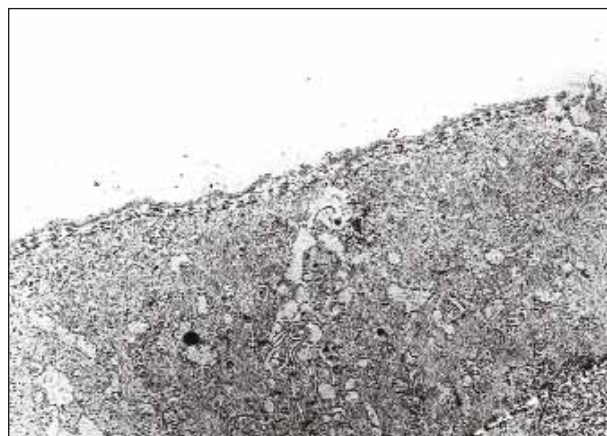
In contrast, specimens excised using 15% and 20% alcohol concentrations showed the formation of cytoplasmic fragments of the basal epithelial cells, enlargement of the intercellular spaces, and extensive discontinuities in the basement membrane, which was excised at the level of the lamina lucida (Figure 4). Preserving the basement membrane is important because it is believed to provide the stability and support that keeps the epithelium intact and preserves its physiological integrity.<sup>2</sup>

**Dr. Katsanevaki:** In another study conducted to determine the viability of the separated epithelial sheet, we examined the epithelial sheets of three patients who underwent Epi-LASIK for myopia.<sup>3</sup> During the postoperative examination of these patients 24 hours after the procedure, the epithelial sheets were dislocated accidentally. The specimens were removed, and the eyes healed, similar to conventional PRK.

We stained and viewed the three sheets using optical and transmission electron microscopy to determine viable versus degraded cells. In the first specimen, we estimated that 87% of the cells were morphologically viable. The second and third specimens showed cell viabilities of 99% and 98%, respectively.

#### WHAT OPTIONS ARE AVAILABLE FOR EPIKERATOME SYSTEMS? HOW SHOULD THESE SYSTEMS BE EVALUATED?

**Dr. Pallikaris:** Our work on the Epi-LASIK technology led to the development of a proprietary surgical system, the Norwood EyeCare Epikeratome. It received 510(k) clearance from the FDA in October 2003. In May 2004, Norwood Abbey acquired the worldwide rights to the system and currently markets the device through its subsidiary, Norwood EyeCare. At least three other companies are also now marketing or developing epikeratomes:



(Courtesy of Vikentia Katsanevaki, MD)

**Figure 3.** Histopathology of intact epithelial sheet after Epi-LASIK.

Visijet, Inc. (Irvine, CA); Moria (Antony, France); and Advanced Medical Optics, Inc. (Santa Ana, CA).

**Dr. McDonald:** In evaluating the various options, it is essential that the epikeratome have a noncutting or non-sharp separator to minimize the stromal incursion rate (the rate at which the separator dives too deeply and removes a small anterior stromal divot). With any sharp separator, there is risk of cutting into Bowman's layer rather than staying in the natural cleavage plane, with all the associated problems.

**Dr. Cross:** The Norwood EyeCare Epikeratome's plastic edge achieves beautiful separation. I have never cut into Bowman's. It is an excellent preparation that polishes Bowman's perfectly. I like the fact that the separator is plastic; it is very forgiving.

**Dr. Camellin:** Plastic is important in reducing the risk of damaging Bowman's membrane as well as the stroma.

**Dr. McDonald:** I also look at the design and placement of the suction ports, which are important for acquiring vacuum effectively and keeping the separator on the natural cleavage plane in a variety of eyes, including deep-set or narrow eyes.

**Dr. Pallikaris:** Norwood EyeCare has already introduced a new 9-mm suction ring size, which allows surgeons to select either the 9- or 10-mm ring to suit the size of the eye. The smaller ring also completely avoids the limbal stem cells, thus reducing the chance of

involving epithelial stem cells at the limbus and reducing healing time.

**Dr. McDonald:** It is not possible to state absolute, optimum parameters for evaluating the oscillation rate, translation speed, or vacuum for the epikeratome systems, because they all relate to one another and the design of the handpiece. In other words, the interplay determines how well the system operates. Each system may have radically different optimal settings.

**Dr. Cross:** In my experience, the design of the Norwood EyeCare Epikeratome's handpiece and the unit's parameters have resulted in an extremely reliable and safe system with no problems.

**Dr. Volpicelli:** Compared with the other options, the Norwood Eyecare Epikeratome has good "surgeon feel"; it is light and ergonomic. Because it is similar to the microkeratome style I prefer, it did not require me to develop a new skill set. Because of the Norwood EyeCare vacuum head's features, such as the advanced castellations/fenestrations, I have never broken suction with it. I have no problem creating an adequately sized epithelial sheet. The two options for suction ring size enable me to work on variously sized eyes as well as those with smaller orbital anatomy.

**Dr. McDonald:** Some of the available Epi-LASIK systems use an applanator to flatten the epithelium in front of the separator as it passes over the cornea. In the case of the Norwood EyeCare Epikeratome, the separator's design incorporates an applanator. Clinical trials are underway to examine the necessity/utility of an applanator, whether incorporated into the separator or attached to the handpiece itself.

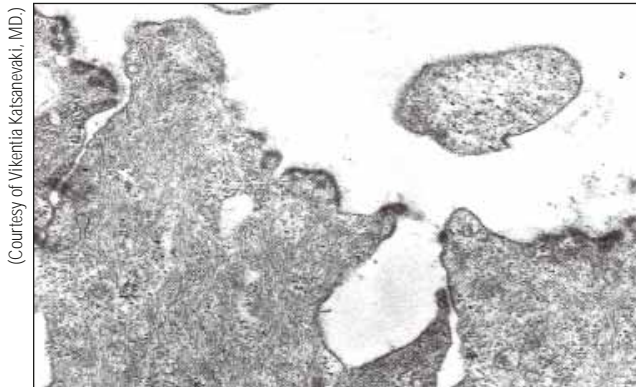


Figure 4. Histopathology of epithelial blebbing following LASEK.

**Dr. Volpicelli:** Instead of a leading applanation device, the Norwood EyeCare Epikeratome has a posterior applanation platform to flatten the cornea as it advances. This unique design feature serves to both applanate the cornea and increase the vacuum.

**Dr. Kantor:** The Norwood EyeCare Epikeratome is "clean" and uncluttered—an important feature for operating accurately and efficiently—and it works well.

#### WHAT TYPES OF PATIENTS ARE CANDIDATES FOR EPI-LASIK? WHAT TYPES ARE NOT CANDIDATES?

**Dr. Cross:** In general, patients who want no or minimal risk are ideal candidates for Epi-LASIK, as are patients who do not want any cutting. Specific patient groups who should be considered for Epi-LASIK include those whose corneas are too thin or too steep for LASIK. My staff and I have performed Epi-LASIK on corneas as flat as 35 and as steep as 52 K and achieved suitable sheets of epithelium. It is obviously a choice procedure for postoperative RK patients; it does not involve incisions or "pizza pie," and the eye seems more stable with less fluctuation after it heals.

You can't sell Epi-LASIK to everyone, however, because it is optically slow to heal. You have to caution patients that their vision will be "soft" (fuzzy) for 3 months, after which it will clear. Immediately postoperatively, Epi-LASIK patients' vision is closer to 20/30, because the attachment of epithelium is not yet perfect. However, most patients actually see better postoperatively than I would expect at that point.

Obtaining a patient history is very important, because there are some types of patients who should not undergo this procedure. There are two distinct groups in particular: those who have had previous PRK and post-LASIK patients. I have performed Epi-LASIK on two eyes of a patient who forgot to tell me that he had undergone PRK 5 years earlier. When the epikeratome hit the area of previous PRK, it created a perfect buttonhole in the epithelial flap. On the second eye, again, the oscillation stopped, and the device traversed the cornea and again produced a buttonhole.

I had another patient who had had LASIK 10 years earlier. In both eyes, the separator instantly found the previous LASIK flap and lifted it. Although it created a perfect lift, I do not recommend this approach. A third group of patients who should not undergo Epi-LASIK is those who have undergone a corneal transplant, for the same reasons I mentioned.

**Dr. Volpicelli:** Epi-LASIK is the perfect niche for patients with flat, steep, or thin corneas; for older patients whose epithelium has the potential for an epithelial slide with LASIK; and for patients with apparent basement-membrane dystrophies. It is a slam dunk for patient groups like these.

### WHAT TIPS CAN YOU PROVIDE FOR SURGEONS PERFORMING EPI-LASIK, ESPECIALLY THOSE NEW TO THE PROCEDURE?

**Dr. Cross:** The learning rate for the Norwood EyeCare Epikeratome is very fast, approximately three to five cases. Epi-LASIK is the perfect procedure for younger physicians entering into refractive surgery and especially good preparation for using blades or the Intralase FS laser (Intralase Corp., Irvine, CA).

**Dr. McDonald:** Regardless of the technology used, there are nuances to performing this procedure. I always recommend watching an expert as well as taking advantage of the wet labs that companies offer.

**Dr. Cross:** Surgeons must be aware that preoperative discussions with Epi-LASIK patients are very different from those with other refractive surgery patients. Epi-LASIK patients must accept a slower visual rehabilitation than LASIK patients. Their vision will be soft, because their epithelial attachments will not be perfectly aligned (as in an unoperated eye), and it takes awhile for the eye to heal. Nevertheless, my staff and I have had no postoperative complaints from Epi-LASIK patients.

**Dr. Cross:** When using the Norwood EyeCare Epikeratome, I test the handpiece by lifting it three or four times before stepping on the forward pedal. Once I have ensured that the suction is sufficient, I let the instrument float in my hand. I find it helpful to decenter the instrument slightly nasally to avoid creating an incompletely hinged flap. One must be careful not to press down on the instrument while the separator passes across the cornea, because too much pressure stops the oscillator. The user should avoid the death grip. Also, it is crucial to remember to mark the sur-

face of the cornea with a dye to indicate the correct alignment when replacing the epithelial sheet.

### WHAT ARE YOUR PREFERRED PRE- AND POSTOPERATIVE REGIMENS?

**Dr. Cross:** My biggest problem with my early Epi-LASIK cases was getting the postoperative management right. My staff and I treated the first 17 patients for 3 days preoperatively and 10 days postoperatively with one of the next-generation fluoroquinolones currently on the market. We had disastrous problems with haze, scarring, epithelial thickening of 3.00D to 5.00D, and the same amount of induced astigmatism. Now, we use Tobradex eye drops (tobramycin and dexamethasone ophthalmic suspension; Alcon Laboratories, Inc., Fort Worth, TX) b.i.d. as European ophthalmologists do, and we are very pleased. Our patients' eyes look healthy and see well.

**Dr. McDonald:** I have a very extensive regimen of pre- and postoperative medication that I am convinced minimizes discomfort and accelerates healing with Epi-LASIK. I have my patients start using vitamin C (500mg b.i.d.) at 1 week preoperatively and continue 1 week after surgery. On the day of surgery, a technician administers oral prednisone (80mg) and 1 drop of brimonidine tartrate 0.15% (Alphagan-P; Allergan, Inc., Irvine, CA) 30 minutes preoperatively. The timing of this first dose of oral prednisone is critical.

Postoperatively, patients continue using prednisone for 5 days and taper down to 5mg. We also prescribe 150mg orally b.i.d. of a histamine H2-receptor agonist (Zantac; GlaxoSmithKline, London, UK), a fluoroquinolone antibiotic eye drop q.i.d., and prednisolone acetate drops q.i.d.

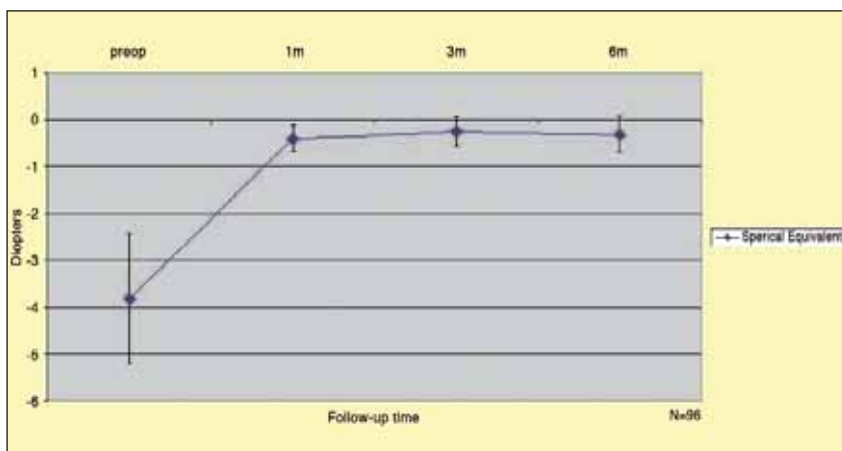


Figure 5. Change in spherical equivalent after undergoing Epi-LASIK.

(Courtesy of Ioannis Palikaris, MD, PhD)

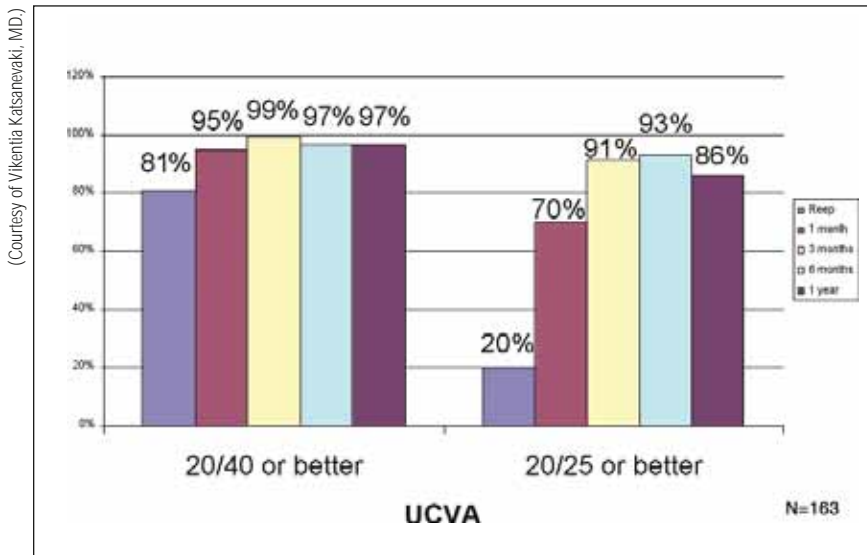


Figure 6. One-year UCVA results after undergoing Epi-LASIK.

for 1 week after surgery. Also, we prescribe a topical NSAID drop (ketorolac in the form of Acular LS [Allergan, Inc.] is my favorite) q.i.d. for the first 3 postoperative days, unpreserved artificial tears every 2 hours while awake, and "comfort drops" (1/20 of 1% tetracaine, from a compounding pharmacist) hourly as needed for the first 3 days. For mild pain, I recommend acetaminophen (500mg). I also prescribe an opioid analgesic such as Mepergan Fortis (a combination of Demerol and phenergan; Wyeth Pharmaceuticals, Philadelphia, PA) as an escape medication, along with ice packs immediately postoperatively and prn at home.

**Dr. Cross:** Our Epi-LASIK patients experience little-to-no pain. Most pain is related to the inflammatory response, so we start our patients on an anti-inflammatory medication a few days preoperatively, and then we put a "frozen popsicle" on the cornea for 1 minute immediately after the ablation. As a result, we have had no patients ask for a pain remedy. One other important point is that changing to the Accuvue Advance contact lens (Johnson & Johnson Vision Care, Inc., Jacksonville, FL) postoperatively is so much more comfortable than the Night & Day contact lens (CIBA Vision, Duluth, Georgia).

#### WHAT RESULTS ARE YOU SEEING WITH EPI-LASIK?

**Dr. Cross:** I have used the Norwood EyeCare Epikeratome on many different types of patients, and

healing is better in the long run than with LASIK. The cornea is clearer, and vision is even better. The average patient's postoperative UCVA is approximately 20/30, and yet these people think they see very well and never complain about their vision. In contrast, a LASIK patient who sees 20/30 the next day will complain about his quality of vision. If you warn Epi-LASIK patients preoperatively that their vision is going to be that way for 3 to 6 weeks and then improve, and that by 4 to 6 months it will be very good, then they accept this outcome.

By 3 to 6 months, patients' vision is very good, and they are pleased. Almost all of the Epi-

LASIK eyes stabilize with acuities of better than 20/20 and often of 20/12.5 or 20/10. Also, the procedure seems to work equally well on myopes and hyperopes.

One year after undergoing Epi-LASIK, patients' corneas are incredibly clear with no scarring. Their vision is very good, better than with LASIK or an Intralase procedure. Epi-LASIK patients also have less dry eye than LASIK patients, and those who do have the condition resolve it faster. I have not seen any residual dry eye in any of my Epi-LASIK patients.

**Dr. Durrie:** With Epi-LASIK, vision on the fourth or fifth day is substandard because the epithelium grows in from the outside and bunches up in the middle. We call this *soft*, meaning that it is not attached in the center, so patients cannot see very well. Initially, postoperative Epi-LASIK vision may not be quite as good as with PRK, but this is generally not an issue for patients, who experience a substantial improvement from their preoperative vision. With Epi-LASIK, they should be between 20/25 and 20/30 for the first postsurgical week.

**Dr. Pallikaris:** H. Burkhard Dick, MD, PhD, Director of Refractive Surgery at Johannes Gutenberg University in Mainz, Germany, reported on 6-month results of 22 Epi-LASIK cases performed with the Norwood EyeCare Epikeratome as part of a multicenter European trial.<sup>4</sup> At 6 months, the average refraction went from -3.25D preoperatively to -0.10D, similar to results I have obtained

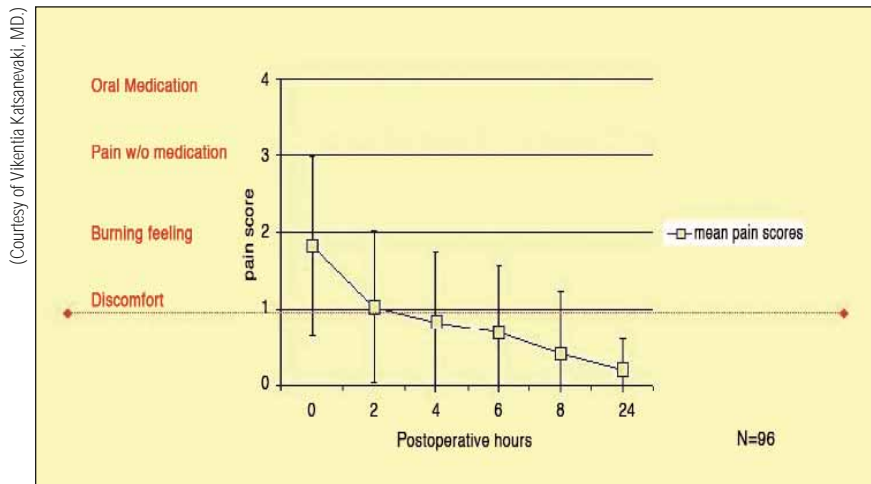


Figure 7. Mean pain scores immediately after undergoing Epi-LASIK.

(Figure 5). In Dr. Dick's study, there were no lost lines of BCVA, and 19% of the patients gained one line or more of BCVA. The histopathological examination Dr. Dick conducted also established that the epithelium was fully intact after separation.

**Dr. Katsanevaki:** In a recent analysis of UCVA for 163 eyes treated with Epi-LASIK for moderate myopia, 81% had an acuity of 20/40 or better at re-epithelialization, with 95% achieving that level of vision at 1 month and 99% at 3 months. Approximately nine out of 10 patients had 20/25 or better UVCA starting at 3 months (Figure 6).

**Dr. Volpicelli:** My colleagues and I are seeing patients' vision improving faster by 1 month after Epi-LASIK versus with PRK or LASEK, where the epithelium is still remodeling. For our first 22 cases, at 1 month, approximately two-thirds are seeing 20/20 or better, including one-third who have UCVA's of better than 20/20. In terms of correction, half are right on the nose, and another one-third are within -0.50D. No patient has lost any lines of BSCVA, a great finding compared with PRK. Also, patients' UCVA is approximately one line better than with LASEK.

### WHAT LEVELS OF POSTOPERATIVE PAIN, HAZE, AND CORNEAL SENSITIVITY DO PATIENTS EXPERIENCE?

**Dr. Katsanevaki:** In our clinical study of 96 patients undergoing Epi-LASIK with the Norwood EyeCare Epikeratome, my colleagues and I examined self-reported postoperative pain scores using a five-point scale (Figure 7). Immediately postoperatively, patients reported a mean pain score of nearly 2.0, which corresponded to "a burning feeling." At 2 hours, the mean reported score was approximately 1.0 ("discomfort"). At 8 hours, the mean score was less than 0.5, and at 24 hours, it was close to 0.

In a recent analysis of pain scores for 163 eyes treated with Epi-LASIK for moderate myopia, mean postoperative scores at 2 hours remained below 1.5. At 2 hours, only 12% reported pain higher than 1.0, and that percentage dropped to 2% at 8 hours (Figure 8). In a similar study of 92 eyes conducted by Efehan Coskunseven, MD, 80% of patients reported no pain or major discomfort.<sup>5</sup>

Our study of 96 patients also examined the incidence of haze from 1 to 6 months after Epi-LASIK (Figure 9).

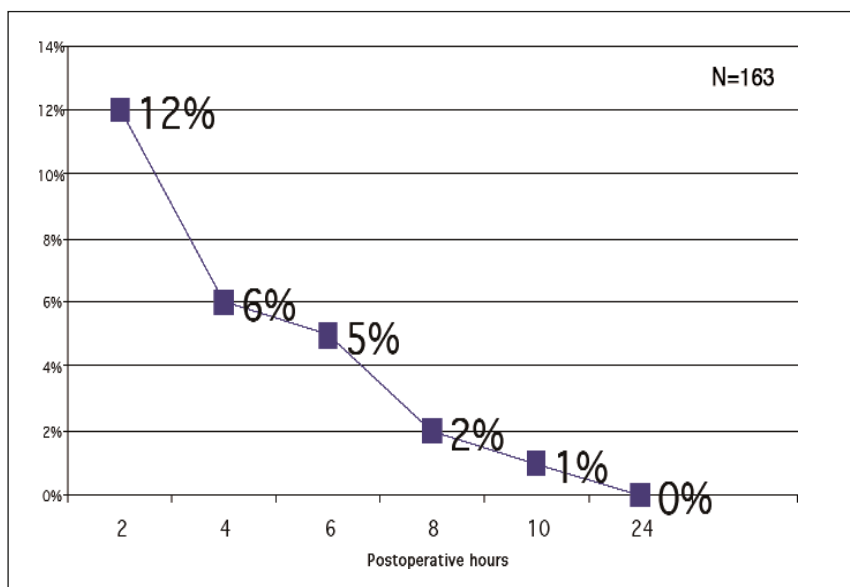


Figure 8. Decrease in percentage of eyes with postoperative pain over 24 hours.



(Courtesy of Ioannis Pallikaris, MD, PhD.)

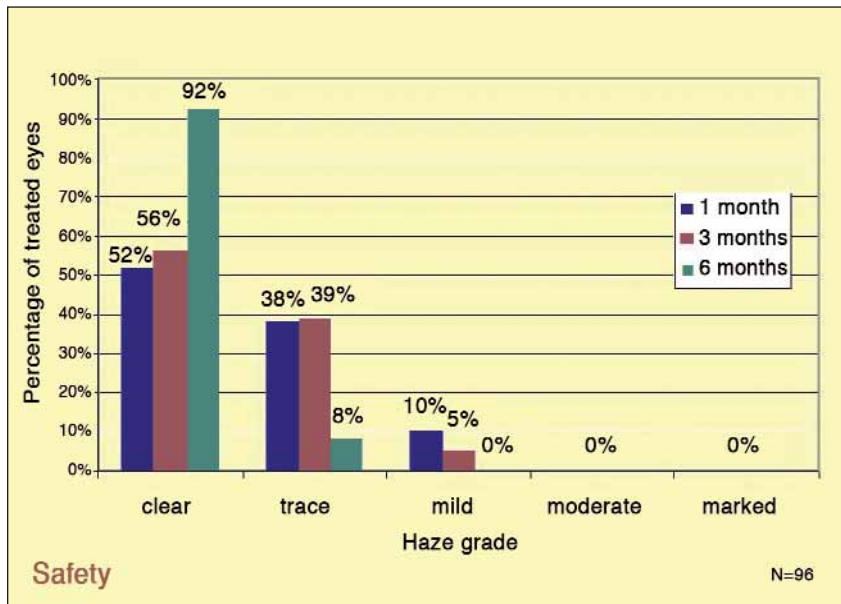


Figure 9. Incidence of haze after undergoing Epi-LASIK.

At 1 month, 10% of patients reported mild haze, 38% had a trace of haze, and 52% of eyes were clear. By 6 months, 92% of the eyes were clear, and 8% of patients reported a trace of haze. In Dr. Coskunseven's study, 78% of cases had clear corneas, and 22% had trace haze that resolved by 6 months.<sup>6</sup>

In the study of 163 eyes, an analysis conducted by Maria I. Kalyvianaki, MD, found that corneal sensitivity (as measured with the Cochet-Bonnet aesthesiometer [Luneau Ophthalmologie, Chartres, France]) declined slightly to a mean of 5cm by 1 month postoperatively, but it returned to preoperative levels by 3 months<sup>11</sup> (Figure 10). When LASIK and Epi-LASIK patients were matched by their attempted correction and treatment zone and compared, Epi-LASIK patients returned to their preoperative sensitivity levels by 3 months and remained at that level. In contrast, the LASIK patients' sensitivity began to approach their preoperative levels at 3 months but had declined significantly by 6 months<sup>12</sup> (Figure 11).

**Dr. Volpicelli:** The first few days, of course, are not comparable with LASIK with regard to comfort, but I am seeing less pain than with PRK and no haze at all. Analysis is still in progress on my patients' objective comfort data, including pain scores and their use of pain medication during the first 72 hours postoperatively.

## HOW DO YOU FEEL ABOUT THE SAFETY OF EPI-LASIK?

**Dr. Vinciguerra:** My patients who have undergone Epi-LASIK are very satisfied and surprised with their results. Most important to me, however, is the safety of having more tissue available. By only removing the corneal epithelium, Epi-LASIK leaves plenty of tissue (200 to 250 $\mu$ m of stroma) for ablating. With LASIK flap thicknesses as great as 200 $\mu$ m, there might not be much tissue left.

**Dr. Cross:** Epi-LASIK is the safest of all the corneal procedures and does not weaken the structural integrity of the cornea, unlike LASIK and even an Intralase procedure. Almost nothing can go

wrong with Epi-LASIK; the worst that can happen is that the surgeon loses the epithelium and has to convert to PRK. With Epi-LASIK, the surgeon can almost do no harm.

**Dr. Kantor:** The safety issue is paramount, because one of the main causes of patients' rejection of laser vision correction is fear.

## WHAT NEW RESEARCH ON EPI-LASIK IS UNDERWAY?

**Dr. McDonald:** I am a principal investigator and the medical monitor for Norwood EyeCare's post-approval, 3-month US prospective study to assess the postoperative comfort and visual recovery of wavefront-guided customized myopic Epi-LASIK with the Norwood EyeCare Epikeratome. Dr. Durrie and the team of Lee Shahinian, MD, and Mark Volpicelli, MD, are also clinical investigators.

**Dr. Pallikaris:** In this exciting study, it will be especially interesting to see how the coupling of Epi-LASIK and wavefront technology may impact visual outcomes.

**Dr. Camellin:** Epi-LASIK has an advantage in wavefront-guided procedures, because it respects the biomechanics of the cornea and does not introduce variations into its shape.

(Courtesy of Vikentia Katsanevaki, MD.)

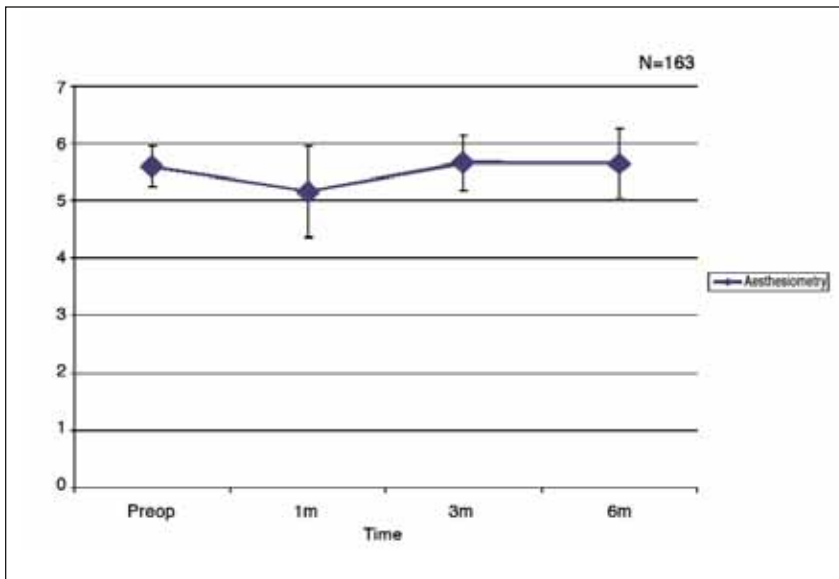


Figure 10. Changes in corneal sensitivity after undergoing Epi-LASIK.

**Dr. Vinciguerra:** Epi-LASIK enhances wavefront-guided procedures by not cutting the stroma and by thus lowering the chance of inducing additional aberrations.

**Dr. Durrie:** None of the other epikeratome manufacturers are conducting controlled, multicenter studies like Norwood EyeCare's US prospective study. It is impressive that the company has enough confidence in its product that it is willing to subject the unit to scrutiny with US investigators.

**Dr. McDonald:** It is important that a manufacturer of a relatively new technology be committed to ongoing design and clinical research. Ultimately, it is this body of research that will reveal which design platform or platforms are most safe and effective.

**Dr. Camellin:** I am working on a blinded study comparing LASEK and Epi-LASIK. I am masking the patients to which eye received the Epi-LASIK treatment in order to avoid any subjective influence that could modify their perception of pain.

comparative trials of Epi-LASIK used with other vision-correction approaches will allow us to further evaluate Epi-LASIK as a strong alternative to photorefractive correction.

**Dr. McDonald:** The refractive community is embracing Epi-LASIK as the most advanced form of surface ablation. I believe the differences in the speed of visual

**Dr. Durrie:** After the US prospective study, I would like to see a confirmatory study of Epi-LASIK versus PRK. It should be a randomized, contralateral, masked (from patients and during post-operative visits) prospective study, comparable to the study I conducted last year for Intralase Corp. As a second phase, I would like to see Epi-LASIK performed on one eye and the Intralase procedure on the other eye.

#### WHAT IS THE FUTURE OF EPI-LASIK?

**Dr. Pallikaris:** The refractive community has already enthusiastically accepted Epi-LASIK. Data from the US prospective study as well as forthcoming data from

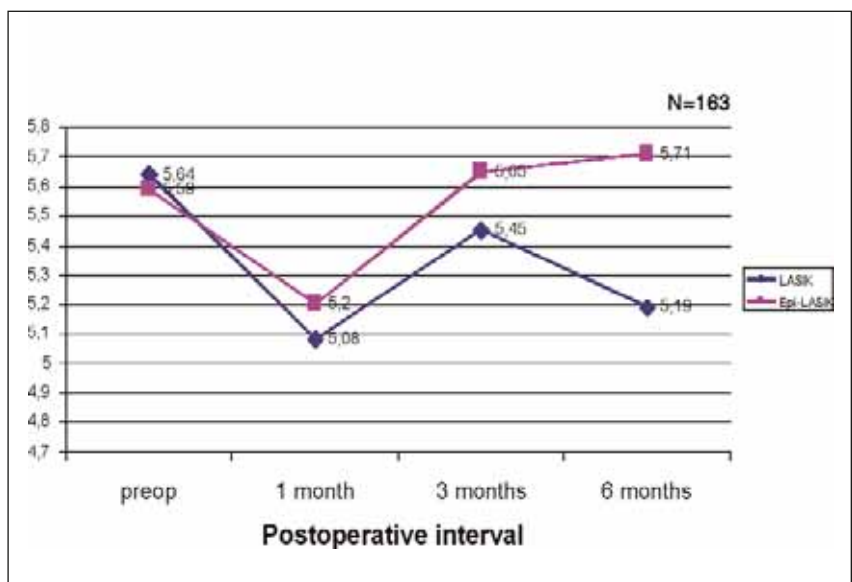


Figure 11. Corneal sensitivity comparison following LASIK and Epi-LASIK.

(Courtesy of Vikentia Katsanevaki, MD.)

recovery and early postoperative pain between LASIK and Epi-LASIK are no longer clinically significant, and patients readily perceive the advantages of blade-free laser vision correction. Data from the US prospective study and eventual comparative trials of Epi-LASIK with other iterations of laser vision correction will allow us to determine Epi-LASIK's place in our refractive armamentarium.

**Dr. Volpicelli:** For Epi-LASIK to replace LASIK 100%, its recovery period and comfort issues would have to be resolved. Right now, Epi-LASIK is the perfect niche procedure for certain patients, as I mentioned earlier.

**Dr. Cross:** If we can figure out how to get the epithelium to heal faster, Epi-LASIK will become the procedure of choice. Its safety factor and ultimate results are quite good.

**Dr. Kantor:** Because of its safety factor, I feel that Epi-LASIK should replace LASIK almost completely in my practice. I think that when we address the pain issue, then most patients will have a good reason to switch.

**Dr. Vinciguerra:** I could see Epi-LASIK's replacing LASIK surgery almost totally. □

*Ioannis Pallikaris, MD, PhD, is the founder and director of the Vardinoyannion Eye Institute of Crete as well as President of the University of Crete and Chairman of its Department of Ophthalmology in Greece. Dr. Pallikaris is President of the European Society of Cataract and Refractive Surgeons. He is a paid consultant to Norwood EyeCare and a founding member of its medical and scientific advisory board. Dr. Pallikaris may be reached at +011 3081542094; pallikar@med.uoc.gr.*

*Marguerite B. McDonald, MD, FACS, is Clinical Professor of Ophthalmology at Tulane University and former President of the American Society of Cataract and Refractive Surgery. She is Norwood EyeCare's Global Medical Advisor and a member of its medical and scientific advisory board. Dr. McDonald may be reached at (504) 896-1250; margueritemcdmd@aol.com.*

*Warren D. Cross, MD, is a founder of Bellaire Eye & Laser Center in Houston. He states that he holds no financial interest in any product or company mentioned herein. Dr. Cross may be reached at (713) 666-4224; wdceyemd@msn.com.*

*Daniel S. Durrie, MD, is Associate Clinical Professor and Director of Refractive Surgery Services at the University of Kansas Medical Center and the leader of the Durrie Vision refractive surgery team in Overland Park, Kansas. He states that he holds no financial interest in any product or company mentioned herein. Dr. Durrie may be reached at (913) 497-3737; ddurrie@durrievision.com.*

*Massimo Camellin, MD, of the Sekal Microchirurgia Rovigo in Rovigo, Italy, is the developer of the LASEK procedure. He states that he holds no financial interest in any product or company mentioned herein. Dr. Camellin may be reached at +39 0425 411357; cammas@tin.it.*

*Paolo Vinciguerra, MD, is Director of the Ophthalmology Department for the Istituto Clinico Humanitis in Milan, Italy. He states that he holds no financial interest in any product or company mentioned herein. Dr. Vinciguerra may be reached at +39 02 55211388; vincieye@tin.it.*

*Vikentia Katsanevaki, MD, PhD, practices refractive surgery in the Vardinoyannion Eye Institute of the University of Crete, Greece. She is a paid consultant for Norwood Eyecare. Dr. Katsanevaki may be reached at +30 2810 371800; vikatsan@med.uoc.gr.*

*Mark Volpicelli, MD, is in private group practice in Mountain View, California. He states that he holds no financial interest in any product or company mentioned herein. Dr. Volpicelli may be reached at (650) 961-2585; volpeyes@aol.com.*

*Robert L. Kantor, MD, FACS, is head of the Kantor Eye Institute and Laser Center in Sarasota, Florida. He states that he holds no financial interest in any product or company mentioned herein. Dr. Kantor may be reached at (941) 925-8888; rlkantor@kantoreye.com.*

1. Pallikaris IG, Naoumidi II, Kalyvianaki MI, Katsanevaki V. Epi-LASIK: comparative histological evaluation of mechanical and alcohol-assisted epithelial separation. *J Cataract Refract Surg.* 2003;29:8:1496-1501.
2. Azar DT, Ang RT, Lee J-B, et al. Laser subepithelial keratomileusis: electron microscopy and visual outcomes of flap photorefractive keratectomy. *Curr Opin Ophthalmol.* 2001;12:323-328.
3. Katsanevaki V. Epithelial specimens viable 24 hours after Epi-LASIK. *Ophthalmology Times.* 2004;29:17:48.
4. Dick HB. Early Epi-LASIK results indicate efficiency, safety for low myopia. *Ophthalmology Times.* 2004;29:14.
5. Coskunseven, E. Epi-LASIK for low myopia: 1-year results in 92 eyes. Paper presented at: The ASCRS/ASOA 2005 Symposium on Cataract, IOL and Refractive Surgery; April 16, 2005; Washington, DC.
6. Coskunseven, E. Epi-LASIK for low myopia: 1-year results in 92 eyes. Paper presented at: The ASCRS/ASOA 2005 Symposium & Congress; April 16, 2005; Washington, DC.

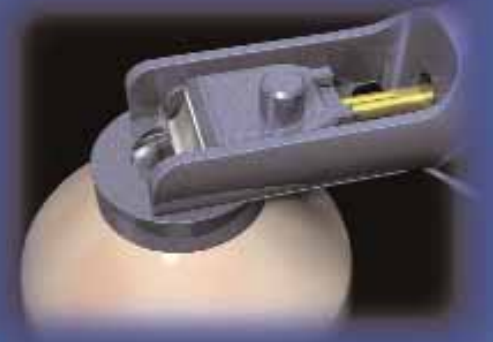
*Interested in learning Epi-LASIK?*

# **Epi-LASIK Skills Transfer Courses**

*Register today for this educational course where you'll hear and learn how Epi-LASIK can be the solution for your laser vision correction patients. In addition to learning how to integrate Epi-LASIK into your practice, you're invited to participate in hands-on wet labs and other interactive sessions.*

*For more information, visit  
[www.ebmccg.com/EpiLASIK.html](http://www.ebmccg.com/EpiLASIK.html)*

*Technicians Welcome!*



***PARTICIPANTS WILL LEARN HOW TO:***

- P Identify the best potential candidates for Epi-LASIK*
- P Understand the unique characteristics and limitations of Epi-LASIK compared to LASIK, PRK and LASEK*
- P Describe and apply the principles for managing patients pre- and postoperatively*
- P Understand marketing concepts designed to attract potential Epi-LASIK patients*

***COURSE DIRECTOR***

***Marguerite B. McDonald, MD, FACS***

*Clinical Professor of Ophthalmology, Tulane University, School of Medicine  
New Orleans, Louisiana*

***2005-2006 COURSE SCHEDULE\****

*\*Tentative Schedule*

*August 20, 2005 .....Boston, MA*

*October 13, 2005 .....Chicago, IL*

*January 14, 2006 .....Maui, HI*

*March 16, 2006 .....San Francisco, CA*

*May 20, 2006 .....Dallas/Ft. Worth, TX*

*June 17, 2006 .....Ft. Lauderdale, FL*

***[www.ebmccg.com/EpiLASIK.html](http://www.ebmccg.com/EpiLASIK.html)***