THE V-SLICE TECHNIQUE

A novel, noncracking, nonrotational maneuver for the phacoemulsification of soft lenses.

BY JEFFREY YEE, MS, MD; KEVIN BRAY, MD; POOJA GODARA, MD; CARTER KIRK, MD; DAVID NEELY, MD; AND JACK PARKER, MD

Ironically, soft cataracts can be among the hardest to remove. The unique challenge they pose stems from their amorphous, gelatinous bodies, which render many of the most common phaco strategies either inapplicable or ineffectual. Cracking maneuvers, for example, can be difficult or impossible to perform, because they typically depend on the presence of rigid cleavage planes, which are frequently absent. Rotation may also be a problem, because instruments placed to achieve this effect may instead "cheese wire" through without achieving enough resistance to effectively turn the lens. If these two operations cannot be accomplished and the lens therefore remains undivided and tethered to its surrounding capsule, then subsequent phacoemulsification must proceed much more slowly and awkwardly, and the risk of complications increases.

Recognition of the special difficulties posed by soft lenses has led to a proliferation of tools and techniques for addressing the challenge. For example, the Akahoshi prechopping maneuver employs special forceps to divide the nucleus into quadrants.[1,2] (Viteri described a related technique, also involving specialized forceps.[3]) The phaco flip somersaults the whole lens into the anterior chamber[4]; the bowl-and-snail technique is similar but involves phacoemulsifying half of the nucleus before flipping it.[5] The hydro-chop and visco-fracture techniques split the nucleus by injections of saline and an ophthalmic viscosurgical device (OVD), respectively.[6,7]

If some criticism can be levied against these alternatives, it is that they either require some specialized (potentially fragile/expensive) instrumentation or rely on pushing the lens around the eye, which demands some minimal amount of nuclear bulk. As a result, there may be some room for a new strategy, one that demands neither specialized instrumentation nor nuclear rotation. To this end, we recently devised the V-slice. We have used the technique in approximately 200 cases to date, and it has become our standard approach to soft lenses.

ABOUT THE TECHNIQUE

The surgery begins per usual. After creating a paracentesis, we instill preservative-free lidocaine into the anterior chamber followed by an OVD. We then create the main incision and

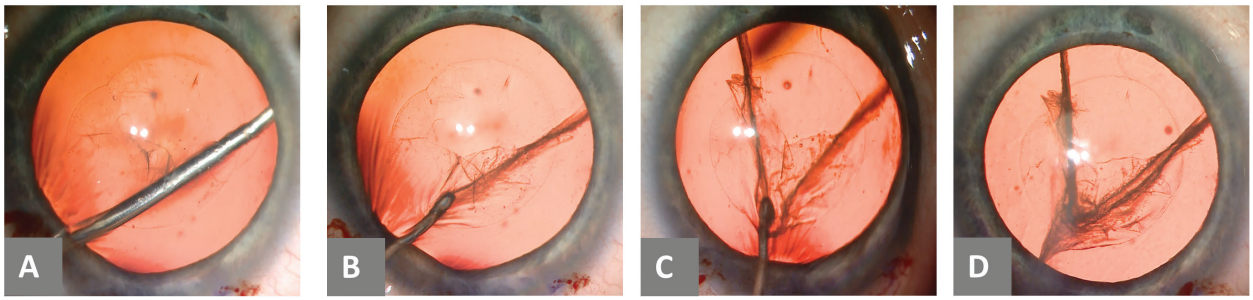

Figure. After completing the capsulorhexis, the surgeon slips a blunt-tipped instrument beneath the anterior capsule at the 7-o'clock position and around the lens equator (A). The instrument is then passed gently through the nucleus at approximately 50% depth towards 12 o'clock (B). This maneuver is then repeated, slicing from 5 to 12 o'clock, to produce a central pie-shaped piece and two lateral crescent-shaped segments (C, D).

WATCH IT NOW

The authors demonstrate the V-slice technique.

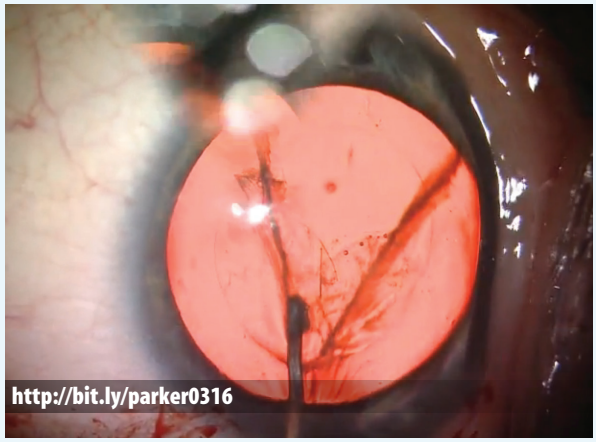

craft a continuous curvilinear capsulorhexis that has a normal diameter (5-5.5 mm). Next, we slide a blunt-tipped instrument (we prefer the Goldberg Nucleus Manipulator [Ambler Surgical, Rhein Medical]) across the surface of the lens at the 5- and 7-o'clock positions, underneath the anterior capsule, and around the lens equator. Subsequently, the instrument is passed through the lens (at approximately one-half to two-thirds depth) towards 12 o'clock to produce a central, V-shaped, presliced segment and two lateral crescent-shaped pieces (Figure). If we encounter any resistance, we abort the V-slice and select another technique.

After performing gentle hydrodelineation and hydrodissection, we inject an OVD into the cracks produced by the previous slicing to further separate the pieces from each other and to push back the posterior capsule. The phaco handpiece and Connor wand (Ambler Surgical, Rhein Medical) cooperate to remove the three pieces, starting with the central pie-shaped segment, because it is usually devoid of adjacent adhesions and floating free at the level of the capsulorhexis.

The operation concludes according to routine. We use the I/A handpiece to complete gentle cortical cleanup, fill the capsular bag with an OVD, inject the lens, remove the OVD, and seal the incisions.

PROS AND CONS

In soft cataracts, the V-slice may have several advantages. First, lens division occurs prior to hydrodissection, when visualization is maximal and the edges of the capsulorhexis can be clearly seen. Second, nuclear segmentation requires only a blunt, inexpensive, commonly available instrument, which can be leveraged through the main incision in a single-handed fashion. Third, the technique is easy, provided that a lens of the appropriate density is chosen.

AT A GLANCE

- Soft cataracts can be challenging to remove.
- The V-slice technique developed by the authors demands neither specialized instrumentation nor nuclear rotation.

The biggest disadvantage of the V-slice is that it seems to be suitable only for very soft lenses, because attempting the maneuver on denser nuclei may risk significant zonular stress. Nevertheless, in our hands, the technique has been a useful adjunct for select cases when other (especially cracking, chopping, and rotating) maneuvers have proven suboptimal. ■

1. Akahoshi T. The Karate Prechop technique. *Cataract & Refractive Surgery Today*. April 2002;2(2):63-64. http://crstoday.com/2002/04/0402_23.html. Accessed February 4, 2016.
2. Akahoshi T. Phaco prechop: manual nucleofracture prior to phacoemulsification. *Op Tech Cataract Ref Surg*. 1998;1:69-91.
3. Viteri E. V-prechop: a simplified and safer technique for cataract surgery. *Ocular Surgery News*. May 2004. http://bit.ly/1ooAQvC. Accessed February 9, 2016.
4. Brown DC. The phaco flip technique. *Cataract & Refractive Surgery Today*. September 2002;2(9):58-59. http://crstoday.com/2002/09/0902_201.html. Accessed February 4, 2016.
5. Gomaa A, Liu C. Bowl-and-snail technique for soft cataract. *J Cataract Refract Surg*. 2011;37:8-10.
6. Malavazzi GR, Nery RG. Visco-fracture technique for soft lens cataract removal. *J Cataract Refract Surg*. 2011;37:11-12.
7. Braga-Mele R, Khan BU. Hydro-chop technique for soft lenses. *J Cataract Refract Surg*. 2006;32(1):18-20.

Kevin Bray, MD
- ophthalmology resident, UAB Callahan Eye Hospital, Birmingham, Alabama
- financial interest: none acknowledged

Pooja Godara, MD
- ophthalmology resident, UAB Callahan Eye Hospital, Birmingham, Alabama
- financial interest: none acknowledged

Carter Kirk, MD
- ophthalmology resident, UAB Callahan Eye Hospital, Birmingham, Alabama
- financial interest: none acknowledged

David Neely, MD
- ophthalmology resident, UAB Callahan Eye Hospital, Birmingham, Alabama
- financial interest: none acknowledged

Jack Parker, MD
- ophthalmology resident, UAB Callahan Eye Hospital, Birmingham, Alabama
- (205) 933-1077; jack.parker@gmail.com
- financial interest: none acknowledged

Jeffrey Yee, MS, MD
- professor of ophthalmology, UAB Callahan Eye Hospital, Birmingham, Alabama
- financial interest: none acknowledged