

# Slipped Intracorneal Ring Segments

BY TENLEY N. BOWER, MD, FRCSC; DEEPINDER K. DHALIWAL, MD, LAc; MICHAEL EHRENHAUS, MD; AND ALEXANDER HATSIS, MD

## CASE PRESENTATION

Two patients underwent the uncomplicated placement of Intacs (Addition Technology) for the treatment of keratoconus in one eye using two asymmetric segments (0.45 mm inferiorly and 0.21 mm superiorly). The channels were created using a femtosecond laser (iFS Laser; Abbott Medical Optics), and the programmed inner and outer diameters were 6.8 and 8.1 mm, respectively. At the 1-month postoperative visit, both patients had experienced slippage of the superior ring segment. In patient 1, the superior segment had slipped inferiorly and had come to rest adjacent to the thicker, inferior segment (Figure 1). In patient 2, the superior ring segment had slipped inferiorly and had come to rest on top of the inferior segment (Figure 2).

What clinical implications are present in each of these cases? Would you recommend intervention, and if so, when?

—Case presented by Parag A. Majmudar, MD.

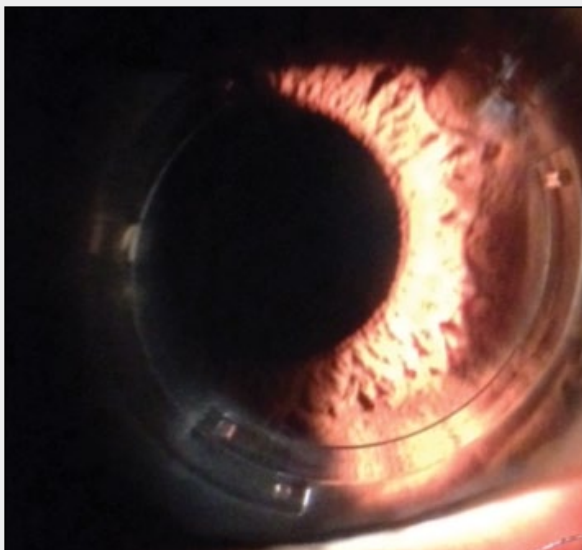


Figure 1. After slipping, the superior Intacs rests adjacent to the thicker, inferior segment.

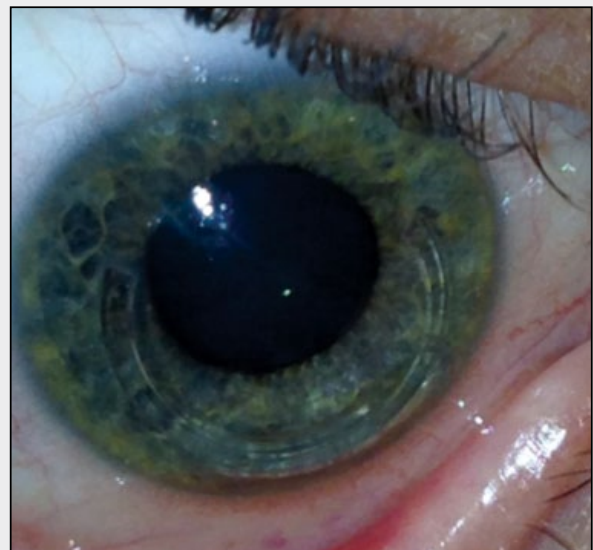

Figure 2. In this eye, the superior segment rests on top of the inferior segment.

### TENLEY N. BOWER, MD, FRCSC, AND DEEPINDER K. DHALIWAL, MD, LAc

Joseph Colin, MD, pioneered the use of Intacs in the treatment of keratoconus as a way to “regularize” the ectatic cornea and decrease irregular astigmatism.<sup>1,2</sup> With the femtosecond laser, surgeons are able to create

more reliable channels at the intended depth, which can decrease the chance of the segments’ erosion or migration.<sup>3,4</sup>

The patients in these cases experienced migration of the thinner, superior ring segment. A likely etiology is the creation of larger channels than intended. It is important

---

“It is my opinion that segments do not slip but are pushed out of position by rubbing.”

–Alexander Hatsis, MD

---

that the surgeon double-check the laser’s settings prior to initiating treatment, because the laser technician enters these manually. Other causes of segments’ migration include trauma, eye rubbing, and inadvertent pressure on the globe during sleep.

A guiding principle for the placement of an Intacs segment, as recommended by Dr. Colin, is that its end should not be near the thinnest point of the cornea so as to avoid corneal erosion with subsequent extrusion of the implant. To determine the next step in the management of each of these cases, we would have to assess the visual and refractive status of the patients in addition to evaluating the location of the end of the migrated Intacs in relation to the thinnest point of the cornea. In case 1, where the segments are resting side by side, if the aforementioned parameters were satisfactory, the patient could be observed without surgical intervention. If an end of the segment were in an area of corneal thinning, however, then the thinner segment should be removed, and the larger segment should be adjusted to straddle the cone.

In case 2, where one segment is on top of the other, it would be advisable to remove the thinner Intacs, because the risk of erosion is high. After removal, the thicker segment should be repositioned to straddle the cone, and then, an intrastromal suture could be placed to close the channel on either side of the thicker segment to prevent future migration.

Postoperatively in any Intacs patient, it is important to control ocular itching and eye rubbing with medications such as a topical mast cell stabilizer-antihistamine and for the patient to use a protective eye shield at night.

### **MICHAEL EHRENHAUS, MD**

It is highly unusual, especially in a case of even oversized IntraLase FS Laser-created channels (Abbott Medical Optics) to have such drastic movement of a segment without external pressure.

The lack of efficacy is the primary ineffective outcome here, but it should also be noted that, if the segments ride one atop the other (in the z axis, front to back), there could be corneal melting in that area. If they are next to each other, side by side, they will simply lack

effect. I have been consulted on and managed both of these scenarios.

It is also possible that the newer iFS created very smooth, large channels. If so, it is conceivable that, despite not separating the “postage stamp edge” stromal interdigitations of the segments during their placement, these stromal “fingers” were fine enough to separate on their own due to the expanding pressure of the segments once placed into the stroma.

Exchanging the slipped segments via the original entrance incision could be easily accomplished with a Sinsky hook, and the thin segments could be removed or even replaced with 0.45-mm segments. Alternatively, both segments could be removed, and 2 to 3 months later, the patients could undergo corneal collagen cross-linking (not FDA approved) and/or the creation of new channels with smaller, tighter diameters to prevent slippage. The newer rings for severe keratoconus or even Ferrara Rings or Kerarings (both from Mediphacos) could also be considered, since their placement would actually be more central and not affected by the oversized Intacs channels.

### **ALEXANDER HATSIS, MD**

I have seen both of these complications, and in each case, the patient was a chronic eye rubber. It is my opinion that segments do not slip but are pushed out of position by rubbing. When the superior segment is adjacent to the inferior one (Figure 1), the patient should notice, if applicable, a change in contact lens fit as well as in visual acuity due to the reduced effect of the Intacs. When one segment rides over the other, the architecture of the corneal surface becomes severely distorted. Not only does the patient’s visual acuity change, but he or she will also likely complain of epiphora and a painful foreign body sensation, with possible epithelial staining over the elevation.

Both of these patients must be counseled about the dangers of rubbing their eyes. An examination of the ocular surface could uncover reasons behind their need to rub their eyes such as dry eye disease, meibomian gland dysfunction, *Demodex*, anterior blepharitis, and allergy.

Although surgical repositioning should be considered, the first patient could be monitored if he or she does not notice a change in vision, contact lens comfort, or wearing time. The slipped segment in the second case should be surgically repositioned. If, after a successful repositioning, the superior Intacs moved again, I would consider removing it. If the patient and I decided to proceed with a second repositioning, I would place a 10–0 nylon suture through the positioning hole to keep the segment in place until channel fibrosis developed through the holes to secure the implant. ■

Section Editor Stephen Coleman, MD, is the director of Coleman Vision in Albuquerque, New Mexico.

Section Editor Parag A. Majmudar, MD, is an associate professor, Cornea Service, Rush University Medical Center, Chicago Cornea Consultants, Ltd. Dr. Majmudar may be reached at (847) 882-5900; pamajmudar@chicagocornea.com.

Section Editor Karl G. Stonecipher, MD, is the director of refractive surgery at TLC in Greensboro, North Carolina.

Tenley N. Bower, MD, FRCSC, is a cornea and external disease fellow at University of Pittsburgh School of Medicine. She acknowledged no financial interest in the products or companies she mentioned. Dr. Bower may be reached at bowertn@upmc.edu.



Deepinder K. Dhaliwal, MD, LAc, is an associate professor of ophthalmology, University of Pittsburgh School of Medicine; director, Cornea and Refractive Surgery Services, UPMC Eye Center; director and founder, Center for Integrative Eye Care, UPMC Eye Center; and director, UPMC Laser/Aesthetic Center. She acknowledged no financial interest in the products or companies she mentioned. Dr. Dhaliwal may be reached at (412) 647-2214; dhaliwaldk@upmc.edu.



Michael Ehrenhaus, MD, is director of New York Cornea Consultants in Bayside, New York, and an assistant professor, Cornea and Refractive Surgery Service, SUNY Downstate Medical Center in Brooklyn, New York. He acknowledged no financial interest in the products or companies he mentioned. Dr. Ehrenhaus may be reached at (718) 425-0903; corneaconsult@me.com.



Alexander Hatsis, MD, is the director of Long Island Vision Experts in Rockville Centre, New York. Dr. Hatsis is also senior attending for resident training and the director of refractive surgery at the Nassau University Medical Centre on Long Island, New York. He acknowledged no financial interest in the products or companies he mentioned. Dr. Hatsis may be reached at (516) 763-4106; hatsis@aol.com.



1. Burris TE, Ayer CT, Evensen DA, Davenport JM. Effects of intrastromal corneal ring size and thickness on corneal flattening in human eyes. *Refract Corneal Surg.* 1994;7:45-50.
2. Burris TE, Baker PC, Ayer CT, et al. Flattening of central corneal curvature with intrastromal corneal rings of increasing thickness: an eye-bank eye study. *J Cataract Refract Surg.* 1993;19(suppl):182-187.
3. Rabinowitz YS, Li X, Ignacio TS, Maquen E. Intacs inserts using the femtosecond laser compared to the mechanical spreader in the treatment of keratoconus. *J Refract Surg.* 2006;22(8):764-767.
4. Carrasquillo KG, Rand J, Talamo JH. Intacs for keratoconus and post-LASIK ectasia: mechanical versus femtosecond laser-assisted channel creation. *Cornea.* 2007;26(8):956-962.