

# Severely Subluxated Pediatric Cataract in an Eye With Aniridia and Glaucoma

BY AMAR AGARWAL, MS, FRCS, FRCOPHTH

**M**y most difficult cataract case involved a host of complexities and the need for a solution that would last for decades.

## HISTORY

I had gone to Mumbai, India, to deliver a lecture and perform live surgery of a glued IOL, a technique I began using in 2007.<sup>1-4</sup> After my lecture, an ophthalmologist from that region approached me and said he had a pediatric patient with a badly subluxated cataract, which was complicated by aniridia and glaucoma. He wanted to refer the case to me. I agreed to see the patient. On my flight home, I wondered how I might approach such a complex case.

The 8-year-old child and his parents came to see me in Chennai, India. When I examined the child, I was shocked. The cataract was badly subluxated, and aniridia was evident (Figure 1). The IOP was 35 mm Hg. The boy's other eye had the same problems. After a thorough examination, I prescribed antiglaucoma medications to reduce the patient's IOP.

## OPTIONS

Obviously, I could not leave the child as he was. His vision was counts fingers at 1 meter, and he had glaucoma. I could perform glaucoma surgery and remove the cataract after explaining to his parents that he would have to wear thick, aphakic glasses for the rest of his life. This was not an ideal solution.

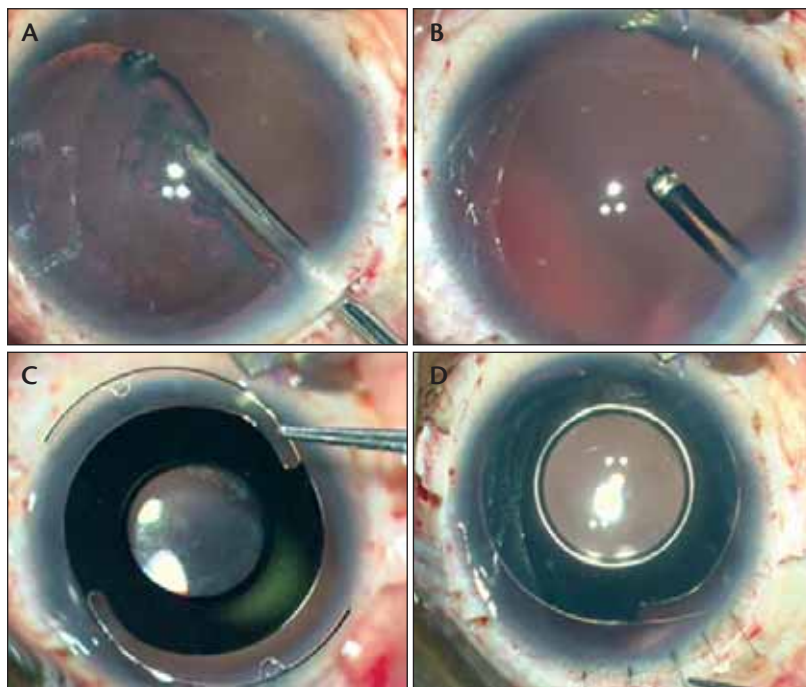
I did not want to suture an IOL to the sclera in the eye of a child. My concerns about scleral fixation were amplified, because the sutures would have to hold for

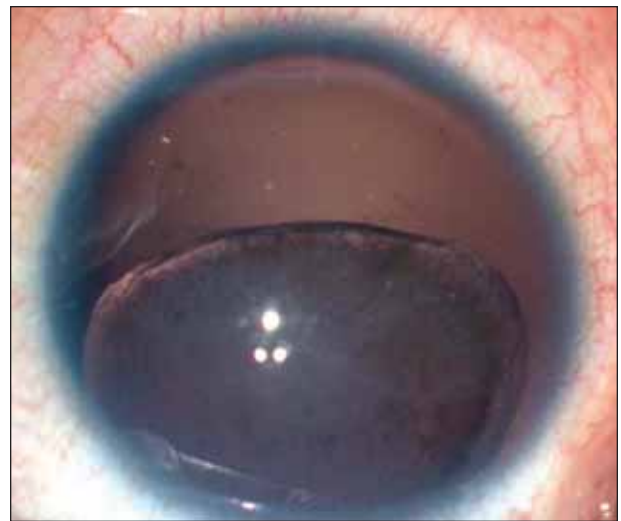

Figure 1. Congenital aniridia with a subluxated cataractous lens.

at least 60 years. Neither an iris-fixated IOL (an iris claw lens or a PCIOL sutured to the iris) nor an ACIOL was an option because of the child's aniridia.

I could remove the cataract and place a Cionni Ring for Sclera Fixation (Morcher GmbH, Stuttgart, Germany; distributed in the United States by FCI Ophthalmics, Marshfield Hills, MA). Then, I could perform a trabeculectomy and try to implant a PCIOL in the bag. The massive subluxation of the crystalline lenses eliminated this option as well as the use of an Ahmed Capsular Tension Segment (Morcher GmbH, Stuttgart, Germany; distributed in the United States by FCI Ophthalmics, Inc., Marshfield Hills, MA) or the



**Figure 2.** The surgeon performs a lensectomy (A). The lensectomy is complete. Note the aniridia (B). The PMMA aniridia implant (C). The IOL is well centered at the end of surgery (D).

AssiAnchor (not available in the United States; Hanita Lenses, Kibbutz Hanita, Israel).

None of the strategies I considered would address the patient's aniridia or the glare and discomfort the child would experience postoperatively.

### **SURGICAL PLAN**

I explained the limited options to the patient's parents. I told them I planned to address their son's glaucoma surgically. I would remove the cataract and perform a vitrectomy (Figure 2A and B). Finally, in an effort to address the boy's aphakia and aniridia, I would fixate with glue an aniridic IOL to the sclera.

I chose a PMMA aniridia IOL (Figure 2C), specifically the OV lens (model ANI5; Intra Ocular Care, Gujarat, India). The overall diameter of the implant is about 12.75 mm. The optic has a central clear zone of about 5 mm with a peripheral opaque or pigmented annulus of approximately 9.5 mm. The haptics are also made of PMMA.

### **SURGICAL COURSE**

I created two partial-thickness scleral flaps of about 2.5 X 3.0 mm that were exactly 180° apart diagonally. I used an infusion cannula for fluid, but the procedure can also be performed with a 23-gauge sutureless trocar infusion can-

nula. I created a third scleral flap for the trabeculectomy. Next, I made a scleral tunnel incision between the flaps and completed the lensectomy to remove the subluxated cataractous lens (Figure 2A and B) with the vitrectomy cutter. I performed an anterior vitrectomy to relieve any traction on the vitreous. I created two straight sclerotomies with a 20-gauge needle under the existing scleral flaps and used a sharp keratome to enlarge the scleral tunnel incision.

With a McPherson forceps, I introduced the PMMA aniridia implant through the limbal incision. I passed an end-gripping 23-gauge microcapsulorhexis forceps (MicroSurgical Technology, Redmond, WA) through one of the sclerotomies to hold the tip of the haptic. I then externalized both of the haptics under each of the scleral flaps. I closed the scleral tunnel with 10-0 monofilament nylon sutures. Next, I made a scleral tunnel with a 26-gauge needle at the point of the haptic's externalization and tucked it into the intra-

lamellar scleral tunnel (Figure 2D). After closing both of the scleral flaps with fibrin glue (Tisseel glue; Baxter Healthcare Corporation, Glendale, CA), I performed the trabeculectomy. I then sutured the trabeculectomy scleral flap.

I removed the infusion cannula and apposed the conjunctiva with fibrin glue.

### **OUTCOME**

The patient did very well postoperatively. The IOL remained in place, and the IOP was well controlled at 18 mm Hg. Six months postoperatively, I saw the child and the happiness on his face and his parents', too. The boy was now able to go to school. They were all comparing the vision of the operated eye and unoperated eye and could not believe the difference. The parents wanted me to proceed with surgery on their son's second eye immediately.

### **GLUED IRIS PROSTHESIS: A NEW TREATMENT FOR ANIRIDIA**

An intact iris diaphragm is essential, because it decreases spherical and chromatic aberrations arising from the lens. The symptoms of aniridia range from decreased vision to optical disturbances such as glare and photophobia due to excess light. Eyelid surgeries, colored contact lenses, scleral suture-fixated prostheses, foldable

“My hope is that [the glued iris prosthesis] technique will help patients such as the one described herein see better.”

artificial irides, and corneal tattooing are widely used to improve patients' symptoms. Contact lenses must be removed periodically, and a scleral suture-fixated IOL can be associated with postoperative hypotony, inflammation, and cystoid macular edema. A glued iris prosthesis avoids these problems.<sup>1-4</sup>

The procedure can be performed on eyes with traumatized corneas that have any grade of scarring, a contraindication for contact lenses. Moreover, the incidence of uveitis-glaucoma-hyphema syndrome is far lower than with a scleral suture-fixated IOL, a sulcus-fixated prosthesis, or an artificial iris.<sup>4</sup>

The placement of a glued iris prosthesis may be combined with other surgeries such as penetrating keratoplasty, trabeculectomy, and pars plana vitrectomy.

I wish I could say I had invented the glued IOL technique, but I must credit divine inspiration. My hope is that this technique will help patients such as the one described herein see better.

Section editor David F. Chang, MD, is a clinical professor at the University of California, San Francisco. Dr. Chang may be reached at (650) 948-9123; [dceye@earthlink.net](mailto:dceye@earthlink.net).

Amar Agarwal, MS, FRCS, FRCOphth, is the director of Dr. Agarwal's Group of Eye Hospitals in Chennai, India. He acknowledged no financial interest in the products or companies mentioned herein. Professor Agarwal may be reached at +91 44 2811 6233; [dragarwal@vsnl.com](mailto:dragarwal@vsnl.com).



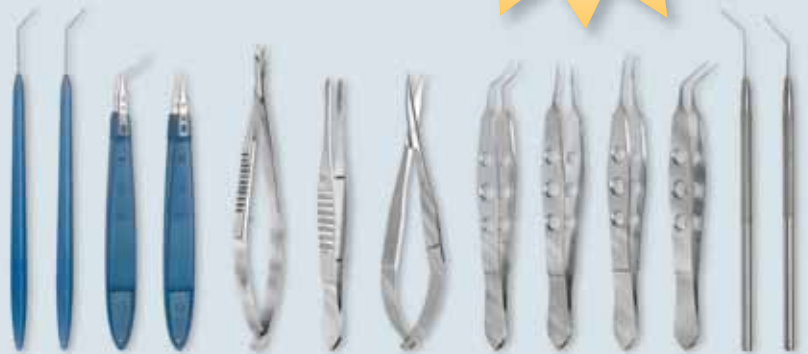1. Agarwal A, Kumar DA, Jacob S, et al. Fibrin-glyce assisted sutureless posterior chambre intraocular lens implantation in eyes with deficient posterior capsules. *J Cataract Refract Surg.* 2008;34:1433-1438.
2. Prakash G, Kumar DA, Jacob S, Kumar KS, et al. Anterior segment optical coherence tomography-aided diagnosis and primary posterior chamber intraocular lens implantation with fibrin glue in traumatic phacocoele with scleral perforation. *J Cataract Refract Surg.* 2009;35:782-784.
3. Prakash G, Jacob S, Kumar DA, et al. Femtosecond assisted keratoplasty with fibrin glue-assisted sutureless posterior chamber lens implantation: a new triple procedure. *J Cataract Refract Surg.* 2009;35(6):973-979.
4. Kumar DA, Agarwal A, Prakash G, et al. Glued posterior chamber IOL in eyes with deficient capsular support: a retrospective analysis of 1-year post-operative outcomes [published online ahead of print: February 12, 2010]. *Eye (Lond).* PMID:20150926.

## BD Visitec™

Meeting the Needs of Ophthalmic Surgery

Visit us at  
ASCRS BOOTH  
#1121

Introducing our expanded family of instruments



Single-Use Instruments and Cannulae  
Designed with Safety in Mind

Single-use instruments and cannulae designed to reduce the risk of TASS and to eliminate the need of flash sterilization.

**Protection | Performance | Simplicity**

BD, BD Logo and all other trademarks are property of Becton, Dickinson and Company. © 2010 BD



**BD Medical**  
Ophthalmic Systems  
411 Waverley Oaks Road  
Waltham, MA 02452  
Tel: 781.906.7900 or  
866.906.8080  
[www.bd.com/ophthalmology](http://www.bd.com/ophthalmology)