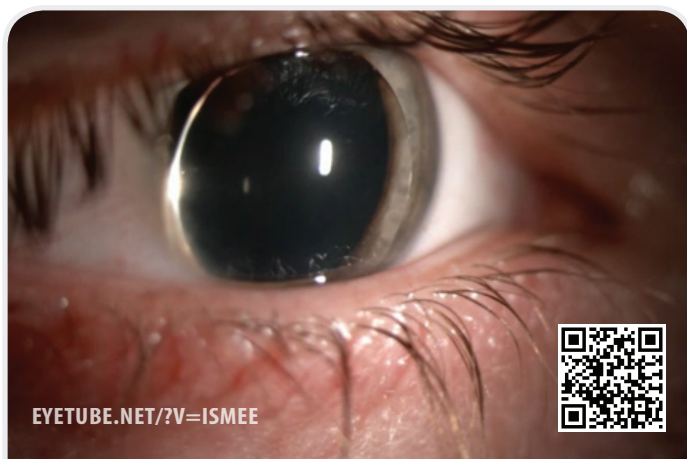


THIS MONTH ON EYETUBE.NET

Surgical Management of a Dislocated Crystalline Lens to the Anterior Chamber

BY BARTLOMIEJ J. KALUZNY, MD, PhD

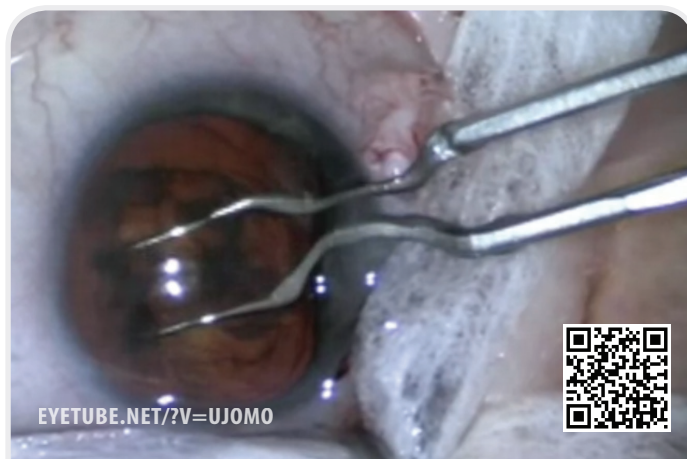


EYETUBE.NET/?V=ISMEE



Single-Incision Phacoemulsification With the Akahoshi PreChopper

BY THANOS PAPAKOSTAS, MD, AND KENNY CHANG, MD

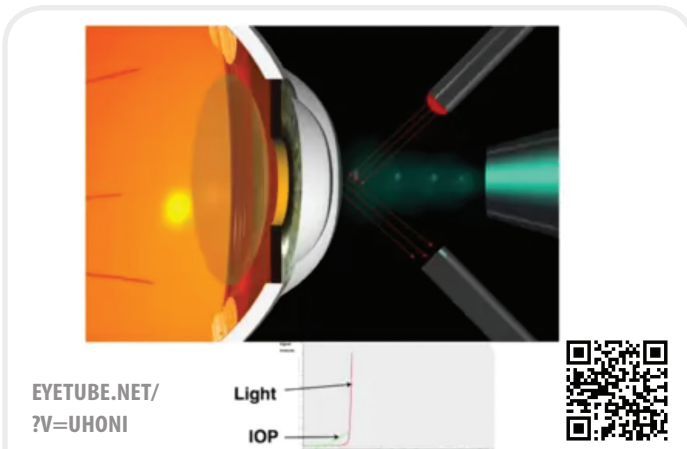


EYETUBE.NET/?V=UJOMO



Quick Guide to Keratoconus Management

BY MAZAN SINJAB, MD



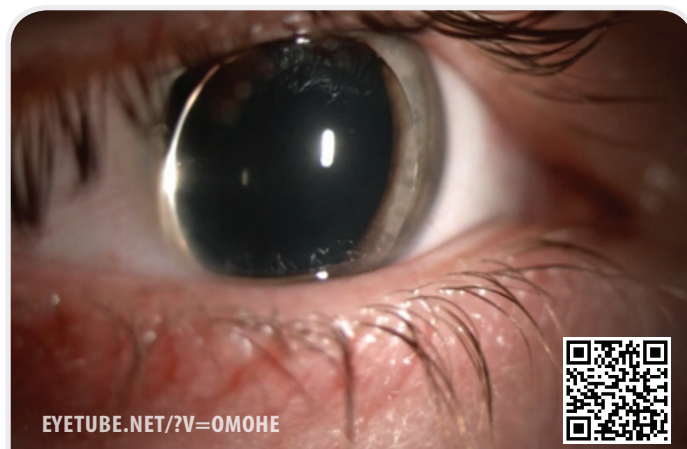EYETUBE.NET/
?V=UHONI

Light
IOP



IOL Cutter and Holder to Trim a Glaucoma Tube Shunt in the Anterior Chamber

BY ALBERT KHOURI, MD



EYETUBE.NET/?V=OMOHE

