

# Cataract & Refractive Surgery TODAY

June 2006

# OZIL

## TORSIONAL: A NEW ERA IN PHACOEMULSIFICATION

TECHNOLOGY OVERVIEW

---

SURGICAL APPLICATION

---

PATIENT OUTCOMES  
& CLINICAL DATA

# OZIL

## TORSIONAL: A NEW ERA IN PHACOEMULSIFICATION

Torsional ultrasound is a revolutionary new phacoemulsification technology that produces a side-to-side motion of the phaco tip as opposed to the forward-and-backward motion of traditional longitudinal ultrasound. The OZil torsional technology is only available on the Infiniti Vision System (both from Alcon Laboratories, Inc., Fort Worth, TX), either incorporated with all new consoles or as an upgrade to existing systems available for purchase. This monograph is based on an evening symposium held at the San Francisco Museum of Modern Art during the 2006 ASCRS meeting at which practiced surgeons shared their experiences with and insights into this new OZil torsional phacoemulsification technology.

# CONTENTS

---

## 4 THE OZIL TORSIONAL PHACOEMULSIFICATION TECHNOLOGY

An overview and study results.

BY DAVID ALLEN, BSc, FRCS, FRCOPHTH

## 7 TRANSITIONING TO TORSIONAL PHACOEMULSIFICATION

Initial experience and learning curve with the OZil torsional ultrasound technology.

BY SONIA H. YOO, MD

## 9 TAILORING CATARACT LENS REMOVAL

How AquaLase and torsional ultrasound transform modern surgical techniques.

BY ROBERT J. CIONNI, MD

# CONTRIBUTORS

---



*David Allen, BSc, FRCS, FRCOPHTH, is a consultant ophthalmologist specializing in cataract surgery in Sunderland, England. He has received reimbursement from Alcon Laboratories, Inc., for travel and lodging but acknowledged no financial interest in the products or company mentioned herein. Mr. Allen may be reached at +44 191 5699071; david@allen50fsnet.co.uk.*



*Sonia H. Yoo, MD, is Associate Professor of Clinical Ophthalmology at Bascom Palmer Eye Institute, University of Miami School of Medicine, Florida. She has received travel and research grants from Alcon Laboratories, Inc. She is a clinical investigator for Intralase Corp. and Advanced Medical Optics, Inc. Dr. Yoo may be reached at (305) 326-6322; syoo@med.miami.edu.*



*Robert J. Cionni, MD, is Medical Director of the Cincinnati Eye Institute in Ohio. He is a paid consultant for Alcon Laboratories, Inc., but acknowledges no direct financial interest in the products or company mentioned herein. Dr. Cionni may be reached at (513) 984-5133; rcionni@cincinnati-eye.com.*

# The Ozil Torsional Phacoemulsification Technology

## An overview and study results

BY DAVID ALLEN, BSC, FRCS, FRCOPHTH

The OZil torsional handpiece on the Infiniti Vision System (Alcon Laboratories, Inc., Fort Worth, TX) is, I think, the future of phacoemulsification. There has been quite a lot of buzz about torsional phacoemulsification since it was unveiled at the 2005 ESCRS meeting in Lisbon, Portugal. There is increasing evidence that cavitation is not a significant factor in how phacoemulsification works and that traditional longitudinal phacoemulsification operates by a physical jackhammer effect on the nucleus.<sup>1</sup> It is important to note that it is on the backstroke of the tip when voids or cavitation bubbles are formed. The collapse of these bubbles occurs when pressure increases as the tip starts to move back toward the lenticular material. Accepting this information as an initial premise, it is quite clear that traditional longitudinal phacoemulsification is inefficient in two ways. First, it constantly pushes the nuclear material away by the jackhammer effect into the lenticular material. Second, it performs effectively only half of the time, because it emulsifies material just on the forward stroke. On the backward stroke, the tip only pulls away from the nuclear material.

### MECHANICS

The OZil torsional handpiece has been designed so that its piezoelectric crystals produce two different effects. At 32kHz, the crystals induce a torsional (oscillatory) movement in the shaft of the phaco needle. If the needle has the Kelman configuration, with a 22° angulation near the tip, a small degree of torsion in the shaft is amplified to a greater side-to-side movement at the tip

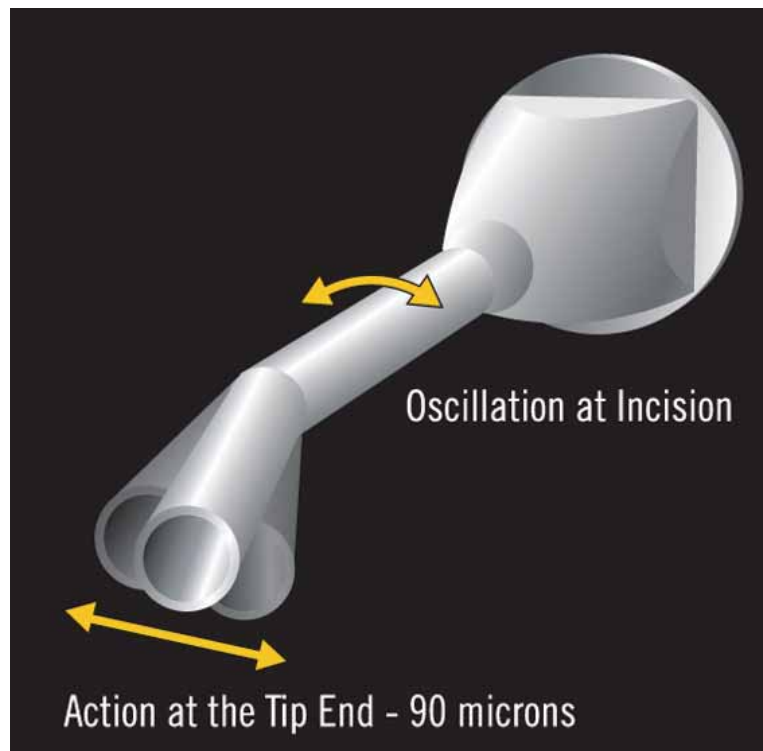


Figure 1. Rotating the shaft of the Kelman-style phaco needle to a small degree produces much larger movement at the tip's cutting edge with torsional phacoemulsification.

(Figure 1). At 44kHz, the crystals move the phaco tip in the traditional linear fashion. In addition, the Infiniti software allows the surgeon to combine torsional and longitudinal movements in different ratios and sequences.

Torsional phacoemulsification greatly reduces the repulsion of nuclear material from the phaco tip. Less repulsion at the tip means that the lenticular material stays on the tip and the tip therefore is kept in an occluded or

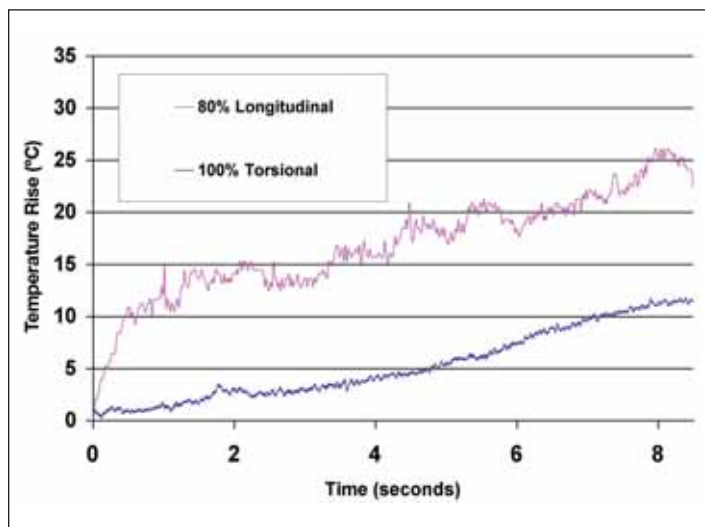


Figure 2. This graph shows the change in incision temperature with continuous torsional and traditional phacoemulsification in conditions of no flow.

nearly occluded state. This greater occlusion in turn decreases turbulence in the anterior chamber and increases the efficiency of the lens' removal. The shearing action of the tip makes it more efficient in removing material, because each side-to-side movement emulsifies material. In contrast, only the forward movement of longitudinal phacoemulsification is effective.

When working with this technology, I found that very dense, brunescient nuclei would occasionally clog the needle. This observation illustrates the fact that the movement in longitudinal phacoemulsification does produce some beneficial clearing action of hard material inside the needle. For dealing with such very dense nuclei, I therefore recommend combining a small degree of longitudinal phacoemulsification with the torsional. If some longitudinal is selected, the software automatically provides 20 milliseconds of longitudinal and 80 milliseconds of torsional power. This combination allows the surgeon to deal with hard nuclei in a dramatically more efficient way than with purely longitudinal ultrasound.

#### TEMPERATURE CONTROL

Traditional phacoemulsification is not only inefficient, but it also can generate a significant buildup of thermal energy at the incision. Torsional phacoemulsification appears to be quite different. Figure 2 shows the temperature rise seen at the incision's surface between longitudinal and torsional ultrasound in a wet lab study. The incision was sealed with glue, and the study was conducted under conditions of no inflow or outflow

through the needle or sleeve. The temperature at the upper surface of the cornea with 80% longitudinal phacoemulsification rose by 12°C (approximately 53°F) within 1 second. It takes 9 to 10 seconds for torsional phacoemulsification to reach the same temperatures. In similar studies I conducted, I found it almost impossible to deliberately cause an incisional burn in a pig eye with torsional ultrasound, despite decentering the phaco tip by pressing tightly against the roof of the incision to increase frictional contact within the sleeve and cornea.

The reason for this difference in temperature between the two technologies is the reduced amount of movement of the phaco needle in the incision with torsional power. With the Infiniti, longitudinal ultrasound at 100% power generates a linear stroke length of approximately 90µm. The lateral or side-to-side movement of the tip in 100% torsional phacoemulsi-

fication is also approximately 90µm. However, because of the geometry of the Kelman tip, the rotational movement of the shaft at the incision is only half that (Figure 1). Torsional ultrasound therefore produces half the movement of traditional phacoemulsification within the incision and also oscillates at a lower frequency than traditional longitudinal (32 versus 40kHz). The total effect of this lower frequency is that the amount of frictional movement against the cornea per second (and therefore of heat generation) is roughly one-third that of longitudinal phacoemulsification.

### Torsional phacoemulsification greatly reduces the repulsion of nuclear material from the phaco tip.

#### ALTERING FLUIDICS AND BSS USAGE

Ophthalmologists have recently become accustomed to using very high vacuum and flow rates with machines that feature the superb fluidics characteristics of the Infiniti Vision System. Now that there is a modality that is less repulsive than traditional longitudinal phacoemulsification, do ophthalmologists need to continue using these high vacuum rates?

In order to explore this idea, I used torsional ultrasound

for a case in which I set the vacuum at my normal level (fairly low for the Infiniti) of 450mmHg. As I expected, it removed the nuclear quadrant quite effectively. Then, on a different quadrant of the same nucleus, I lowered the vacuum to 350mmHg. The emulsification was just as efficient and rapid. Therefore, I concluded that we no longer are compelled to use the high vacuum and flow rates that have made our modern phaco technique effective. We can be even more efficient with torsional phacoemulsification at lower settings. This aspect of torsional phacoemulsification's parameters means that it is potentially the ideal technology to harness micro-coaxial cataract techniques. The main issue with that technique is the potential for postocclusion surge that arises from the reduced inflow caused by reducing the size of the phaco sleeve. We can now use lower vacuum levels without a loss of efficiency with torsional ultrasound to address the issue of surge.

**I really do think that torsional ultrasound is the future of phacoemulsification, and I do not believe there is any reason to continue using traditional longitudinal ultrasound alone.**

I searched for ways of demonstrating the effectiveness of the OZil handpiece technology objectively and eventually tried measuring the flow of BSS through the eye during nuclear removal. Using a precision balance from which I suspended the irrigating bottle, I conducted a small pilot study of the weight (as a proxy for volume) of BSS I used in removing the nucleus with standard longitudinal phacoemulsification. Using these data, I performed statistical power calculations and showed that a study with 38 patients per group would have the power to demonstrate a 20% difference in the amount of BSS used. I performed a series of cases in which I randomly assigned each surgery to either torsional or longitudinal phacoemulsification. I

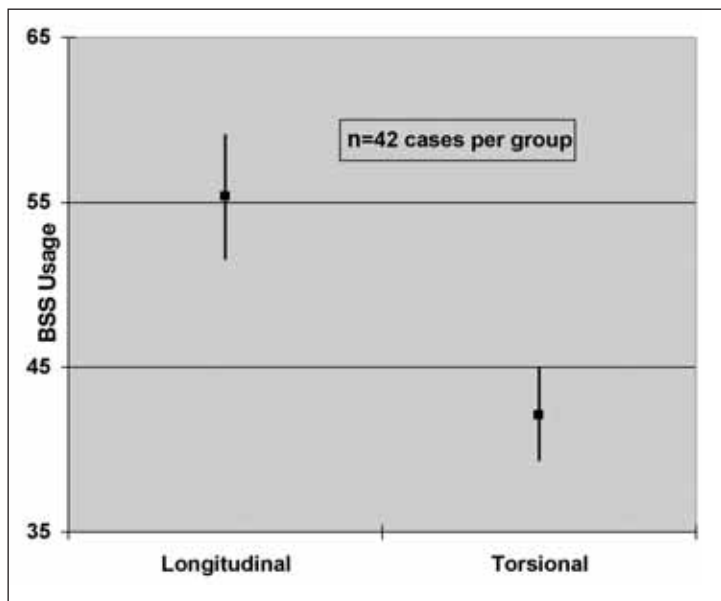


Figure 3. Weight measurements show a 20% difference in balanced salt solution used between torsional cases and longitudinal cases.

used the same fluidic settings in all cases. After executing 42 cases in each group, it was clear that there was 23% less BSS used with torsional phacoemulsification compared with longitudinal<sup>2</sup> (Figure 3). Although I have yet to demonstrate a clinical impact (such as reduced endothelial cell loss or diminished corneal thickening on POD1) of what is statistically a significant decrease, I believe that any technique that reduces both the turbulence and the volume of fluid going through the anterior chamber and bathing the corneal endothelium must be advantageous.

#### IN SUMMARY

I would summarize torsional phacoemulsification in this way: It works; there is absolutely no question about that. It can be used for all grades of cataract, even very dense ones. The densest cataracts respond best to a combination of torsional and longitudinal ultrasound, a pairing that works as smoothly as torsional phacoemulsification alone. The OZil technology is very smooth and effective on a clinical basis. I believe its efficiency will be further proven with increased experience. I really do think that torsional ultrasound is the future of phacoemulsification, and I do not believe there is any reason to continue using traditional longitudinal ultrasound alone. ■

1. Zacharias J. Jackhammer or cavitation: the final answer. Video presented at: The ASCRS Film Festival; March 17-22, 2006; San Francisco, CA.

2. Allen D. Efficient surgery with a new torsional phaco mode. Paper presented at: The ASCRS/ASOA 2006 Symposium & Congress; March 18, 2006; San Francisco, CA.



# Transitioning to Torsional Phacoemulsification

## Initial experience and learning curve with the OZil torsional ultrasound technology

BY SONIA H. YOO, MD

My colleagues and I had a great experience with the torsional phacoemulsification technology when studying its efficiency versus longitudinal ultrasound. It was an easy transition for me as someone who was used to using the Infiniti Vision System (Alcon Laboratories, Inc., Fort Worth, TX) with the 1.1-mm flared tip and conventional longitudinal phacoemulsification. With torsional ultrasound, I made a few changes to my surgical technique that I describe herein.

I was fortunate to receive the torsional upgrade on my Infiniti phacoemulsification system in November 2005. The first change I had to make from longitudinal phacoemulsification was to switch from my usual 1.1-mm flared tip to the 0.9-mm tapered, angled tip. The latter tip and sleeve design allowed me to decrease the size of my wound from 2.8 to 2.6mm. Also, I was used to employing pulse or burst mode to emulsify quadrants in longitudinal ultrasound; in torsional ultrasound, I was able to use a continuous mode. With longitudinal ultrasound, pulse or burst settings are used to overcome the repulsion of phaco energy to regain purchase of lenticular material. In contrast, torsional ultrasound does not create the same kind of repulsive forces at the tip. The surgeon may therefore use continuous ultrasound, which results in the more efficient removal of lenticular material with less chatter of nuclear fragments at the tip.

### EARLY EXPERIENCE

One of my early torsional phaco cases was a monocular patient with a dense cataract who had had problems with postoperative endophthalmitis in her first eye. Despite her anterior chamber's being somewhat shallow, I was easily able to enter the 2.6-mm wound with the 0.9-mm angled tip. I appreciated how the tip's angulation helped me to stay deep in the groove without having to torque the incision. I could sculpt narrowly and crack the nucleus easily. I

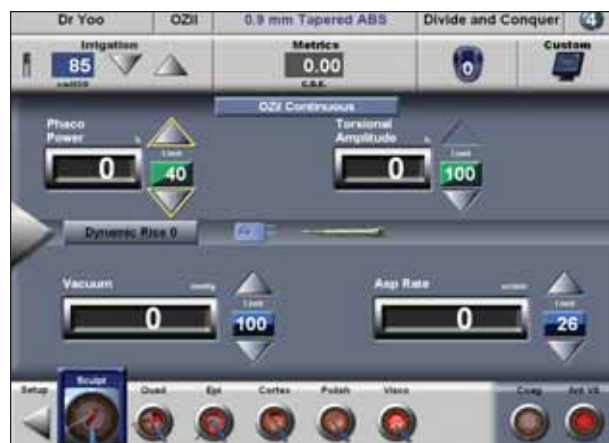

Figure 1. This image shows Dr. Yoo's settings when she combined traditional ultrasound with torsional on a dense lens.

had a nice view without getting striae from the corneal wound from torquing it. I had to make a few more passes than I was used to for my initial sculpting, but the OZil handpiece cut very nicely.

Another small change I made with torsional ultrasound involved the fluidics. In longitudinal ultrasound with a 1.1-mm tip, I would usually go to the top of foot position 3 and give a little burst of ultrasound to engage the first nuclear piece. Then, I would go to the bottom of foot position 2, let vacuum build, and then pull the quadrant toward me. Because torsional ultrasound starts emulsifying right away and allows me to stay in continuous mode, I simply turned the tip, buried it into the quadrant, and held it at the bottom of foot position 2 so that I could get good purchase. Then, I brought the quadrant to the center of the pupil, stepped deep into foot position 3, and emulsified the lenticular material. I did not see a lot of chatter or have fragments coming to the paracentesis site, nor did I have to chase pieces of

lens around the anterior chamber.

Because I now use an angled tip and have little or no torquing of the irrigation sleeve within the incision, I induced no irrigation leakage, and I could fully occlude the mouth of the phaco needle, build vacuum, get good purchase on the lenticular material, and bring it to the center of the pupil.

On one of my next torsional cases, I had an extremely dense cataract that had reduced the patient's vision to hand motion. I used trypan blue to stain the anterior capsule and a pupil expander to open the pupil. Initially, I saw a little bit of lens "milk," which is occasionally observed with torsional phacoemulsification on dense cataracts. It likely represents liquified lenticular material around the dense lens nucleus. Even with this dense cataract, the torsional ultrasound cut reasonably well. I then used some longitudinal ultrasound in conjunction with the torsional ultrasound, a combination that let me cut a little more effectively (Figure 1). Any procedure that stretches the pupil includes a risk that the pupil will be pulled to the tip of the phaco needle, but torsional ultrasound helps to decrease turbulence in the anterior chamber. Additionally, fully occluding the lenticular material with the tip and keeping the needle in the center of the pupil will reduce the frequency with which the iris comes to the phaco needle.

## **Torsional phacoemulsification appears to be a very safe and effective method of cataract removal. Patients' postoperative vision and cell counts were excellent.**

### **STUDY**

#### **Parameters**

I conducted a study of 25 eyes that underwent cataract surgery with torsional ultrasound between November 2005 and February 2006. I examined the eyes pre- and postoperatively and studied their IOP, the endothelial cell counts, the grade of cataract, adverse events, the time of surgery, and how much BSS was used. I preoperatively noted any pre-existing conditions and potential acuity measurements.

I used a 30° 0.9-mm Kelman phaco needle. Most of the cataracts that were extracted were of 2+ density, although the spectrum ranged from trace cataracts for refractive

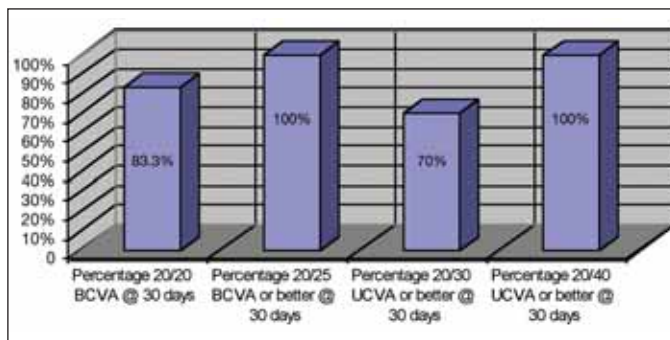


Figure 2. Dr. Yoo's visual acuity results at 30 days postoperatively.

lens surgery all the way to dense, 4+ nuclear cataracts. The data were skewed by one patient who required a vitrectomy. The total OR time was 17 minutes on average.

### **Results**

Patients' visual acuities were quite good. At 30 days, 83% of participants had 20/20 BCVA, and 100% had 20/25 (Figure 2). UCVA scores at 30 days were 70% at 20/30 and 100% at 20/40 or better. The case that required an anterior vitrectomy involved a posterior capsular rent. The eye had a 4+ nuclear sclerotic cataract that required a combination of conventional and torsional ultrasound. The eye did well postoperatively and had a final visual acuity of 20/25. The study group experienced no other adverse events or complications.

On average, I used 268mL of BSS intraoperatively, which is less than what is typically used with conventional longitudinal ultrasound. Torsional phacoemulsification's smaller wound and tighter seal translates to less torque on the wound, which allows fluid to remain in the eye. Postoperatively, there was very little anterior chamber inflammation. Postsurgical endothelial cell counts were 2,790 on average, with an average decrease of 117 at 30 days. Those counts seem to be commensurate with other phaco modalities.<sup>1</sup>

### **CONCLUSION**

Torsional phacoemulsification appears to be a very safe and effective method of cataract removal. Patients' postoperative vision and cell counts were excellent and on par with other phaco modalities my colleagues and I have studied. The total use of intraoperative fluid with this technology appeared to be less than with conventional ultrasound. That decrease may preserve cell counts postoperatively, because increasing volumes of fluid irrigated through the eye likely adversely affects endothelial cell counts postoperatively. ■

1. Sobottka Ventura AC, Wälti R, Böhnke M. Corneal thickness and endothelial density before and after cataract surgery. *Br J Ophthalmol.* 2001;85:18-20.



# Tailoring Cataract Lens Removal

## How AquaLase and torsional ultrasound transform modern surgical techniques

BY ROBERT J. CIONNI, MD

When working with presbyopia-correcting IOLs or any kind of refractive IOL surgery, I certainly want to ensure that my patients achieve the best possible outcomes. They expect to see beautifully on the first day after surgery. Refractive lens surgery demands delicacy within the eye, a low amount of fluid, and minimal turbulence for a successful outcome and a happy patient.

Torsional phacoemulsification gives us surgeons the ability to better customize technologies to our patients' needs. With this new ultrasound technology and the AquaLase liquefaction device (Alcon Laboratories, Inc., Fort Worth, TX), available on the Infiniti Vision System (Alcon Laboratories, Inc.), we have the ability to tailor our surgical approach to suit each specific surgical case.

### THE RIGHT TECHNOLOGY FOR THE JOB

As a consultant for Alcon, I have worked for many years with AquaLase, which I believe is the best technology for removing soft nuclei. Certainly, it is possible to remove a soft lens with ultrasound, but why shoot a sparrow with an elephant gun? AquaLase and the prechop technique can remove a soft cataractous lens more efficiently and with a greater degree of safety than ultrasound without risking a poor outcome. The smooth polymer tip allows the surgeon to work deep within the capsular bag because it is much less likely to break the posterior capsule. It also offers good followability, especially with soft nuclei. However, AquaLase does require some mild alterations to one's surgical technique.

I do not advocate using AquaLase in dense nuclei. I

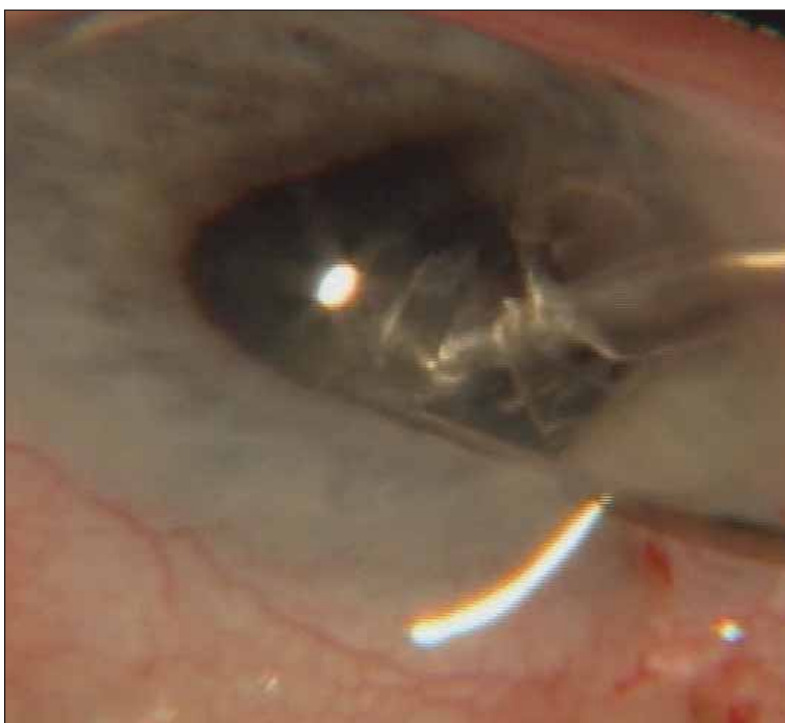


Figure 1. The author demonstrates the followability and safety of using torsional ultrasound in an eye with an iris made floppy by the use of Flomax.

**“Torsional phacoemulsification gives us the ability to better customize technologies to our patients’ needs.”**

believe ultrasound is still the best technology available for these types of cataracts, yet we now know that the longitudinal motion of the ultrasound tip emulsifies material only 50% of the time and encourages repulsion. The resultant turbulence can lead to endothelial

damage. To decrease chatter and the risk of wound burn, manufacturers added power modulations to their traditional phaco software. With torsional ultrasound, such modulations are possible, but I consider them unnecessary.

#### EXPERIENCE WITH TORSIONAL ULTRASOUND

I have had the OZil torsional ultrasound prototype unit (Alcon Laboratories, Inc.) for well over 1 year, and I have come to enjoy it tremendously. Approximately half the cataract surgeries I perform involve medium density nuclei. Torsional phacoemulsification provides wonderful sculpting capabilities with this type of cataract. I increase the amplitude a little higher than I do with longitudinal phacoemulsification, but the actual amount of thermal energy or power delivered is approximately 33% to 40% that of longitudinal at the same power level based on studies in which I was involved at Alcon Laboratories, Inc. Then, I use a small burst of energy when I grab hold of the nucleus before dividing it into quadrants. Torsional ultrasound permits lower vacuum levels than longitudinal because it does not generate a repulsive force. Each quadrant rapidly disappears into the 0.9-mm angled Kelman-style tip without chatter or the need to chase nuclear fragments around the anterior chamber. It greatly simplifies surgery and almost feels like cheating.

#### **“Even with a dense lens, I can use 100% torsional ultrasound with no longitudinal.”**

I conducted a small study looking at fluid usage and the cumulative delivered energy (CDE) with torsional ultrasound. CDE is the average phaco power that either longitudinal or torsional ultrasound brings into the eye multiplied by the duration of time. I evaluated consecutive uncomplicated phaco cases and found that the CDE was approximately 30% higher with longitudinal than with torsional ultrasound. Torsional ultrasound's lower CDE is due to the decreased power that it puts into the eye compared with longitudinal, because the time for complete nuclear emulsification was slightly longer with torsional. I also used less BSS with torsional ultrasound. Many surgeons believe, as I do, that less fluid through the eye results in less endothelial trauma.

#### **“Torsional phacoemulsification is for every surgeon.”**

#### APPLICATIONS

Even with a dense lens, I can use 100% torsional ultrasound and no longitudinal. With a very dense lens, however, I might add perhaps 20% longitudinal power, especially during sculpting, to provide increased cutting efficiency that will help me power through an extremely dense lens. I utilize burst mode just as I am impaling the nucleus, which I then divide into quadrants using low vacuum. While this dense lens is being emulsified, I can see that the followability and lack of turbulence and chatter are quite impressive. Therefore, I do not need to use my second instrument much or move my phaco tip to chase down nuclear pieces that might have chattered away with longitudinal phacoemulsification.

The benefits of torsional phacoemulsification are vividly demonstrated in patients who use Flomax (Boehringer-Ingelheim Pharmaceuticals, Inc., Ridgefield, CT). In many eyes of such patients, the pupil grows smaller and is especially flaccid. Torsional ultrasound's phenomenal followability allows me to stay in the center of the pupil and completely emulsify the nucleus without having to go under the floppy iris and grab fragments. The torsional tip remains still, and I can simply leave it in the middle of the pupil and allow the torsional motion to shear and emulsify the nucleus without repulsion (Figure 1).

#### CONCLUSION

The take-home message about torsional ultrasound is that it offers the following benefits over longitudinal phacoemulsification: less energy; better followability; greater safety because of a lessened risk of wound burn; and ease of use because of less manipulation. Furthermore, it requires no change in the surgeon's technique, and it accommodates any nuclear emulsification approach. Torsional phacoemulsification is for every surgeon.

The ability to utilize AquaLase for soft lenses and torsional ultrasound for dense lenses makes the Infiniti platform a tremendously valuable tool for cataract surgery. The combination of these two technologies helps us ensure the best outcomes for our patients. ■

1. Zacharias J. Jackhammer or cavitation: the final answer. Video presented at: The ASCRS Film Festival; March 17-22, 2006; San Francisco, CA.

**"Torsional phacoemulsification greatly reduces the repulsion of nuclear material from the phaco tip. The shearing action of the tip makes it more efficient in removing material, because each side-to-side movement emulsifies material. In contrast, only the forward movement of longitudinal phacoemulsification is effective."**

—David Allen, BSc, FRCS, FRCOphth

---

**"Any procedure that stretches the pupil includes a risk that the pupil will be pulled to the tip of the phaco needle, but torsional ultrasound helps to decrease turbulence in the anterior chamber."**

—Sonia H. Yoo, MD

---

**"Torsional phacoemulsification gives us the ability to better customize technologies to our patients' needs."**

—Robert J. Cionni, MD

---

**"Torsional phacoemulsification appears to be a very safe and effective method of cataract removal. Patients' postoperative vision and cell counts were excellent."**

—Sonia H. Yoo, MD

**"The take-home message about torsional ultrasound is that it offers the following benefits over longitudinal phacoemulsification: less energy; better followability; greater safety because of a lessened risk of wound burn; and ease of use because of less manipulation."**

—Robert J. Cionni, MD

---

**"I really do think that torsional ultrasound is the future of phacoemulsification, and I do not think there is any reason to continue using longitudinal ultrasound alone."**

—David Allen, BSc, FRCS, FRCOphth

---

**"Torsional phacoemulsification appears to be a very safe and effective method of cataract removal. Patients' postoperative vision and cell counts were excellent."**

—Sonia H. Yoo, MD

---

**"Torsional phacoemulsification allows us to use lower vacuum levels than longitudinal because it does not generate a repulsive force. Torsional ultrasound is so easy to use that I feel like I am cheating."**

—Robert J. Cionni, MD

