

Unocular Patient With Cataract, Inferior Coloboma, and Congenital Microcornea

BY SAMUEL MASKET, MD

When choosing my most difficult cataract case to present for this article, I pondered what case type would constitute “difficult.” Would it be the nature of the individual, perhaps an esteemed colleague, a family member, a close personal friend, or a major celebrity? Would it be a case in which a severe and unexpected complication occurred? Would it be a special surgical challenge, such as a one-eyed patient with several ocular comorbidities who lost the first eye to cataract surgery? Would it be a case that required the use of specialized devices and multiple procedures? Alternatively, would it be the case that caused me the greatest degree of preoperative consternation? I opted for the last criterion, not because the course of surgery or the outcome was complicated, but because I needed to draw on long experience in order to plan for and achieve a successful result.

CASE PRESENTATION

A 79-year-old female was referred to me for consideration of cataract surgery in her left eye. She had bilateral congenital microcornea with extensive inferior colobomata affecting the iris, ciliary body, choroid, and retina. Additionally, she had long-standing glaucoma. As a young adult, her right eye had had better visual acuity than her left eye. She had lost all vision in her right eye to glaucoma 10 years ago, however, following cataract surgery and an eventual corneal transplant. Earlier in her life,

the patient had functioned as a sighted individual and was capable of gainful employment as a schoolteacher, but her vision had never been adequate for her to qualify for a driver’s license. As the visual acuity diminished in her left eye after the loss of acuity in her right eye, the patient gradually began to function as a blind person, who required assistance with most of the activities of daily life. At presentation, the glaucoma in her left eye was being managed with topical agents.

Ocular examination revealed no light perception in her right eye and light perception with projection in her left eye. The IOP measured 25 mm Hg OD and 19 mm Hg OS. Anterior segment findings for the right eye revealed a small, scarred cornea and an absent anterior chamber; scarring was sufficient to preclude a view of the posterior segment. An evaluation of the left eye demonstrated microcornea and an inferior iris coloboma (Figure 1). The

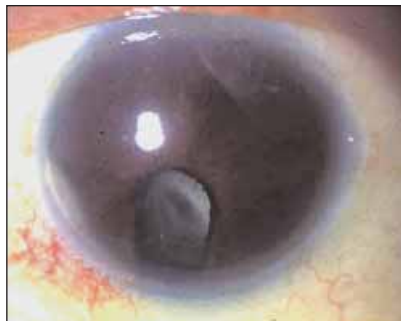

Figure 1. The anterior segment view of the patient’s left eye demonstrates microcornea with an inferior iris coloboma and a mature cataract. The pupil is maximally dilated.

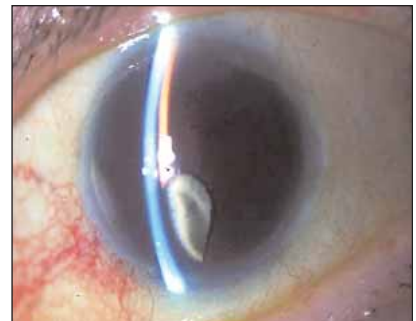

Figure 2. A slit-lamp photomicrograph of the patient’s left eye reveals a very shallow anterior chamber in combination with microcornea, an inferior coloboma, and a mature cataract.

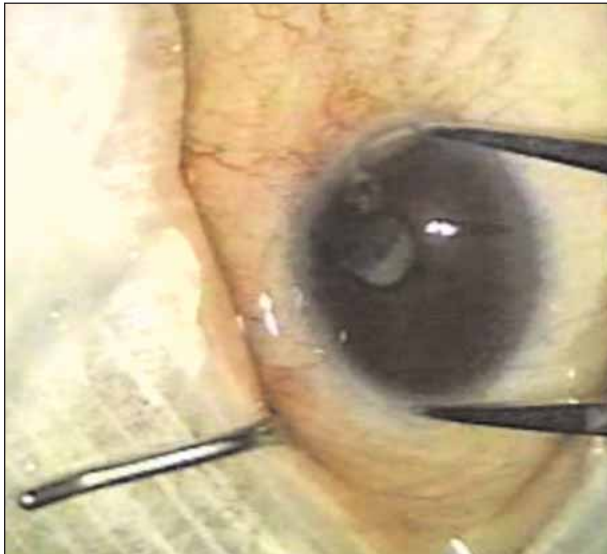


Figure 3. An intraoperative view of the measurement of the corneal diameter.

cornea was clear, and the endothelium appeared to be healthy. The anterior chamber, however, was very shallow (1.6 mm centrally), as shown in Figure 2. The inferior coloboma included the pupillary margin. Pharmacologic dilation was extremely poor but revealed a dense black cataract with minute remnants of white anterior cortex. No view of the posterior segment was possible. B-scan ultrasonography illustrated an attached retina with an inferior coloboma extending to the posterior pole. A full-sized crystalline lens was present.

The patient was hopeful that cataract surgery for her left eye would return her vision and thus the lifestyle that she had previously enjoyed. Based upon her history and no view of the posterior segment, however, I could not accurately predict her visual outcome with even the most successful cataract/IOL procedure. I also had considerable concern about the course of surgery, given the poor outcome for her right eye. She and I spent far more time discussing her predicament than I did performing her examination and surgery. After careful and lengthy consideration of her options, the patient requested surgery under general anesthesia.

When deciding my surgical approach, I considered several factors. One was the small corneal diameter in combination with the severely shallow chamber and full-sized black cataract. Added to my concern was the inferior coloboma with a given degree of absent zonules, although there was no sign of phacodonesis. While phacoemulsification can be accomplished in almost all eyes, I worried about this case. My most significant concern was whether her cornea would survive a phaco procedure.

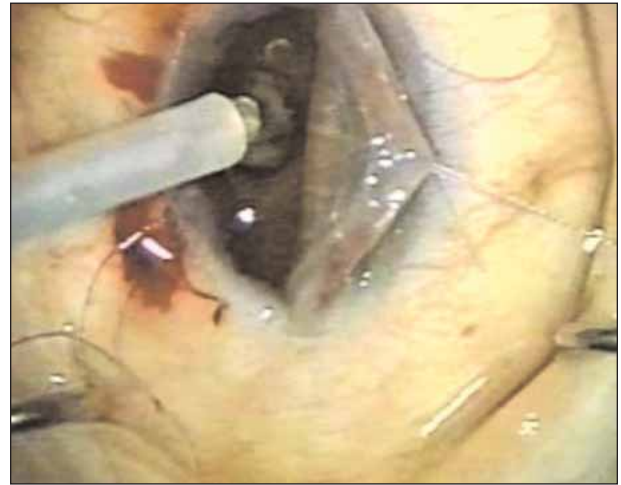

Figure 4. The surgeon applies the cryoprobe to the surface of the cataract through the pupil with the cornea elevated by means of an 8-0 Vicryl traction suture (Ethicon Inc., Somerville, NJ).

In this case, I felt that it was important to limit the operating time, because a prolonged surgery with an open eye would increase the risk of a suprachoroidal hemorrhage.

Another factor was choosing the best strategy for managing the patient's congenital coloboma. Given her dark iris and overall situation, the aesthetic result was not a concern of hers.

Finally, I needed to determine the best way to anchor an IOL should capsular damage occur during surgery. I could not rely on an ACIOL as a backup plan, given the patient's anterior segment anatomy. Iris and scleral suturing would prolong surgery significantly, again risking an

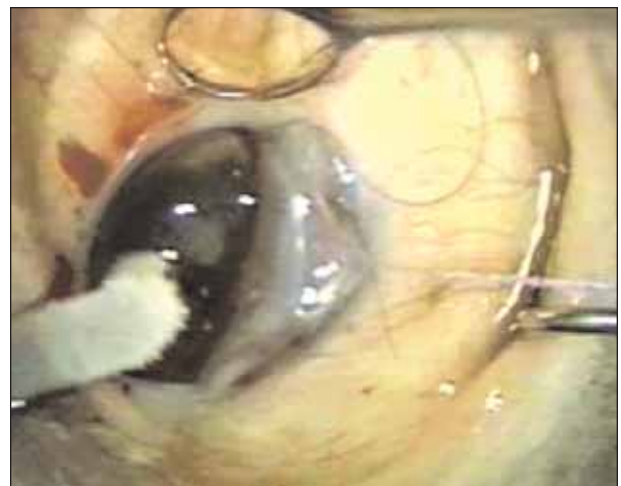

Figure 5. Cryoextraction of the full-sized mature cataract from the small anterior segment.

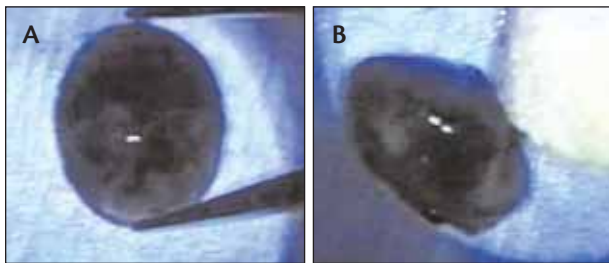


Figure 6. The horizontal diameter of the mature cataract measured 9.0 mm (A). The axial length of the mature cataract was 5.8 mm (B).

intraoperative suprachoroidal hemorrhage.

Biometry relieved my concern regarding the IOL by showing a very steep cornea. The average keratometry reading was approximately 48.50 D. A-scan ultrasonography showed an elongated axial length (24.21 mm), and B-scan ultrasonography ruled out a staphyloma. As a result, the patient required only a +5.00 D PCIOL for emmetropia. Given that finding, I theorized that I could leave the eye aphakic, and she could easily manage the necessary spectacles. With my concern about a prolonged procedure and the fact that she did not require an IOL, the surgical plan became apparent. I would leave the iris alone, leave the eye aphakic, and perform an intracapsular cryoextraction through the inferior coloboma. This plan, I theorized, would allow the eye to be open only briefly and would reduce the surgical time as much as possible.

SURGICAL COURSE

I had some concerns regarding the surgical procedure, namely that I would have to be seated temporarily while removing the large nucleus with a cryoprobe in my non-dominant left hand. I had not used a cryoprobe in many years and had never used the instrument with my left hand.

The cornea measured 8.0 mm vertically and 8.5 mm horizontally (Figure 3). I made a 200° half-thickness vertical groove in the inferior corneal limbus and preplaced two absorbable 8-0 sutures prior to entering the anterior chamber. These sutures gave me a small degree of security about closing the eye rapidly in the case of a suprachoroidal hemorrhage.

Next, I opened the chamber, enlarged the incision to at least 200°, dried the surface of the lens, and applied the cryoprobe (Figure 4). I gently rocked the cataract from side to side and gradually from the eye; the process seemed to take an eternity. The cataract appeared larger than the remaining anterior segment (Figures 5 and 6). The cataract's removal stretched the poorly dilated,

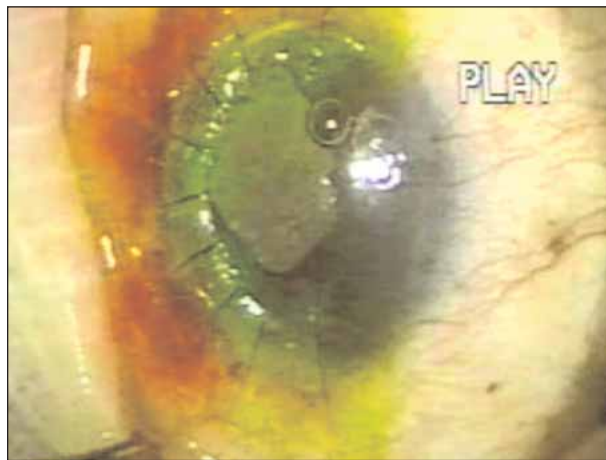


Figure 7. View of the eye at the close of surgery with multiple interrupted 10-0 nylon sutures. The pupil was enlarged inadvertently by the removal of the large, firm cataract.

abnormal pupil but caused no other harm. I quickly tied the preplaced sutures and closed the incision with multiple, interrupted 10-0 nylon sutures, which also replaced the earlier sutures (Figure 7). There were no operative complications. Grossly viewing the large, thick, and ultradense extracted cataract after the surgery (Figure 6) affirmed my decision not to employ phacoemulsification.

OUTCOME

Postoperatively, the patient fared remarkably well, and we more than achieved the targeted visual acuity. Three months after surgery, the patient's UVCA was 20/400 OS, with a BCVA of +2.00 -2.25 X 70 = 20/200. She was able to read large newsprint with a +3.50 D add, and her IOP was 18 mm Hg with the same topical medications she had been taking preoperatively. Postoperative findings included an extensive inferior coloboma, including the optic nerve. Most importantly, however, the patient now functions as a sighted individual.

Although I surely have dealt with many complex cataract situations during my career, I was greatly pleased to make an improvement in this woman's life. I firmly believe that it was best to avoid phacoemulsification in this unusual case. ■

Samuel Masket, MD, is in private practice in Century City, California, and is Clinical Professor of Ophthalmology at the UCLA Geffen School of Medicine, Jules Stein Eye Institute, Los Angeles. He is also past President of the ASCRS. He acknowledged no financial interest in the product or company mentioned herein. Dr. Masket may be reached at (310) 229-1220; avcmasket@aol.com.

