Adult Eyes With a 5.5-mm Corneal Diameter

BY DOUGLAS D. KOCH, MD

It was an interesting challenge to select one of the many tough cases that remain "Velcroed" to my mind. I chose the one presented herein because of the unique anatomy.

CASE PRESENTATION

A 42-year-old female was referred to me for cataract surgery. She had a history of microcornea, nystagmus, and an iris and choroidal coloboma with involvement of the optic nerve. She had developed dense bilateral cataracts.

On examination, her BCVA was count fingers at 1 foot in her right eye and count fingers at 8 feet in her left eye. Pertinent findings included jerk nystagmus, microcornea with a corneal diameter of 5.0 mm OD and 5.8 mm OS, iris and choroidal coloboma involving the optic nerve (in the right eye to a greater extent than the left eye), and advanced cortical and nuclear cataracts bilaterally. Immersion A-scan biometry showed axial lengths of 20.1 mm OD and 21.83 mm OS. The anterior chamber depth was 1.77 mm OD and 1.91 mm OS. The mean corneal power was 38.00 D OD and 40.00 D OS.

The patient indicated that her left eye had better visual potential. Because the left eye also had slightly less challenging anterior segment anatomy, I decided to operate on it first. An obvious dilemma was selecting an IOL. Power calculations showed that her right eye required a 39.00 D lens and that a 31.00 D lens was indicated for her left eye. Because of her tiny corneal diameter, I was concerned that all of the available IOLs would be too large for her eyes. Oftentimes, however, eyes with this type of anatomy have a large crystalline lens, which might permit the insertion of a lens implant into the capsular bag. If, intraoperatively, the overall lens diameter appeared too large for the bag, I planned to remove both of the haptics and simply implant the optic alone in the capsule.

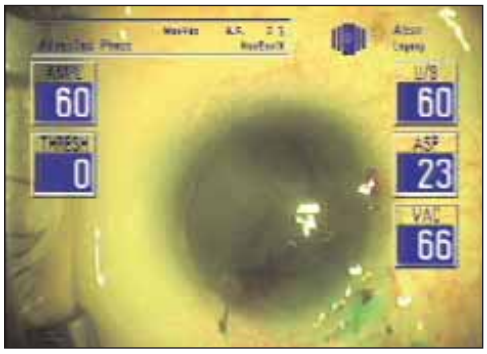

Figure 1. The anterior capsule has just been stained with indocyanine green.

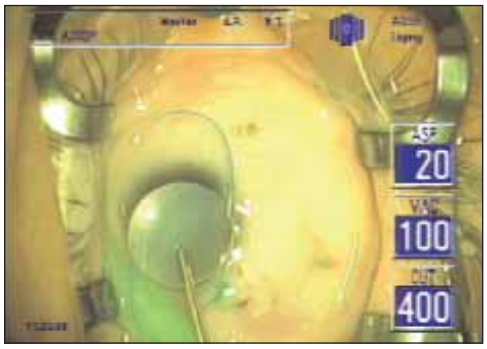

Figure 2. The corneal diameter is only slightly larger than the 5.5-mm optic.

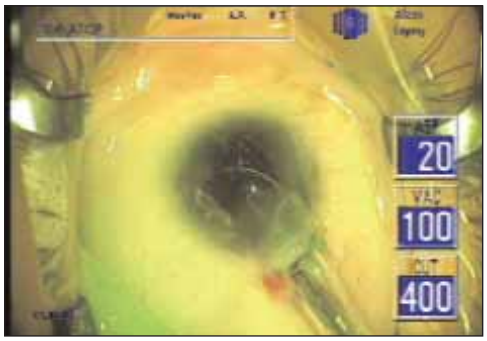

Figure 3. The surgeon injects a three-piece IOL.

SURGICAL COURSE

Because of the patient's nystagmus, I performed surgery with a peribulbar block. I carefully massaged the globe and orbit to ensure that the eye was soft. After I stained the anterior capsule with indocyanine green (Figure 1), the capsulorhexis went well. I performed gentle hydrodissection and began emulsifying the cataract.

After a brief period of sculpting, the nucleus fell into the vitreous. A small amount of vitreous was present, so I performed a lim-

ited vitrectomy and removed the remaining cortex. The anterior capsular rim was intact.

The dilemma, of course, was whether or not to implant the IOL. Looking at the size of the lens, it was obvious that the corneal diameter was barely larger than the IOL's 5.5-mm optic (Figure 2). Even with an intact capsular rim, was it safe to insert a three-piece IOL in the ciliary sulcus of this tiny anterior segment? I injected Healon GV (Advanced Medical Optics, Inc., Santa Ana, CA) underneath the iris, enlarged the wound to 4 mm, folded a 30.00 D MA30AC lens (5.5-mm optic; Alcon Laboratories, Inc., Fort Worth, TX), and gently injected it into the ciliary sulcus (Figure 3). Inserting the proximal haptic was challenging because of the small corneal diameter.

The lens appeared to be stable. I made various attempts to gently nudge the IOL, and it consistently returned to a stable central location. I sutured the scleral incision and completed the surgery. Because of travel-related issues, the pars plana vitrectomy was delayed for 2 weeks.

OUTCOME

The patient regained vision of 20/400 OS and was delighted with the outcome. Her right eye had a similar surgical course. Despite all precautions, again, the capsule ruptured early during phacoemulsification. Fortunately, there was no loss of lenticular tissue into the vitreous cavity. Because the corneal diameter in this eye was slightly less than 5 mm and there was zonular weakness, however, I did not feel that it was safe to insert an IOL into the sulcus of this eye. My decision was also influenced by the eye's poor visual potential due to greater obliteration of the macula and optic nerve by the coloboma than in her right eye.

CONCLUSION

My interpretation is that both posterior capsules were defective in some way, analogous perhaps to a posterior polar cataract. In retrospect, I would perform little if any hydrodissection because of this concern about capsular fragility. I would groove and split the nucleus and then viscodissect each portion into a position where it could be emulsified.

One year postoperatively, the patient's vision was stable, both eyes were quiet, and she was pleased with her outcome. Obviously, she and I are fortunate that her better-seeing eye tolerated two procedures to remove her cataract. ■

Douglas D. Koch, MD, is Professor of Ophthalmology and the Allen, Mosbacher, and Law Chair in Ophthalmology at Baylor College of Medicine in Houston. He is a consultant to Advanced Medical Optics, Inc., and Alcon Laboratories, Inc. Dr. Koch may be reached at (713) 798-6443; dkoch@bcm.tmc.edu.