

Repositioning and Fixation of the Subluxated Lens

An intraocular anchoring device may be used in conjunction with a capsular tension ring that is inserted before, together, or after placement of the capsular clip.

BY EHUD I. ASSIA, MD; YOKRAT TON, MD; AND ADI MICHAELI, MD

Mild cases of zonular dialysis are managed by implantation of a posterior chamber IOL, or preferably by using a capsular tension ring (CTR) to support the capsular equator at the area of missing or loose zonules. Moderate-to-severe subluxation of the crystalline lens is usually treated by complete lens removal and implantation of an IOL into the anterior chamber, or by suturing a posterior chamber IOL to the iris or sclera.

Alternatively, the capsular bag may be preserved and utilized for IOL fixation with the Cionni Modified Capsular Tension Ring (Morcher, Stuttgart, Germany) and suturing the ring to the scleral wall. This ring has an additional hook that extends perpendicular to the plane of the CTR and bends around the capsulorrhexis. A modified segment was designed by Ike K. Ahmed, MD, FRCSC (Ahmed Capsular Tension Segment; Morcher) to facilitate surgical maneuvers. A conventional CTR may also be directly sutured to the sclera; however, capsule penetration with a needle may result in extension of the tear to the posterior capsule.

We have designed a novel device, the Capsular Anchor (Hanita Lenses, Kibbutz Hanita, Israel), for securing the capsular bag to the scleral wall. This device is a one-plane intraocular implant made of PMMA. It works like a paper clip, holding the anterior capsule

between a central rod that is placed in front of the capsule, and the two lateral arms are inserted through the capsulorrhexis and placed behind the capsule. A hole at the base of the device is used as a temporary safety suture to facilitate manipulations and prevent falling posteriorly through the zonular defect (Figure 1). The fixation suture (ie, 9-0 or 10-0 prolene) may either be threaded through a second hole at the distal edge of the anchor (Figure 1), or it may simply encircle the central rod (Figure 2).

The Capsular Anchor may be used in conjunction with a CTR that is inserted before, together, or after placement of the capsular clip. These two devices serve separate functions: The anchor secures the lens capsule to the scleral wall, whereas the CTR maintains a circular configuration of the capsular equator. In cases of a very large zonular defect, the two devices may be implanted into the same eye.

We performed experimental studies on porcine and living rabbit eyes. Implantation was easily done either prior to or after lens material removal. The anterior capsulorrhexis remained intact, even after multiple procedures in the same eye. Histological studies in rabbit eyes 1 month after implantation demonstrated that the PMMA is well tolerated. There was no excessive inflammatory reaction in any of the eyes.

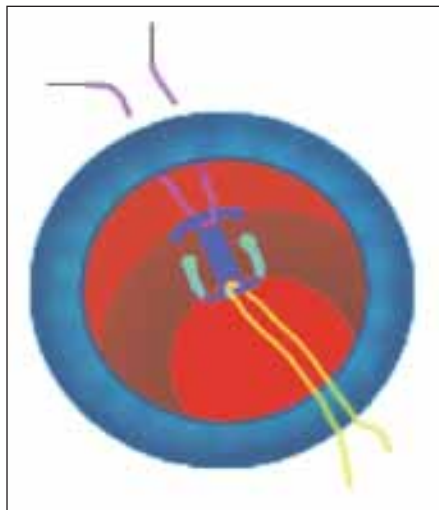


Figure 1. Illustration of the Capsular Anchor. The lateral arms are positioned behind the anterior capsule. This device is secured to the scleral wall by a 9-0 or 10-0 prolene suture (purple). The safety suture (yellow) is removed at the end of the procedure.

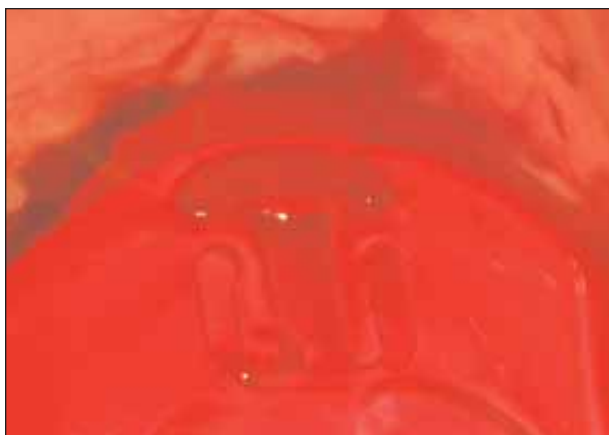


Figure 2. The Capsular Anchor was implanted into a rabbit eye prior to removal of lens material. The fixation suture encircles the central rod.

We also performed implantation of the Capsular Anchor in three patients with subluxated cataractous lenses. The first case was a 29-year-old man with a 5-hour dialysis of the inferior zonules following blunt trauma. The other two patients had 4- to 6-hour zonular dehiscence and long-standing subluxation secondary to Marfan's syndrome. In all cases, the anchor was inserted before lens removal, and phacoemulsification was performed after the lens was repositioned and secured to the scleral wall. CTRs were implanted in two eyes. In one case, an additional 3-hour dialysis of the superior temporal

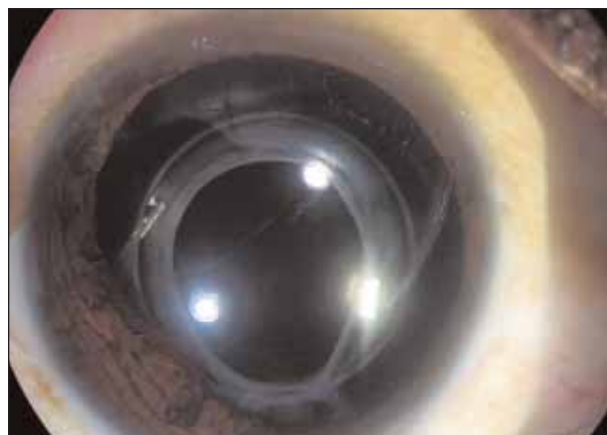

Figure 3. One month after implantation of the Capsular Anchor, in a patient with a traumatic subluxated lens. The blue-colored anchor is seen at 6 o'clock.

zonules was observed during surgery, and a second anchor was placed. One month postoperatively (Figure 3), the lenses are centered and stable, and vision significantly improved in all three cases.

One advantage of the Capsular Anchor is its simple placement of the device under direct visualization, even in cases with a large zonular dialysis. Unlike the modified CTRs, the anchor sustains not only the capsular equator, but mainly provides a wide contact with the anterior capsule and the margin of the capsulorrhexis. A CTR may optionally be used to maintain the round contour of the capsulorrhexis and the even tension at the equator. ■

This article was reprinted with permission from Cataract & Refractive Surgery Today Europe's May 2007 edition.

Ehud I. Assia, MD, is Associate Professor, Sackler Faculty of Medicine at Tel Aviv University, in Kfar Saba, Israel and Director, Department of Ophthalmology, at Meir Medical Center, in Kfar Saba, Israel. Professor Assia states that he is a paid consultant to Hanita Lenses, and he is the inventor of the Capsular Anchor. A study was supported by Hanita Lenses. He may be reached at tel: +972-9-7471527; fax: +972 9 7472427; Ehud.Assia@clalit.org.il; or assia@netvision.net.il.



Adi Michaeli, MD, is a Senior Physician in the Department of Ophthalmology, Soraski Medical Center, in Tel Aviv, Israel. Dr. Michaeli states that she has no financial interest in the products or companies mentioned. She may be reached at tel: +972 524 266508; fax: +972 9 7472427.

Yokrat Ton, MD, is a resident in the Department of Ophthalmology, Meir Medical Center, in Kfar Saba, Israel. Dr. Ton states that she has no financial interest in the products or companies mentioned. She may be reached at tel: +972 9 7471527; fax: +972 9 7472427.