

Single Radial Tear in the Rhexis

Experts discuss their surgical options for the management of this complication.

BY LISA ARBISSER, MD; DAVID F. CHANG, MD; UDAY DEVGAN, MD; AND BONNIE HENDERSON, MD

LISA ARBISSER, MD

Controlling the capsular dome and properly directing the shear vector by regrasping the edge noting any errant direction within 1 or 2 mm can prevent tears in almost every case. Rescuing an errant tear with centripetal force applied to the crux of the tear or completing a continuous curvilinear capsulorhexis (CCC) from the opposite direction almost always results in success. In the following paragraphs, I explain how I proceed in the rare case of an unavoidable radial tear.

The key in managing the tear is to “cement” the edges of the tear in close approximation to each other and avoid anterior-posterior displacement or rotational forces throughout the case.

After covering the tear with a dispersive ophthalmic viscosurgical device (OVD), causing the two edges of the tear to approximate into a semblance of the intact position, I pack the dispersive in place with cohesive OVD stabilizing the chamber and inspect it by retracting the iris to see the extent of the tear. Tears naturally stop at the zonular attachments just anterior to the equator where the interdigitating fibrillar elements fortify the delicate capsule. If the tear extends beyond the equator, I consider converting to an extracapsular technique without external pressure.

As long as the tear stops at the zonules, I will proceed with hydrodelineation without cortical cleaving hydrodissection. This process frees the nucleus from adhering to the bag, allowing nucleus rotation while maintaining an intact rim of epinucleus to hold the edges of the capsular tear in place, which discourages extension.

Next, I introduce the phaco tip with the bottle at a very low level to avoid the distension of the anterior chamber. In a myopic or vitrectomized eye, I place my chopper under the edge of the pupil and lift the iris off the anterior capsule before I step on the pedal, all of which prevents retropulsion of the iris. I slowly raise the bottle to the usual

height while in foot position one; flow is established in foot position two to prevent wound burn before I initiate ultrasound. I then perform my usual vertical chop technique. Dispersive OVD must be kept over the tear, however, and I replace it through the sideport if necessary. I advise surgeons to avoid capsule torque by using a slow and gentle, two-handed technique to turn the nucleus as required to access and remove it. Once I extract the endonucleus, I remove the epinucleus if it is free or left in place via I/A. I avoid chamber shallowing by replacing the chopper with a cannula filled with balanced salt solution and irrigating through the sideport while exchanging the phaco tip for the I/A tip.

I leave the cortex adjacent to the tear last. If it is recalcitrant, the surgeon can remove it manually with a dry technique under cohesive OVD. Once the bag is empty, tissue relationships are maintained with cohesive OVD. A one-piece acrylic IOL is most valuable in my opinion because it can be placed as a very compact package with haptics folded on the optic, it opens without pent-up energy, and its forces are evenly distributed when the haptics unfurl. I orient the haptics to avoid their escaping through the tear. The tackiness of the lens ensures that it will stay put, and the material is least likely to induce fibrosis with time. If I thought it were necessary to place a three-piece lens, I would use bimanual insertion without dialing the IOL into place, and I would consider a cut on the opposite side of the capsule if the forces of the haptics distorted the capsule tear. These steps are not necessary with a one-piece acrylic IOL. I irrigate the incision prior to OVD removal so there will be no shallowing of the chamber when I take out the I/A tip.

I would not attempt to clean the posterior chamber of the OVD. Carbonic anhydrase inhibitors immediately post-operatively prevent IOP spikes.

In my experience, these eyes generally benefit from the same rapid and uneventful recovery as a routine case.

DAVID F. CHANG, MD

If a peripheral capsulorhexis tear that cannot be rescued occurs, one must consider any other surgical comorbidities in deciding upon a surgical strategy. If there is a brunescient nucleus with weak zonules and a small pupil, converting to a manual extracapsular cataract procedure may be prudent. With a brunescient nucleus and normal zonules, making two additional anterior capsule relaxing incisions 120° away from each other may reduce the chance for a wraparound posterior capsular tear. If the nucleus is reasonably soft, I usually opt to complete the rest of the capsulorhexis from the opposite direction, prior to performing phaco in the presence of the single anterior capsular tear.

The maneuver most likely to extend a radial anterior capsular tear into the posterior capsule is the rotation of either the nucleus or IOL. When rotating either structure with a single instrument, we must first push it against the equator of the capsular bag to establish countertraction before applying torque. In my opinion and experience, this is the moment at which a wraparound tear occurs. Therefore, emulsifying the nucleus without rotating it is the key objective when proceeding with phacoemulsification in this situation. Gentle hydrodissection and hydrodelineation will not extend the anterior capsule tear, and in fact, these steps are critically important if one is to remove both the endonucleus and the epinucleus without rotation. The advantage of horizontal phaco chop is that one can initiate the first two chops/fractures without rotating the nucleus. The first fragment that is created is lifted out of the capsular bag. Especially if the endonucleus is small enough, the remaining hemi-sections can be elevated out of the bag with the phaco tip or the horizontal chopper.

Following cortical cleanup, the bag should be filled with an OVD. The capsulorhexis will take on a teardrop appearance because of the radial tear. One can easily inject a single-piece hydrophobic acrylic lens without applying any haptic force against the capsular equator. If this IOL design is not available, however, one could safely place a three-piece IOL inside the capsular bag. The key is to avoid forcefully decentering the optic and haptic toward the quadrant where the capsulorhexis is torn. One can accomplish this step by first directing the lead haptic into the anterior chamber rather than into the capsular bag. This technique allows me to rotate the trailing haptic into the bag while all decentering forces are applied to the anterior chamber angle. The second haptic is rotated into the bag by decentering the optic away from the capsulorhexis tear. The haptics are oriented 90° away from the location of the radial capsulorhexis tear. The advantage of completing phacoemulsification in the presence of a single capsulorhexis tear is that the intended IOL

can still be placed inside the capsular bag with a low risk of decentration. IOL placement into the ciliary sulcus is still an option, but it carries a higher risk of a refractive surprise or of postoperative decentration due to insufficient overall length.

UDAY DEVGAN, MD

When the capsulorhexis radializes, it can turn a routine case into a challenging situation with a higher risk of intraocular complications. If the capsulorhexis can be retrieved and completed in a continuous manner, surgeons can avoid these problems to successfully finish the case.

The main culprit in a radialized capsulorhexis is a flat anterior chamber and loss of viscoelastic. When there is posterior pressure, or if I distort the incision and allow egress of the viscoelastic, then the anterior lens capsule becomes more curved, and the rhexis tends to roll downhill toward the zonules. By reinflating the anterior chamber with viscoelastic, I can redden it and flatten the anterior lens capsule, thus facilitating capsulorhexis retrieval.

Although traditional force vectors can be used to lead the capsulorhexis back toward the center of the lens capsule, this maneuver is often difficult to perform through my sub-3-mm incisions. Use of paracentesis incisions, along with 23- or 25-gauge capsule forceps, can allow better instrument positioning to redirect the capsulorhexis centrally.

I owe a debt of gratitude to Brian Little, FCRS, FRCOphth, of London, for his technique of capsulorhexis retrieval, which is simple and yet very effective. It involves unfolding the capsule back and placing it flat (see *Retrieval Maneuver for CCC Tear-Out* on page 70). The next step is to pull backward and then curve in to redirect the tear centrally. Continue pulling centrally to bring the capsulorhexis edge back to the desired size. Now, a normal method of capsulorhexis creation can occur, and the procedure is finished (Figures 1 through 5).

I consider Dr. Little's method for capsulorhexis retrieval invaluable in many difficult situations. My recommendation to surgeons is that the next time they encounter a single radial tear, they should reinflate the anterior chamber with a cohesive viscoelastic and use Dr. Little's method.

BONNIE HENDERSON, MD

If the surgeon manages a small radial tear properly, creating a complete continuous capsule opening is still possible. The first important step is to determine why the radial tear occurred. Is the patient uncomfortable and squeezing the lid speculum? Is there posterior pressure?

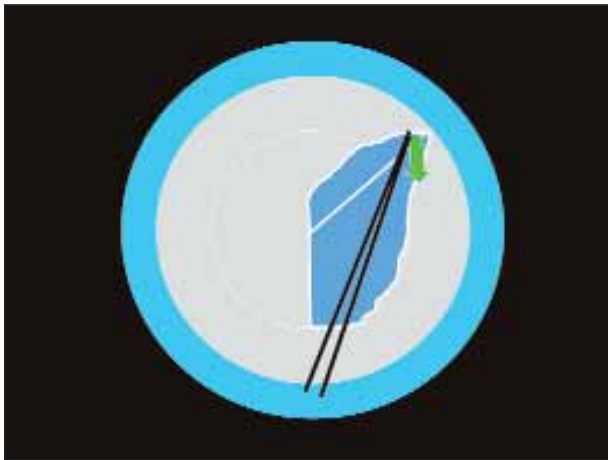


Figure 1. In step one of Dr. Little's method, the surgeon unfolds the capsule back and lays it down flat. The dashed line is the intended capsulorhexis.



Figure 2. In step two, the surgeon pulls backward and curves in to retrieve the capsulorhexis.



Figure 3. In step three, the surgeon pulls centrally to bring the edge of the capsulorhexis back to the desired size.



Figure 4. In step four, the surgeon resumes the usual method of creating a capsulorhexis.

After investigating and correcting any of the possible causes, as the next step, I inflate the anterior chamber with the proper amount and type of viscoelastic solution. The anterior chamber should be inflated enough to flatten the lens diaphragm without over inflating. I choose a type of viscoelastic based on my goal for the surgery. A dispersive, highly retentive form, such as chondroitin sulfate, will maintain the chamber better, whereas the cohesive form, such as sodium hyaluronate, allows for easier handling of the capsular flap.

Once the anterior chamber is deepened with viscoelastic solution, I grasp the middle of the inverted capsular flap rather than at the peripheral base of the tear. Grasping the flap at the peripheral base can cause the radial tear to extend further out to the periphery.



Figure 5. In step five, the surgeon finishes the capsulorhexis.

Cataract & Refractive Surgery Today's Submission Guidelines

Once I grasp the flap, I attempt to change the direction of the tear by gently pulling tangentially at first, then turning centrally toward the center of the pupil. It is important to keep the forceps in the same area slightly anterior to the plane of the anterior capsule and to not lift toward the cornea.

If the radial tear cannot be easily redirected, I do not continue. Instead, I leave the tear alone and use a cystatome to restart a capsulorhexis at the same beginning position and tear in the opposite direction to meet at the radial tear. I tear a larger capsule opening to incorporate the radial tear into the new capsule opening. When restarting the capsulorhexis, I ensure that the configuration of the new opening is heart-shaped. This arrangement allows me to craft a new flap without creating a fresh extension and, consequently, a point of weakness.

If I cannot incorporate the radial tear into the new capsulorhexis, and if the radial tear is still present, I carefully hydrodissect and hydrolineate the lens without prolapsing it out of the capsular bag. I remove the center nucleus using a chopping technique with minimal rotation of the lens. Once the center nucleus is removed, I carefully extract the outer epinuclear layer without causing undue stress on the capsule. In the presence of a radial tear, it is best to avoid over rotating the lens, which increases the chance of extending the small tear. When removing the epinucleus and cortex, I leave the area closest to the radial tear until last. Remember to strip the cortex toward the radial tear rather than away from the tear. ■

Lisa Arbisser, MD, is in private practice at Eye Surgeons Associates, PC in the Iowa and Illinois Quad Cities and is an Adjunct Clinical Associate Professor at University of Utah Moran Eye Center. She may be reached at (563) 323-2020; drlisa@arbisser.com.



David F. Chang, MD, is Clinical Professor at the University of California, San Francisco, and is in private practice in Los Altos, California. He may be reached at (650) 948-9123; dceye@earthlink.net.



Uday Devgan, MD, is in private practice at the Maloney Vision Institute in Los Angeles. Dr. Devgan is Chief of Ophthalmology at Olive View-UCLA Medical Center and Assistant Clinical Professor at the UCLA Jules Stein Eye Institute. He may be reached at (310) 208-3937; devgan@ucla.edu; www.maloneyvision.com.



Bonnie Henderson, MD, is an Assistant Clinical Professor at Harvard Medical School and a partner at Ophthalmic Consultants of Boston. She may be reached at (781) 487-2200 ext 3321; bahenderson@eyeboston.com.



If you would like to submit an article for publication in *Cataract & Refractive Surgery Today*, first send a written inquiry with an outline of your proposed article. E-mail inquiries to Gillian McDermott, Editor-in-Chief, at gmcdermott@bmctoday.com.

Editorial Policies. All articles published in *Cataract & Refractive Surgery Today* are reviewed by our Editor-in-Chief, who has sole discretion to accept, reject, or edit any article submitted for consideration. Articles are also read by a medical reviewer. All articles must be original in form and substance, and the author must warrant (1) that the article has not been published (and is not under consideration for publication) elsewhere and (2) that it does not contain material that infringes or violates any personal or intellectual property rights of others.

Format. We accept manuscripts in Microsoft Word for MacIntosh and PC. E-mail copy to gmcdermott@bmctoday.com.

Deadlines. All assigned work must be submitted by no later than the first of the month, 2 months prior to publication.

Length. Unless otherwise agreed to by our Editor-in-Chief, articles should be approximately 1,200 words in length.

Author Information. Please include (1) the complete article title, (2) the authors' full names, academic degrees, and affiliations, (3) all relevant financial disclosures, and (4) a name and address for correspondence, including fax number, telephone number, and e-mail address.

Artwork. Artwork may be submitted in digital or original form. Digital files may be sent in JPG, TIF, or EPS format; they should be approximately 300 dpi and 4 inches wide. If sending via email, JPGs are preferred. Original slides and photos are also acceptable. Please be sure to indicate the number and orientation of each image. If any artwork previously appeared elsewhere, it is the author's responsibility to obtain reprint permission from the original author and publisher.

References. The author is responsible for the accuracy of references. References should be typed at the end of the manuscript and listed in the order in which they appear in the text (not alphabetically). Unpublished data (papers submitted but not yet accepted for publication, personal communications) should be cited parenthetically in the text.

Questions? Contact Gillian McDermott, Editor-in-Chief, at (484) 581-1812; gmcdermott@bmctoday.com.

You may address correspondence to *Cataract & Refractive Surgery Today*, Bryn Mawr Communications LLC, 1008 Upper Gulph Road, Suite 200, Wayne, PA 19087.