Supracapsular Phacoemulsification for IFIS

Taking the iris' behavior out of the equation.

BY TAL RAVIV, MD

Intraoperative floppy iris syndrome (IFIS) covers a spectrum of intraoperative findings ranging from a prolapsing iris to progressive intraoperative miosis to severe iris/stromal atonicity with billowing. These irregularities may have a deleterious effect on cataract surgery by causing poor visibility, difficulty in controlling prolapse, and an entanglement of iris tissue by the phaco or other instruments. Numerous techniques and devices are available to maintain sufficient pupillary dilation and to help tame the misbehaving iris, but none is foolproof in my experience.

I became aware of my preferred approach for managing IFIS by chance and have used it since, mostly with success. For routine phacoemulsification in eyes without IFIS, I use one of two techniques—either supracapsular prolapse and tilt or vertical quick chop, depending on various factors. In general, soft nuclei are great for prolapsing, and hard nuclei do better with chopping. A supracapsular technique has worked particularly well for me in eyes with constricting pupils.

After learning of IFIS, I realized that many of the shrinking pupils I had encountered were due to tamsulosin (Flomax; Boehringer Ingelheim Pharmaceuticals, Inc., Ridgefield, CT). The beauty of supracapsular tilt for IFIS is that it effectively takes the constricting and billowing iris out of the equation. Using this technique and understanding the mechanics of iris prolapse can result in safer phacoemulsification in eyes with IFIS.

IRIS PROLAPSE

Presumably due to atrophy of the iris smooth muscle dilators, the irides in eyes with IFIS have minimal stromal rigidity and are swayed by the mildest fluid flow. Controlling severe iris prolapse to the phaco and sideport incisions is important for successful surgery.

Mechanically speaking, for the iris to prolapse, a pressure gradient must be present across the corneal wound. The iris will only prolapse when the pressure inside the anterior chamber is higher than the atmospheric pressure and when the closed system is disrupted by instrumentation. Although a relatively large gradient is needed for a normal iris, the slightest difference is enough to move the atrophic iris in a case of IFIS. Other factors such as the incision's construction and placement can usually keep the iris from prolapsing, but they may be less effective with the whimsical iris of IFIS.

Prolapse typically occurs during one of three stages in the procedure: the incision; capsulorhexis; or hydrodissection. If one can safely complete these important steps, prolapse becomes less likely, because the phaco sleeve seals the wound and re-creates a closed system. With this information in mind, the keys to preventing and managing iris prolapse are keeping a low anterior chamber pressure, allowing the equalization of pressure during the instrumentation of the wounds, and maintaining a closed system whenever possible.

With the rare exception of high posterior or intralenticular pressure, elevated pressures in the anterior chamber are typically iatrogenic from the overly vigorous, well-intentioned use of an ophthalmic viscosurgical device (OVD). In IFIS, the initial placement of an OVD should leave the eye relatively underfilled. That is especially true for the more dispersive OVDs such as Viscoat (Alcon Laboratories, Inc., Fort Worth, TX) or Healon 5 (Advanced Medical Optics, Inc., Santa Ana, CA). In most cases, any prolapse of the iris immediately after the incision's construction is due to overfilling with a viscoelastic. The problem can be remedied by removing viscoelastic through the firm depression of the posterior wound and the burping out of excess OVD. The

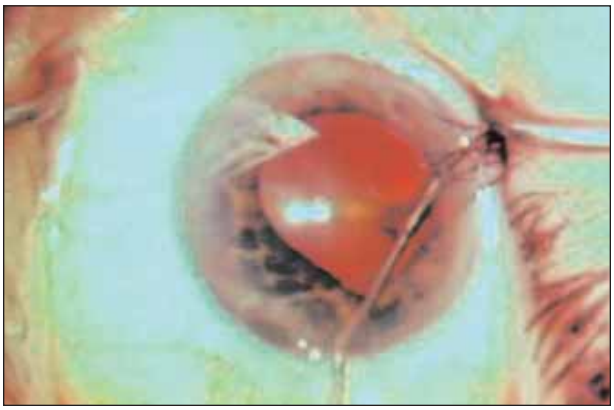

Figure 1. The surgeon performs hydrodissection diagonally to the side while simultaneously depressing the corneal wound and the proximal iris.

latter step is difficult with Viscoat or Healon 5, because they do not passively exit the eye and may need to be aspirated.

Hydrodissection adds fluid volume to the eye. In a closed system, that change results in a rapid increase in pressure. To prevent a pressure gradient, the amount of fluid entering the eye must equal the volume exiting it. The best way to ensure this balance is firmly to depress the posterior lip of the corneal incision and cause the wound to gape during hydrodissection (Figure 1). To avoid sweeping up the iris with the egressing viscoelastic, the surgeon should simultaneously direct the cannula diagonally across the wound and posteriorly over the proximal iris.

During a case of IFIS, the surgeon should initially address any prolapse by releasing fluid or viscoelastic (ie, pressure) from the anterior chamber. The ophthalmologist depresses either the paracentesis or the wound itself and causes it to gape. It is tempting to reach for more viscoelastic, but it is rarely necessary and may be counterproductive. Lowering the pressure in the anterior chamber will "pull" the iris back into the eye. A dispersive OVD should only be used after the chamber has been depressurized and then only in a limited quantity.

SUPRACAPSULAR TECHNIQUE

The technique of supracapsular prolapse and tilt involves phacoemulsifying the lens above the capsule. With a small pupil, the tilted, partially prolapsed nucleus lies in front of the iris as well.

There are different ways to perform supracapsular phacoemulsification. Some techniques involve flipping and inverting the entire nucleus, whereas others entail mechanically chopping the nucleus once it has prolapsed. I favor partially tilting the lens out of the capsular bag. In that way, just a small portion of the nucleus comes forward, which minimizes manipulation close to the corneal endothelium.

To prolapse a nucleus from its capsule, a sufficiently sized capsulorhexis is necessary. In most cases, a 5.5- to 6.0-mm capsulorhexis is adequate. Softer lenses can be prolapsed through smaller incisions, but hyperdense lenses need a larger opening. I usually try to keep the capsulorhexis smaller than 6.0mm to allow for complete overlap of the IOL's optic.

In IFIS, the initial size of the pupil is generally not as problematic as progressive intraoperative miosis. The construction of an adequate capsulorhexis can therefore occur with no more than viscodilation (Healon 5 works well here). Pupillary stretching, normally a useful technique for small pupils, is less effective in eyes with IFIS.

A right-hand–dominant surgeon should perform hydrodissection to the right side of the capsulorhexis with the simultaneous posterior displacement of the wound, proximal iris, and lens. This approach equalizes the pressure between the anterior chamber and atmosphere, controls the iris, and leads the lens to prolapse to the left side—with easy access through the sideport incision for instrumentation.

Once the lens has partially prolapsed out of the bag, the surgeon places a second instrument underneath the tilted pole to support it (Figure 2). Because the phacoemulsification takes place far from the capsule, capsular compromise is significantly limited. In addition, in IFIS, the second instrument or manipulator has a secondary role in keeping the iris away from the lens and phaco tip.

With the lens located safely above the iris and supported by the manipulator, the behavior of the constricting and flopping iris becomes irrelevant. The manipulator feeds and rotates the tilted portion of the lens to the phaco tip while the rest of the lens remains in the capsular bag. Using a moderate setting of flow and vacuum, the surgeon carousels the lens out of the bag to emulsify the nucleus as one large quadrant. In eyes with advanced IFIS,

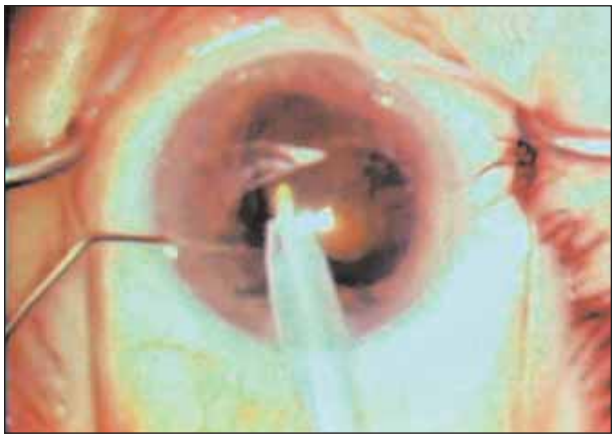

Figure 2. The second instrument supports the partially prolapsed lens above the constricting iris in an eye with IFIS.

where pupillary constriction would normally be severe, the prolapsed lens nucleus itself physically acts to maintain the pupil.

PRECAUTIONS

Surgeons should be extra cautious to avoid engaging the iris with the phaco tip. The second instrument is used to tamponade the iris while supporting the tilted lens. Furthermore, ophthalmologists should keep the phaco tip bevel up and apposed to the lens as much as possible. They should add a dispersive viscoelastic as needed to protect the endothelium.

Certainly, the supracapsular technique involves a learning curve. Efficiently manipulating a prolapsed lens in a sometimes tight anterior chamber, safely away from the endothelium, can be challenging. I recommend mastering the technique in an eye with a soft lens, well-dilated pupil, and deep anterior chamber before attempting a case of IFIS.

CONCLUSION

Most phaco strategies for eyes with IFIS involve controlling or retracting the iris to allow visualization of the eye and intracapsular manipulation. A supracapsular technique permits excellent visualization and intraocular manipulation without the use of accessory devices. By taking the action above the capsule, surgeons can mostly avoid the potentially treacherous, floppy iris of IFIS. ■

Tal Raviv, MD, is Assistant Professor of Ophthalmology, New York Medical College, Valhalla, New York; is an attending cornea and refractive surgeon at the New York Eye and Ear Infirmary; and is in private practice in New York City. He acknowledged no financial interest in the products or companies mentioned herein. Dr. Raviv may be reached at (212) 448-1005; tal.raviv@nylasereye.com.