

Propionibacterium Acnes Endophthalmitis

BY RICHARD E. BRAUNSTEIN, MD; NICK MAMALIS, MD; ROBERT KAUFER, MD;
AND DANIEL M. MILLER, MD, PhD

CASE PRESENTATION

A healthy 80-year-old female underwent what appeared to be uneventful cataract surgery in her left eye approximately 2 months ago. The surgeon placed a three-piece silicone IOL in the capsular bag. According to the patient, her visual acuity was fine for the first month, but it began to fluctuate and become hazy thereafter. She reported slight pain and redness in her eye as well as photophobia. Treatment with prednisolone q.i.d. reduced her pain but did not enhance her vision. After weeks of no improvement, the patient was referred to you for a consultation.

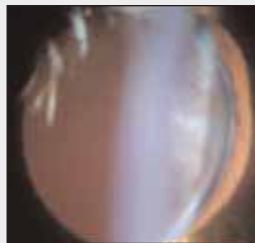


Figure 1. Although quiet, the patient's left eye has minor folds in Descemet's membrane and a capsular plaque.

On examination, the patient's visual acuity measured 20/80 with refraction. Her eye was quiet with minor Descemet's folds, and a capsular plaque located peripherally in the bag (360°) was more intense at the 3- and 9-o'clock positions (Figure 1). No vitreous inflammation or flare and only mild cell were evident. Macular edema was present on the retinal angiogram. An extraction of aqueous from the anterior chamber tested positive for *Propionibacterium acnes*. During that week, her visual acuity decreased to 20/100.

How would you manage this patient?

RICHARD E. BRAUNSTEIN, MD

This patient has a presentation consistent with postoperative *P. acnes* endophthalmitis. Caused by *P. acnes*, a gram-positive anaerobic bacillus, this condition presents as a white intracapsular plaque in the setting of decreased vision, conjunctival injection, intraocular inflammation with or without hypopyon, and keratic precipitates. The positive culture from the anterior segment of this patient solidifies the diagnosis.

P. acnes endophthalmitis has traditionally been treated via a stepwise approach. Many patients are successfully managed with topical corticosteroids. This patient may benefit from a more frequent regimen of topical corticosteroids in conjunction with a topical NSAID. If topical therapy is ineffective at controlling her inflammation and improving her vision, the literature supports an intravitreal injection of vancomycin 1 mg/0.1 mL.^{1,2} Reviews of treatment strategies for *P. acnes* endophthalmitis reported a 50% to 100% failure rate for an intraocular antibiotic injection as a primary treatment.^{1,2} When intraocular antibiotics fail to control the inflammation, a pars plana vitrectomy and either a partial or a total capsulectomy with or without IOL exchange is indicated. Data from the aforementioned studies demonstrated a recurrence rate of 14% to 44% in patients treated with partial capsulectomy and a recurrence rate of zero in patients treated with total capsulectomy and IOL removal.

For this culture-positive patient, I would recommend an intravitreal injection of vancomycin combined with frequent topical anti-inflammatory therapy. If this therapy failed to resolve the inflammation, I would attempt a pars plana vitrectomy with subtotal posterior capsulectomy, irrigation of the capsular bag, and a repeat intravitreal injection of vancomycin prior to performing a total capsulectomy and removing the IOL.

NICK MAMALIS, MD

This patient's history of inflammation associated with slight pain and redness, photophobia, and a partial response to prednisolone drops is consistent with a case of delayed-onset or chronic endophthalmitis. On Figure 1, the white plaque in the periphery of the capsule is consistent with *P. acnes*, which was confirmed by the testing of an extract from the patient's aqueous.

Treating *P. acnes* chronic endophthalmitis can be challenging, because the organism may be sequestered within the capsular bag or between the implant and the capsular bag, where it is difficult for antibiotics to reach sufficiently high levels to eradicate the bacterium. Such can be the

case even after a direct injection of an antibiotic into the lens capsular bag. Conservative treatment for *P. acnes* chronic endophthalmitis consists of the intravitreal injection of an antibiotic (vancomycin) combined with either pars plana vitrectomy or pars plana vitrectomy and partial posterior capsulectomy. Only approximately 50% of patients treated with this limited therapy, however, showed successful eradication of the infection. Two relatively large retrospective studies have confirmed these findings.^{1,2} Aldave et al reported on the experience of treating *P. acnes* endophthalmitis at Wills Eye Hospital in Philadelphia,² and Clark et al reported similar results for the treatment of patients at the Bascom Palmer Eye Institute in Miami and at the Cleveland Clinic.¹ Both studies confirmed that the limited surgical interventions described earlier eradicated infection in approximately half of the patients. The infection recurred in the remaining 50% of patients, who required a more aggressive surgical intervention, including total capsulectomy with the removal of the IOL combined with an injection of intravitreal antibiotics and pars plana vitrectomy. The complete removal of the lens capsular bag with the IOL cured this condition in all patients treated in this manner.

Given the findings of the aforementioned studies, this patient should undergo initial management with a limited pars plana vitrectomy and posterior capsulectomy followed by intravitreal vancomycin as well as an injection of 1 mg of vancomycin directly into the remaining capsular bag. If the signs of infection recur following this treatment, then the patient will have to undergo a complete removal of the lens capsular bag and IOL with an exchange for either an ACIOL or a sutured PCIOL without the presence of the lens capsular bag. This treatment is usually definitive, even if the more conservative treatment initially fails.

ROBERT KAUFER, MD

Fortunately, the complication presented in this case is infrequent. This patient's endophthalmitis must be managed for the macular inflammation to decrease. Otherwise, her visual acuity will be compromised.

My approach would be to explant the IOL and the entire capsular bag and then inject vancomycin into the anterior chamber. If the capsular plaque were localized in one place (in this case, it occupies 360°), one could consider partially removing the capsule. If vitreous were present in the anterior chamber, a vitrectomy would be indicated.

After administering sub-Tenon's anesthesia, I would inject an ophthalmic viscosurgical device into the anterior chamber to permit maneuvering of the lens. I have found it difficult to fold a silicone lens in the anterior chamber. I would therefore remove the IOL from the bag and cut it

into two pieces in order to extract it through a 3-mm incision. Next, I would remove the entire capsular bag while trying to preserve the hyaloid face and prevent vitreous from moving anteriorly. Once I had removed the lens and capsule, I would irrigate the anterior chamber thoroughly with vancomycin 1 mg/0.1 mL and instill a miotic agent.

Postoperatively, the posterior portion of the patient's eye should be tranquil. The macular inflammation should dissipate, and, with proper refractive correction, the patient's visual acuity should improve. I would wait 3 months for her refraction to stabilize, during which time the patient could use a contact lens. I would then proceed to implant an ACIOL. Another possibility would be to suture a PCIOL to the iris or sclera. Given the age of this patient, however, I would consider the ACIOL to be safer.

DANIEL M. MILLER, MD, PhD

The differential diagnosis in cases of delayed inflammation after cataract surgery includes noninfectious uveitis such as sarcoid- or HLA-B27-associated inflammation and infectious endophthalmitis. Causative organisms in delayed-onset endophthalmitis are *Staphylococcus epidermidis*, *Streptococcus viridans*, other coagulase-negative staphylococci, *P. acnes*, gram-negative rods, and—less commonly—*Candida* or *Aspergillus* in immunosuppressed or systemically ill patients.³

P. acnes is an anaerobic, gram-positive, pleomorphic bacillus that grows extremely slowly in anaerobic culture.⁴ The association of this organism with acute endophthalmitis after cataract surgery was first reported in 1978.⁵ Subsequently, *P. acnes* was shown to be a common cause of delayed-onset endophthalmitis after cataract surgery.^{6,7} The key clinical feature of delayed-onset endophthalmitis caused by *P. acnes* is a white, intracapsular plaque composed of sequestered organisms in the relatively anaerobic peripheral capsular bag. The diagnosis can be established by anaerobic culture and by polymerase chain reaction.^{4,5,8}

The management of *P. acnes* endophthalmitis is challenging. Intraocular inflammation can recur many months and years after a primary treatment modality, so clinicians should view with caution reports of successful intervention with relatively short follow-up periods. Topical and intraocular antibiotics alone typically do not eradicate the organism, because *P. acnes* may be encapsulated in the peripheral capsule.^{1,2,7} Two series of *P. acnes* endophthalmitis following cataract surgery provided information on the relative effectiveness of a variety of therapeutic interventions,^{1,2} as described in the comments of my coauthors.

The patient in this case has moderate-to-severe visual loss associated with her infection as well as a progressive course despite topical prednisolone. *P. acnes* endophthalmitis is likely to recur with less aggressive treatment, because the peripheral capsular plaque in 360° of the capsule eliminates the possibility that a focal capsulectomy would result in long-term success. Similarly, conservative measures such as irrigating the peripheral capsule with antibiotics and rotating/mobilizing the IOL within the capsule without capsulectomy are unlikely to treat all sequestered *P. acnes*. I would recommend a pars plana vitrectomy, a total capsulectomy, intravitreal vancomycin, and an IOL exchange in this case. ■

Section Editors Robert J. Cionni, MD; Michael E. Snyder, MD; and Robert H. Osher, MD, are cataract specialists at the Cincinnati Eye Institute in Ohio. They may be reached at (513) 984-5133; rcionni@cincinnatieye.com.

Richard E. Braunstein, MD, is Associate Professor of Clinical Ophthalmology at the Edward S. Harkness Eye Institute of Columbia University Medical Center in New York. Dr. Braunstein may be reached at (212) 326-3320; reb10@columbia.edu.



Robert Kauffer, MD, is Medical Director of the Kauffer Clínica de Ojos in Buenos Aires, Argentina. Dr. Kauffer may be reached at +54 1 1 4733 0560; rob@kauffer.com.



Nick Mamalis, MD, is Professor of Ophthalmology for the Moran Eye Center at the University of Utah in Salt Lake City. Dr. Mamalis may be reached at (801) 581-6586; nick.mamalis@hsc.utah.edu.



Daniel M. Miller, MD, PhD, is in private practice and is Voluntary Assistant Professor for the Department of Ophthalmology at the University of Cincinnati. Dr. Miller may be reached at (513) 984-5133; dmiller@cincinnatieye.com.



1. Clark WL, Kaiser PK, Flynn HW, et al. Treatment strategies and visual acuity outcomes in chronic postoperative *Propionibacterium acnes* endophthalmitis. *Ophthalmology*. 1999;106:1665-1670.
2. Aldave AJ, Stein JD, Deramo VA, et al. Treatment strategies for postoperative *Propionibacterium acnes* endophthalmitis. *Ophthalmology*. 1999;106:2395-2401.
3. Benz MS, Scott IU, Flynn HW, et al. Endophthalmitis isolates and antibiotic sensitivities: a 6 year review of culture proven cases. *Am J Ophthalmol*. 2004;137:38-42.
4. Hall GS, Pratt-Rippin K, Meisler DM, et al. Growth curve for *Propionibacterium acnes*. *Curr Eye Res*. 1994;13:465-466.
5. Forster RK, Zachary IG, Cottingham A Jr, Norton EWD. Further observations in the diagnosis, etiology, and treatment of endophthalmitis. *Trans Am Ophthalmol Soc*. 1978;73:221-230.
6. Meisler DM, Palestine AG, Vastine DW, et al. Chronic *Propionibacterium* endophthalmitis after extracapsular cataract extraction and intraocular lens implantation. *Am J Ophthalmol*. 1986;102:733-739.
7. Meisler DM, Mandelbaum S. *Propionibacterium*-associated endophthalmitis after extracapsular cataract extraction. Review of reported cases. *Ophthalmology*. 1989;96:54-61.
8. Lai J, Chen K, Lin Y, et al. *Propionibacterium acnes* DNA from an explanted intraocular lens detected by polymerase chain reaction in a case of chronic pseudophakic endophthalmitis. *J Cataract Refract Surg*. 2006;32:522-525.