

# Combined Phacoemulsification and ECP

Together, these procedures can treat cataract and medically controlled glaucoma.

BY STANLEY J. BERKE, MD

**E**ndoscopic cyclophotocoagulation (ECP) safely and effectively lowers IOP.<sup>1-4</sup> This is confirmed by several new, large, long-term studies summarized in this article. Because the surgeon visualizes the ciliary processes directly and can treat them precisely using diode laser energy, the problems of ocular pain, inflammation, hypotony, and visual loss associated with transscleral forms of cycloablation do not occur. The surgeon passes the 18-gauge endolaser probe through the limbus or pars plana to treat virtually any type of glaucoma, regardless of its etiology. I have found that ECP is particularly easy and well suited to lowering IOP and reducing patients' need for glaucoma medications when combined with phacoemulsification in cases of concurrent cataract and medically controlled glaucoma.

## HISTORICAL PERSPECTIVE

Using penetrating diathermy, cryotherapy, and, more recently, Nd:YAG and diode lasers, ophthalmologists have been performing transscleral cycloablation for many years. Traditionally, cycloablative procedures have been a last resort for eyes that have undergone multiple failed glaucoma procedures, such as trabeculectomies and the implantation of glaucoma drainage devices, and for eyes that are blind and painful or have very poor visual potential. The downgrade of the procedure was appropriate, because transscleral cycloablative procedures are unpredictable. Surgeons cannot visualize the tissue they are ablating, so over- or undertreatments are likely. The procedures are associated with many postoperative complications, including pain, inflammation, visual loss, and phthisis.

ECP is a gentler procedure in comparison to transscleral cycloablation, because surgeons can visualize the tips

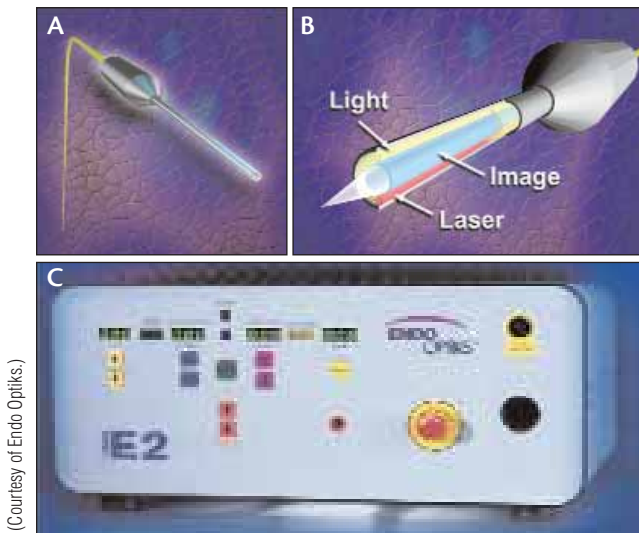
of the ciliary processes directly and treat them to achieve the desired effect on tissue. ECP does not cause undesirable collateral tissue damage and, therefore, does not cause the complications associated with transscleral cycloablation.<sup>5</sup> Surgeons can perform ECP in eyes with excellent visual potential. Because ophthalmologists can execute ECP with topical/intracameral anesthesia, it is well suited to patients who are monocular or are anticoagulated. In contrast, transscleral diode cyclophotocoagulation requires retrobulbar or peribulbar anesthesia.

## PATIENT SELECTION

Surgeons may consider ECP for any patient scheduled for cataract surgery who also requires a glaucoma procedure and is a poor candidate for filtration or drainage device surgery. Two examples are patients who have scarred conjunctivae or those whose contralateral eye has developed complications related to previous trabeculectomy or the bleb.<sup>6</sup>

ECP is preferable to filtration surgery in eyes where an ocular fistula is problematic, such as cases of elevated episcleral venous pressure, intraocular tumor, contact lens wear, or blepharitis.

ECP is much faster and easier than filtering surgery or drainage device surgery, and it involves fewer postoperative visits and additional treatments such as laser suture lysis, bleb needling, 5-fluorouracil injections, etc. ECP may therefore be a good choice for patients who are unable to make frequent postoperative visits or who are unable to cooperate for laser suture lysis, suture removal, or other manipulations of the bleb. Likewise, ECP is an alternative for patients who have had problems with glaucoma drainage devices such as extraocular muscle dysfunction, erosion of the tube or plate, or corneal decompensation.



(Courtesy of Endo Optiks.)

Figure 1. Laser endoscope probe (straight) (A, B). E2 Laser and Endoscopy System (C).

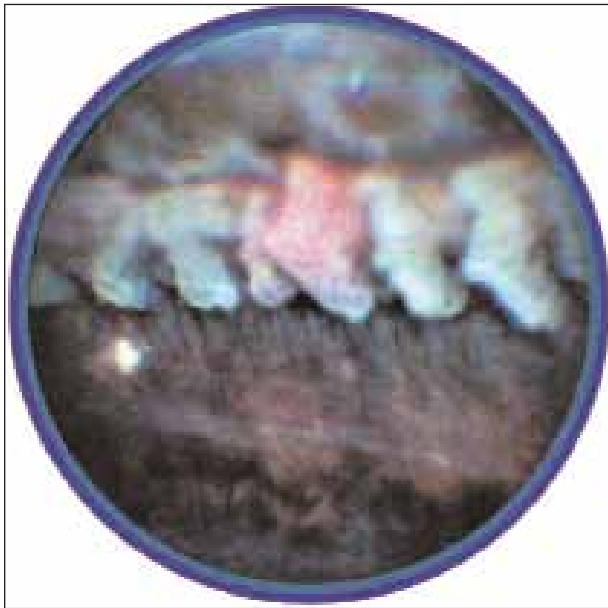


Figure 3. The treated ciliary process is shrunken and white.

## TECHNIQUES

The laser endoscope has three fiber groupings: the image; the light; and the laser guide. There is an 18-gauge endoprobe (Figure 1A and 1B) with a 110° field of view and a depth of focus ranging from 1 to 30 mm. The advantages of the laser endoscope's large diameter are the greater clarity provided by the image bundle and the panoramic field of view that it creates. This feature is especially helpful for the novice endoscopist, because the wide field of view permits simple orientation to the anatomy of the ciliary sulcus and ciliary processes.

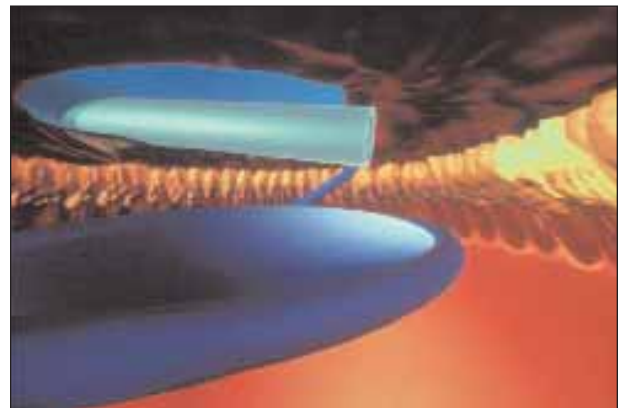


Figure 2. View from behind the iris of endolaser treatment to the ciliary processes with a PCIOL in place.



Figure 4. The area of the ECP treatment should be 200° to 360° (a 270° treatment is shown).

The laser endoscope connects to the console (Figure 1C) that contains all of the instruments used for endoscopy—a video camera, monitor, and recorder as well as a light source. Surgeons use a semiconductor diode laser tuned to the 810-nm wavelength. They place the console next to the surgical table and control the progress of the procedure by viewing the video monitor, rather than images through the operating microscope.

Surgeons can access the ciliary processes from an incision in the anterior segment in a phakic, pseudophakic, or aphakic eye. They may use a 1.5- to 2.0-mm incision in clear cornea or a scleral tunnel.

Surgeons perform their usual phaco procedure. They may perform ECP before or after inserting the PCIOL. Surgeons should introduce the viscoelastic over the capsular bag, posterior to the iris. This maneuver displaces the capsular bag backward and causes the iris to move forward, which provides a clear view of the ciliary processes

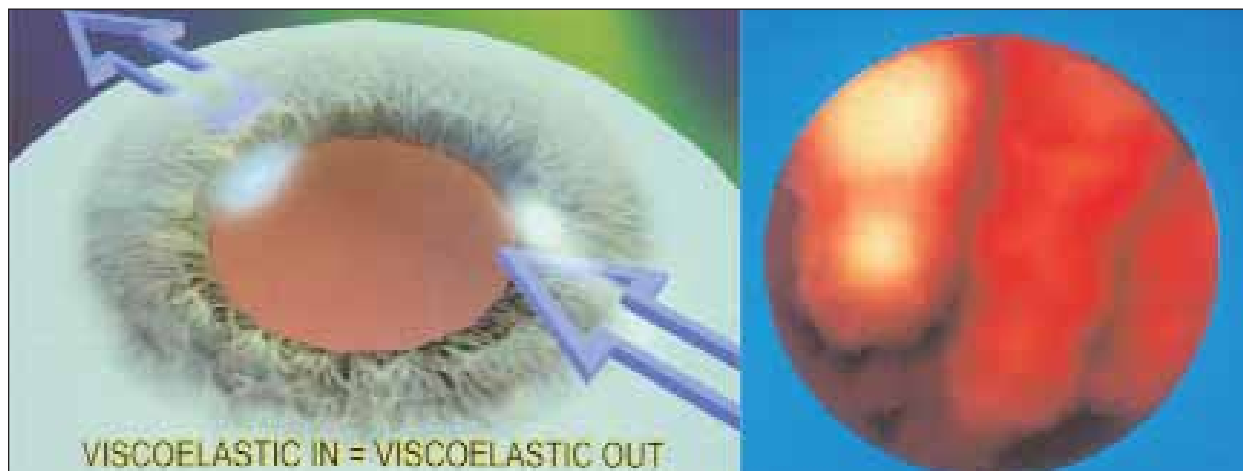

Figure 5. Surgeons should remove all viscoelastic from the eye at the end of the procedure.

(Figure 2). A clear corneal incision is preferable for combined ECP and cataract surgery, because it leaves the superior conjunctiva intact for future filtering surgery.

To me, perhaps the most outstanding quality of ECP is it allows me to deliver laser energy to the ciliary processes on demand in a highly titratable fashion, despite numerous anatomic impediments. The optimal effect on tissue when managing glaucoma is clear. The physical goals of treatment are to whiten the ciliary processes and cause visible shrinkage of the tissue (Figure 3). Surgeons should incorporate the entirety of each process into the treatment zone and, in general, treat 200° to 360° of the ciliary processes (Figure 4). They should avoid the formation of bubbles, pigmentary dispersion, audible popping, photocoagulation of nonciliary processes tissue, and the inclusion of prosthetic material in the treatment zone. At the conclusion of surgery, it is important to remove all of the sodium hyaluronate from the eye to prevent a postoperative increase in IOP (Figure 5). See *Tips for Performing ECP*.

### MY EXPERIENCE

ECP permits visualization and photocoagulation of the ciliary processes in essentially any patient, despite the presence of corneal opacification, a miotic pupil, or previous glaucoma surgery.<sup>1</sup> Laser endoscopy benefits from the advantages of directly viewing the ciliary processes and photocoagulation yet avoids the complications associated with transscleral cyclodestruction.

Since 1998, my partners and I have performed more than 1,000 combined phaco/ECP procedures, primarily in patients with medically controlled glaucoma. We analyzed our first 25 consecutive cases with 1-year follow-up.<sup>2</sup> Treating 180° of the ciliary processes resulted in a mean decrease in IOP of 15% (from 20.2 to 17.2 mm Hg) and a

### TIPS FOR PERFORMING ECP

- Treat at least 200° of the ciliary processes in every case. Treating 270° to 360° is preferable with a second clear corneal incision or with a curved endolaser probe. Hypotony does not occur.
- Treat the entire ciliary process from top to bottom as well as the space between ciliary processes (the “valleys” between the “hills”).
- Be advised that treating eyes with pseudoexfoliation is more difficult, because the ciliary processes are smaller and covered with white pseudoexfoliative material. It may be necessary to increase the power of the endolaser or to move the tip of the endolaser probe closer to the targeted tissue.
- Take the time to remove all of the viscoelastic from inside the eye, including in front of and behind the iris as well as behind the IOL.
- Monitor patients for pressure spikes within the first 24 hours postoperatively. Increases in pressure may occur as early as 3 hours after surgery. Treat all patients with a topical glaucoma medication and oral Diamox Sequels 500 mg (Duramed Pharmaceuticals, Inc., Cincinnati, OH) immediately postoperatively.
- Taper the patient’s glaucoma medications if his IOP is lower than his target pressure. It may take 4 to 6 weeks to realize the full effect of the procedure.
- Treat patients with your standard postoperative regimen for cataract surgery of topical steroids and NSAIDs q.i.d. for 2 to 3 weeks. Treat patients with increased inflammation more intensively with anti-inflammatory agents for a longer period of time.

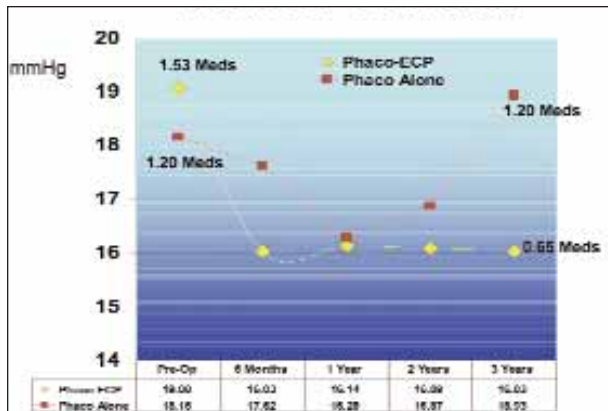


Figure 6. The long-term results of phacoemulsification/ECP.

68% reduction in glaucoma medications (from 1.6 to 0.5). There was no visual loss or significant adverse sequelae postoperatively.

We recently analyzed our long-term phaco/ECP results.<sup>3</sup> We compared 626 consecutive eyes treated with phacoemulsification/ECP with a similar cohort of 81 eyes that underwent phacoemulsification alone. The follow-up period ranged from 6 months to 5.5 years, with a mean follow-up time of 3.2 years. In the phaco/ECP group, the mean IOP decreased by 3.4 mm Hg, from 19.1 to 15.7 mm Hg. In the control group, the mean IOP increased 0.7 mm Hg, from 18.2 to 18.9 mm Hg. More significantly, the number of preoperative glaucoma medications decreased from a mean of 1.53 to 0.65 at the end of the follow-up period in the phaco/ECP group but remained unchanged from a mean of 1.20 in the phaco group (Figure 6). There were no serious complications in either cohort, and the rate of cystoid macular edema (CME) was similar in both groups (less than 1%). Another study involving more than 1,000 eyes confirmed our results and showed no difference in angiographic CME between eyes that underwent phacoemulsification/ECP versus phacoemulsification alone (approximately 2% in both groups).<sup>4</sup>

I still perform phacoemulsification alone and combined phacoemulsification/trabeculectomy on many glaucoma patients undergoing cataract surgery. In an average month, I complete 40 cataract surgeries in which approximately 10 eyes have glaucoma. Of those, I perform phacoemulsification alone on 25%, phacoemulsification/ECP on 50%, and phacoemulsification/trabeculectomy on 25%. Although I evaluate every patient individually, my general rule of thumb is as follows.<sup>7-9</sup>

If a patient with a cataract has mild, well-controlled glaucoma on a single, well-tolerated glaucoma medication, I perform phacoemulsification alone and implant an IOL through a temporal clear corneal incision. This procedure preserves the superior conjunctiva in case

trabeculectomy is needed in the future. If the patient has moderate glaucoma and uses two or more glaucoma medications, I perform phacoemulsification/ECP through a clear corneal incision in an effort to lower his IOP and reduce or eliminate his use of glaucoma medications. Last, if a patient has advanced glaucomatous cupping and visual field loss on maximum medical therapy (two or more medications), I perform a phacotrabeculectomy with intraoperative mitomycin C.

## CONCLUSION

ECP should not be considered the same as transscleral forms of cycloablation, which are “blind” procedures that can cause a lot of collateral tissue damage and that can result in an over- or undertreatment of the tips of the ciliary processes.

ECP may not be indicated for some cataract surgery patients with very mild or very advanced glaucoma. However, it is a safe and effective addition to our armamentarium to treat glaucoma patients with moderate disease on two or more medications. ■

*Stanley J. Berke, MD, is Associate Clinical Professor of Ophthalmology and Visual Sciences, Albert Einstein College of Medicine, in New York; Chief, Glaucoma Service, Nassau University Medical Center, East Meadow, New York; and Founding Partner, Ophthalmic Consultants of Long Island, Lynbrook, New York. He acknowledged no financial interest in the products or companies mentioned herein. Dr. Berke may be reached at (516) 593-7709; sberke@ocli.net.*



1. Uram M. Ophthalmic laser microendoscope endophotocoagulation. *Ophthalmology*. 1992;99:1829-1832.
2. Berke SJ, Cohen AJ, Sturm RT, et al. Endoscopic cyclophotocoagulation (ECP) and phacoemulsification in the treatment of medically controlled open angle glaucoma. *J Glaucoma*. 2000;9:129.
3. Berke SJ, Sturm RT, Caronia RM, et al. Phacoemulsification combined with endoscopic cyclophotocoagulation (ECP) in the management of cataract and medically controlled glaucoma: a large, long term study. Paper presented at the AGS Annual Meeting; March 6 2006; Charleston, SC, and at the AAO Annual Meeting; November 14, 2006; Las Vegas, NV.
4. The ECP Study Group. Comparison of phaco/ECP to phaco alone in 1,000 glaucoma patients: a randomized, prospective study including fluorescein angiography in all patients in both groups. Paper presented at: The 2002 ASCRS Symposium on Cataract, IOL and Refractive Surgery; June 6, 2002; Philadelphia, PA.
5. Trevisani MG, Allingham RR, Shields MB. Histologic comparison of contact transscleral diode cyclophotocoagulation and endoscopic diode cyclophotocoagulation. *Invest Ophthalmol and Vis Sci*. 1995;36:4.
6. Berke SJ, Bellows AR, Shingleton BJ, et al. Chronic and recurrent choroidal detachment following glaucoma filtering surgery. *Ophthalmology*. 1987;94:154-162.
7. Berke SJ. How ECP compares to other procedures. *Ophthalmology Management*. <http://www.ophtmanagement.com/article.aspx?article=&loc=archive/2003/march/medtronic/0303medtronic4.htm>. Accessed June 23, 2008.
8. Berke SJ. Cyclodestruction as a treatment for glaucoma. *American Academy of Ophthalmology Focal Points*. 2004;22:10:11-14.
9. Berke SJ. Combining ECP and cataract surgery. *Glaucoma Today*. September 2005;3:5:27-28.