

Traumatic Iris Prolapse

BY DEEPINDER K. DHALIWAL, MD; MARTIN S. ARKIN, MD, PhD; R. BRUCE WALLACE III, MD;
THOMAS A. OETTING, MS, MD; AND ANITA NEVYAS-WALLACE, MD

CASE PRESENTATION

A 67-year-old male with Usher's syndrome (retinitis pigmentosa and sensorineural hearing loss) underwent uncomplicated cataract surgery 2 months ago. He received a toric IOL and achieved a visual acuity of 20/30. While doing chores on his farm, he stepped on a rake that he did not see lying on the ground due to his limited peripheral vision. Its handle struck him in his operated left eye, causing a marked reduction in his vision. An examination revealed that iris material had prolapsed through the clear corneal wound.

The patient is referred to you for management. Figure 1 shows the current appearance of the globe. The anterior chamber is deep. The iris has obviously prolapsed out of the wound. Please describe how you would proceed and comment on any pharmacologic therapy you think would be appropriate.

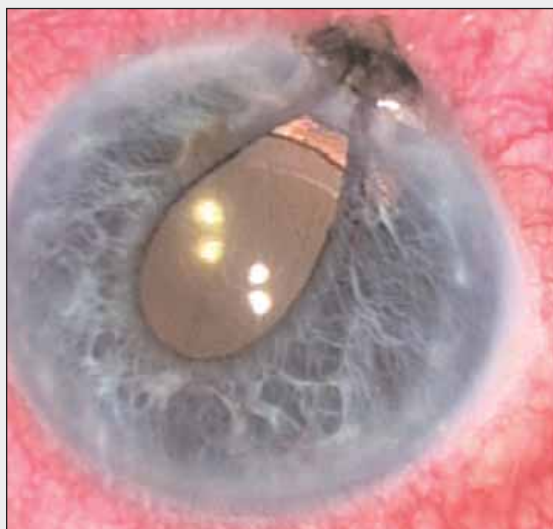


Figure 1. A photograph of the anterior segment of the injured eye discloses iris prolapse.

DEEPINDER K. DHALIWAL, MD

There is no obvious evidence of infection (absence of keratitis and hypopyon) or subluxation of the lens (the toric IOL appears to be well centered in the capsular bag). I would take the patient to the OR as soon as possible. After draping the eye and inserting the lid speculum, I would culture the prolapsed iris and ocular surface extensively (including fungal plates due to his history of a farm-related injury). I would then copiously irrigate the ocular surface with balanced salt solution. I would check the wound for vitreous prolapse, because the zonules tend to be weak in patients with Usher's syndrome. After gently scraping the prolapsed iris with a Weck-Cel sponge (Medtronic ENT, Jacksonville, FL) to remove any epithelium or debris, I would reposition it from a separate stab incision as long as it did not appear devitalized.

The next step is critical. I would use a sharp blade to scrape away all epithelium present along the internal aspect of the wound. A fistulous tract forms quickly in these situations. I would place sutures to ensure a watertight wound. If the incision did not seal after the placement of several sutures, I would remove them and scrape the wound again. I would then instill Miochol-E (Novartis Ophthalmics, Inc., Duluth, GA). No peaking of the pupil should be visible.

In terms of pharmacologic therapy, I would administer topical antibiotics pre- and postoperatively. I would also prescribe a postoperative NSAID and steroid, because patients with Usher's syndrome have a higher incidence of cystoid macular edema (CME). In addition, I would instruct the patient to use systemic antibiotics for 1 week.

MARTIN S. ARKIN, MD, PhD

The first thing that this patient needs is a complete examination. I would consider obtaining an orbital CT scan if there were a possibility of an intraocular foreign body. Although gentle dilation might worsen the pro-

lapse slightly, I think that it would be worthwhile to see the condition of the zonules and the orientation of the IOL. The alignment marks of the toric lens should be readily visible if there is not excessive corneal edema or hemorrhage. This information would help me to determine whether the implant must be rotated, either during the repair of the ruptured wound or at a later date. Although the surgeon could attempt to perform a manifest refraction and keratometry, I predict that the ruptured wound would make these measurements almost useless.

The priority in this case is closing the eye in order to prevent endophthalmitis. Retinitis pigmentosa is sometimes associated with loose zonules, so I would look for this condition during the preoperative examination. At the time of surgery, my first step would be to decompress the eye. I would create a side incision as a paracentesis, insert a cannula into the anterior chamber, and remove some aqueous. Decompressing the anterior chamber often makes it much easier to reposition a prolapsed iris within the eye. Probably the easiest approach would be to insert a thick viscoelastic such as Viscoat (Alcon Laboratories, Inc., Fort Worth, TX) over the iris in that area. If this step were unsuccessful, then a cyclodialysis spatula, inserted through the paracentesis and brought in sideways toward the wound, could be used to tease the iris back into position. I would attempt to avoid losing any iris tissue.

Viscoelastic would help to keep the iris inside the eye while I closed the wound with 10–0 nylon sutures. Initially, I would be most concerned with making sure the wound did not leak, although tight sutures would temporarily cause some astigmatism. These sutures would also likely delay my assessment of the postoperative corneal astigmatism. Once the wound was well healed, I could selectively adjust the sutures by removing the tightest ones first and eventually removing all of the sutures within 2 to 3 months. At that point, I would re-evaluate the patient and determine whether the toric IOL required rotation. In my experience, once the AcrySof Toric IOL (Alcon Laboratories, Inc.) is in place, it rotates very little, unless the trauma is severe. The treatment of possible zonular loss might involve transscleral or iris-fixation sutures for the IOL, an IOL exchange, the placement of a capsular tension ring, or a possible vitrectomy.

In terms of postoperative management, I would consider the possibility of anaerobic infection. Initially, I would treat the patient's eye with a topical fourth-generation fluoroquinolone antibiotic. If there were any sign of excessive postoperative inflammation, however, I would consider administering systemic clindamycin or metronidazole.

R. BRUCE WALLACE III, MD

This unfortunate patient deserves surgical repair as soon as possible to restore the excellent visual result he enjoyed and avoid further complications such as CME and endophthalmitis. I would immediately start topical antibiotic prophylaxis with Vigamox (Alcon Laboratories, Inc.) and avoid preserved medications until the fistula was repaired. Surgical preparation would include povidone-iodine 5%, but only to the skin of the eyelid. After gently draping the eye and placing a self-retaining lid speculum, I would establish (or re-establish) a side-port incision and allow for the anterior chamber to become shallow gradually, whereupon I would administer an intracameral injection of Miochol-E and reposition the iris with a blunt cyclodialysis spatula. (Sometimes, sharp dissection is required to free the iris from the surrounding conjunctiva before the surgeon can reposition the iris.)

Interrupted 10–0 nylon sutures, likely two, would help to ensure the incision's closure. Postoperative topical medications would include Zymar, Pred Forte, and Acular LS (all from Allergan, Inc., Irvine, CA).

I used this technique on a patient who had recently received a Crystalens implant (Bausch & Lomb, Rochester, NY). Ocular trauma had caused the iris to prolapse. Now, 3 weeks postoperatively, his surgical result is excellent.

THOMAS A. OETTING, MS, MD

I think some of the prolapsed iris is salvageable. At the very least, the iris sphincter looks viable. My goal would be to reposition the iris, suture the corneal wound, and prevent infection.

While waiting for the OR, I would place an intravenous line and start a fluoroquinolone.¹ During the examination, I would ensure that the patient has no pseudophacodonesis, because patients with retinitis pigmentosa tend to have weak zonules,² and the additional insult of the trauma may have led to a loose IOL. I would probably try topical anesthesia using only unpreserved 1% lidocaine; if the patient were unsteady or communication were too difficult due to his hearing loss, however, I would use general anesthesia.

The key to repositioning the prolapsed iris is first to place a paracentesis at approximately the 3-o'clock position. Through the paracentesis, I would remove fluid from the eye and relieve pressure that is pushing the iris out of the wound. Then, I would use unpreserved 1% lidocaine with a cannula to reposition the iris. Iris tissue that is not viable will often wash away. If I needed more force for the repositioning, I would inject a viscous dispersive viscoelastic through the wound to

push the iris in after lowering the pressure behind the iris using the paracentesis. After positioning the iris, I would probably use one or two subincisional iris hooks to hold the frayed iris during automated I/A in order to remove any residual debris. I would close the incision with two interrupted 10-0 nylon sutures before removing the hooks.

Following the procedure, the superior iris would be translucent. Although the sphincter might be intact, a significant amount of stroma is surely missing. I think that there is a good chance, however, that no additional repair of the iris would be required, because the retinitis pigmentosa might limit the patient's photophobia and the defect would be located superiorly under the eyelid. I would prescribe a topical and an oral fluoroquinolone³ as well as topical 1% prednisolone acetate, and I would watch the patient closely for signs of infection. After 1 week, I would start him on an NSAID and have him continue using it for several weeks to prevent CME.⁴

ANITA NEVYAS-WALLACE, MD

A dirty wound with the presentation of vitreous is a setup for endophthalmitis, particularly if more than 24 hours have elapsed between the injury and its repair. General anesthesia is necessary to avoid further expression of the ocular contents. If the prolapse occurred 36 hours ago or less and the tissue does not look ischemic, it may be repositioned. Otherwise, it should be cut flush with the corneal surface. Later in the procedure, the surgeon may suture the ends together using a 10-0 polypropylene suture, although an iris defect under the upper eyelid probably would not cause symptoms or cosmetic difficulty in a 67-year-old man.

If the tissue is to be repositioned, it should first be cultured, then rinsed with balanced salt solution, irrigated generously with Vigamox drops, and allowed to soak for a few minutes. These drops have been shown to be safe for intracameral use,⁵⁻⁷ and the drug covers many organisms found in soil, including *Bacillus cereus* and *Staphylococcus*.

In order to maintain the anterior chamber, I would use a new or a diamond blade to create two paracenteses before attempting to reposition or excise the entrapped tissue. I would excise the prolapsed knuckle of vitreous flush with the corneal surface. After removing a bit of aqueous to avoid further prolapse, I would instill Miochol-E through a sideport incision. Next, using viscoelastic, I would reposition the iris; aided by an iris sweep through a sideport incision, I would coax the iris into place without placing undue pressure on the iris root. I would then intracamerally instill unpreserved Triescence (triamcinolone; Alcon Laboratories, Inc.),

diluted 1:1 with balanced salt solution, to disclose any vitreous in the chamber and then sweep the wound again. Placing viscoelastic just inside the wound would make the iris slightly concave and prevent the chamber from becoming shallow. I would then suture the wound.

Next, I would perform a pars plana vitrectomy with infusion through one of the sideports. I would again instill Triescence intracamerally and sweep the wound area to verify the absence of vitreous. Before closing, I would inject vancomycin 1 mg/0.1 mL, ceftazidime 2.25 mg/0.01 mL, and voriconazole (Vfend; Pfizer Inc., New York, NY) 100 µg through the pars plana incision. I would aspirate any remaining viscoelastic with bimanual I/A and instill intracameral moxifloxacin (1:5 dilution with balanced salt solution) and voriconazole (10 µg/0.1 mL) in the anterior chamber.

Postoperatively, the patient should be hospitalized, given intravenous cefazolin 1 g q6h for 72 hours, followed by moxifloxacin (Avelox; Bayer Corporation, West Haven, CT) 400 mg p.o. once daily for 7 days. I would follow him closely and watch carefully for infection. I would administer a tetanus and diphtheria booster shot if his last were more than 7 years ago.

The injury and its repair will change the patient's corneal astigmatism so that the axis at which his toric IOL is oriented may no longer be optimal. Attempting to rotate the toric IOL, even with viscodissection, risks detaching the capsular bag. An evaluation of astigmatism should wait for several months after the sutures' removal to be sure that no fungal infection or epithelial ingrowth has developed. Then, if the amount of astigmatism were high, I would consider performing astigmatic keratotomy or LASIK. ■

Section Editors Robert J. Cionni, MD; Michael E. Snyder, MD; and Robert H. Osher, MD, are cataract specialists at the Cincinnati Eye Institute in Ohio. They may be reached at (513) 984-5133; msnyder@cincinnatieye.com.

Martin S. Arkin, MD, PhD, is in private practice with Bay Eye Associates in Traverse City, Michigan. He acknowledged no financial interest in the products or companies mentioned herein. Dr. Arkin may be reached at (231) 935-0630; ar897@tcnet.org.

Deepinder K. Dhaliwal, MD, is Associate Professor of Ophthalmology, University of Pittsburgh School of Medicine; Director, Cornea and Refractive Surgery Services, UPMC Eye Center; Director and Founder, Center for Integrative Eye Care, UPMC Eye Center; and Director, UPMC Laser/Aesthetic Center. She acknowledged no financial interest in the products or companies mentioned herein.



Dr. Dhaliwal may be reached at (412) 647-2214; dhaliwaldk@upmc.edu.

Anita Nevyas-Wallace, MD, is in private practice with Nevyas Eye Associates in Bala Cynwyd, Pennsylvania. She acknowledged no financial interest in the products or companies mentioned herein. Dr. Nevyas-Wallace may be reached at (610) 668-2777; anevyaswallace@nevyas.com.



Thomas A. Oetting, MS, MD, is Clinical Professor at the University of Iowa in Iowa City. He acknowledged no financial interest in the products or companies mentioned herein. Dr. Oetting may be reached at (319) 384-9958; thomas-oetting@uiowa.edu.



R. Bruce Wallace III, MD, is Medical Director of Wallace Eye Surgery in Alexandria, Louisiana. Dr. Wallace is also Clinical Professor of Ophthalmology at the LSU School of Medicine and Assistant Clinical Professor of Ophthalmology at the Tulane School of Medicine, both in New Orleans. He is a consultant to Advanced Medical Optics, Inc.; Allergan, Inc.; and Bausch & Lomb. Dr. Wallace may be reached at (318) 448-4488; rbw123@aol.com.



1. Fiscella RG, Shapiro MJ, Solomon MJ, et al. Ofloxacin penetration into the eye after intravenous and topical administration. *Retina*. 1997;17:535-539.
2. Hayashi K, Hayashi H, Matsuo K, et al. Anterior capsule contraction and intraocular lens dislocation after implant surgery in eyes with retinitis pigmentosa. *Ophthalmology*. 1998;105:1239-1243.
3. Donnenfeld ED, Perry HD, Snyder RW, et al. Intracorneal, aqueous humor, and vitreous humor penetration of topical and oral ofloxacin. *Arch Ophthalmol*. 1997;115:173-176.
4. Henderson BA, Kim JY, Arment CS, et al. Clinical pseudophakic cystoid macular edema. Risk factors for development and duration after treatment. *J Cataract Refract Surg*. 2007;33:1550-1558.
5. Espiritu CRG, Caparas VL, Bolinao JG. Safety of prophylactic intracameral moxifloxacin 0.5% ophthalmic solution in cataract surgery patients. *J Cataract Refract Surg*. 2007;33:63-68.
6. Arshinoff SA. Intracameral moxifloxacin for antibacterial prophylaxis in cataract surgery. *Cataract & Refractive Surgery Today*. April 2007. Available at http://www.crstoday.com/PDF%20Articles/0407/CRST0407_12.php. Accessed June 20, 2008.
7. Mah FS. Which topical fluoroquinolone to use? Paper presented at: The AAO Annual Meeting; October 25, 2004; New Orleans, LA.