

Tips and OVD Tricks for Difficult Cataract Surgery Cases

Surgeons can use OVDs almost universally to create and preserve surgical spaces and to protect endothelial cells.

BY STEVE A. ARSHINOFF, MD, FRCSC

Ophthalmic viscosurgical devices (OVDs) are the primary surgical tools that ophthalmologists use to create the physical environments they need to perform the controlled, delicate intraocular maneuvers of modern phacoemulsification and IOL implantation as well as other intraocular surgeries. Since the introduction of Healon (Abbott Medical Optics Inc., Santa Ana, CA) in 1979,¹ OVDs have proliferated and become essential in anterior segment surgery for creating space, balancing pressure in the anterior and posterior chambers, stabilizing tissue, and protecting the corneal endothelial cells from surgical trauma, free radicals, and other surgical hazards.² Understanding the factors that we need to control during surgery and the properties of the available OVDs allows us to perform at a higher level, which can make complex procedures seem simple to observers. Before addressing specific spatial problems in difficult situations, this article reviews some of the important characteristics of OVDs. Our goal as surgeons should be to create an environment in which we can execute a given task easily, rather than to learn to perform heroically in a complicated and uncontrolled environment.

THE CLASSIFICATION OF OVDs

The classification of OVDs is essential to the ability to develop surgical techniques that optimize their use. Initially, all cataract viscosurgery involved Healon. When Viscoat (Alcon Laboratories, Inc., Fort Worth, TX) and hydroxypropylmethylcellulose became available a few years later, we surgeons divided ourselves into two groups: those of us who preferred to work with higher-viscosity cohesives (Healon and later agents) and those who preferred lower-viscosity dispersives (Viscoat or hydroxypropylmethylcellulose).

A functional classification should be based upon the

physical properties that are most essential in cataract surgery. In 1989, I devised the first OVD classification scheme based upon zero-shear viscosity, but I noted the high correlation between viscosity and the relative degree of cohesion or dispersion of available OVDs (Table 1).^{3,4} Higher-viscosity cohesives were excellent at creating space and sustaining pressure, whereas lower-viscosity dispersives were capable of partitioning spaces and coating tissues (Table 2). Each group was poor at performing the tasks at which the other group excelled, and thus we were forced to choose an OVD based upon which type of complication we felt was most likely to occur in a particular case. The appearance of viscoadaptives in 1998 required an expansion of the scheme (Table 1).⁵ The most recent major new OVD, DisCoVisc (Alcon Laboratories, Inc.), does not fit into even this expanded classification because of the intentional dissociation of the historic OVD correlation between zero-shear viscosity and cohesion in DisCoVisc. Thus, a more major modification of the scheme from a simple list to a two-dimensional table was necessary (Table 3).⁶

THE SOFT SHELL AND ULTIMATE SOFT SHELL TECHNIQUES

Choosing the proper OVD for complicated cases

The dilemma of needing to choose between OVD groups, each of which was inadequate for the full cataract procedure, led to the development of the viscoelastic dispersive-cohesive soft shell technique, and, the ultimate soft shell technique. More physical effects can be achieved with two fluids of disparate properties than with any single fluid.^{7,8} Attempts to design a single OVD that can replace multiple OVD techniques (eg, DisCoVisc) continue. Despite the success of such agents for routine cataract cases, a single OVD can never replace the ability in complex cases of the

TABLE 1. THE CLASSIFICATION OF OVDs PRIOR TO 2005 (ARSHINOFF 1989 TO 2000)

Year of Class Appearance	OVD Class	Zero-Shear Viscosity (mPa.s)	
		Range	Approximation
1998	Viscoadaptives	7-24 x 10 ⁶	10 millions
1989	Higher viscosity cohesives • Super viscous cohesives • Viscous cohesives	1-5 x 10 ⁶ 10 ⁵ - 10 ⁶	millions 100 thousands
	Lower viscosity dispersives • Medium viscosity dispersives • Very low viscosity dispersives	10 ⁴ - 10 ⁵ 10 ³ - 10 ⁴	10 thousands thousands

Abbreviations: mPa.s, millipascal seconds

Note: The primary parameter used for classification is zero-shear viscosity.

soft shell/ultimate soft shell techniques to create rheologically different, adjacent physical spaces that do not mix. Consequently, OVD techniques designed to deal with complications are usually variations of the soft shell/ultimate soft shell techniques. This article describes a few.

Fuchs' Endothelial Dystrophy

Cases of Fuchs' endothelial dystrophy are best handled with variations on the soft shell or ultimate soft shell technique. The idea is first to place a mound of dispersive OVD on the surface of the crystalline lens and then to pressurize the dispersive OVD up against the corneal endothelium by injecting a cohesive (soft shell technique) or viscoadaptive (ultimate soft shell technique) OVD below it. In the ultimate soft shell technique, another layer of balanced salt solution is injected below the viscoadaptive agent. During the ensuing phacoemulsification, the ultimate soft shell technique preserves the viscoadaptive layer, whereas the cohesive OVD is likely aspirated out of the anterior chamber with the soft shell technique. At the end of the case, the residual viscoadaptive or cohesive OVD is removed, and the dispersive agent is left in the eye as a thin layer coating the endothelium for protection.

It is advisable, when intentionally leaving some OVD in the eye, to treat the patient with an ocular hypotensive postoperatively. I use 0.2% carbachol drops because of their long duration of action and because cholinergics are the most effective agents to prevent postoperative IOP spikes. I have my hospital dilute 2% drops to 0.2% to prevent the patients from developing an aching brow or eye.

Zonular Deficiency

At the earliest sign of instability, a capsular tension ring, Cionni Capsular Tension ring or Ahmed Capsular Tension Segment (the last two from FCI Ophthalmics, Marshfield Hills, MA [the Ahmed Capsular Tension Segment is not available in the United States]) is inserted. In addition, the surgeon can insert a Grieshaber hook (Grieshaber & Company AG, Schaffhausen, Switzerland) or other hooks as

TABLE 2. OPTIMAL USES OF COHESIVE AND DISPERSIVE OVDs (VISCOADAPTIVES DESIGNED TO DO ALL)

Higher-Viscosity Cohesives	Lower-Viscosity Dispersives
<ul style="list-style-type: none"> • Create space • Induce and sustain pressure 	<ul style="list-style-type: none"> • Prolong retention • Partition spaces

needed. Because there is no vitreous in the anterior chamber, these cases usually progress relatively routinely, with the capsular tension ring and OVDs in place.

Intraoperative Floppy Iris Syndrome

The soft shell/ultimate soft shell technique for intraoperative floppy iris syndrome (IFIS) is performed as follows (Figure 1). The OVD technique for IFIS is a combination of the soft shell and the ultimate soft shell technique.

Preoperative study

First, determine if you are dealing with IFIS or some other cause of small pupils (eg, atrophy of the iris, a pupillary fibrotic ring, a history of miotic use). Test the patient's pupillary dilation 1 week prior to surgery to confirm the presence and severity of expected IFIS by instilling Mydracryl (tropicamide) 1% gtts x2, 5 minutes apart, and Mydrin (phenylephrine) 2.5% gtts x1 (both products from Alcon Laboratories, Inc.).

After 20 minutes, measure the pupils. If they are larger than 6.5 mm, and especially if the patient has brown eyes, surgery should not be particularly difficult. Inject up to 0.5 mL (but usually 0.1 mL is sufficient) of intracameral phenylephrine (5.0 mL balanced salt solution mixed with 0.3 mL [all] of a phenylephrine 10% mimim in a 6.0-mL syringe [dilutes to 0.57%]) into the anterior chamber after the intracameral injection of Xylocaine (Astrazeneca LP, Wilmington, DE) through the sideport incision. Then, wait 1 minute before making the main incision and starting surgery. You can use the soft shell/ultimate soft shell technique for IFIS,

TABLE 3. NEW CLASSIFICATION OF OVDs, 2005, MODIFIED AND UPDATED TO 2009

Zero-Shear Viscosity Range (mPa.s)	Cohesive OVDs Cohesion/Dispersion Index ≥ 30 (%asp/mm Hg)	Dispersive OVDs Cohesion/Dispersion Index < 30 (%asp/mm Hg)
7-18 x 10 ⁶ (ten millions)	I. Viscoadaptives • Healon5 • iVisc (MicroVisc) Phaco • BD MultiVisc	
1-5 x 10 ⁶ (millions) 10 ⁵ -10 ⁶ (hundred thousands)	II. Higher-viscosity cohesives A. Super-viscous cohesives • Healon GV • iVisc (MicroVisc, HyVisc) Plus • BD Visc, AcriHylon Plus B. Viscous cohesives • Healon • iVisc (MicroVisc, HyVisc) • Eyefill HC • Ophthalin Plus • Provisc • Opegan Hi • Viscorneal • Biolon Prime • Biolon • Amvisc Plus • Amvisc • Ophthalin • Eyefill SC	II. Higher-viscosity dispersives A. Super-viscous dispersives • none B. Viscous dispersives • DisCoVisc
10 ⁴ - 10 ⁵ (ten thousands)	III. Lower-viscosity cohesives A. Medium-viscosity cohesives • none	III. Lower-viscosity dispersives A. Medium-viscosity dispersives • Viscoat • Biovisc • Endogel • Rayvisc • Opelead

Abbreviation: mPa.s, millipascal seconds

Note: Healon, Healon5, Healon GV, Biovisc (not available in the United States), and Healon D, Abbott Medical Optics Inc. (Santa Ana, CA); iVisc and Icell (neither available in the United States), iMed Pharma Inc. (Quebec, Canada); MicroVisc and HyVisc (neither available in the United States), Bohus Biotech (Stromstand, Sweden); BD MultiVisc and BD Visc (neither available in the United States), BD (Franklin Lakes, NJ); AcriHylon Plus, Ophthalin Plus, Ophthalin, and Endogel (none available in the United States), Carl Zeiss Meditec, Inc. (Dublin, CA); Eyefill HC, and Eyefill SC, Eyefill HD (none available in the United States), Croma Pharma (Korneuburg, Austria); DisCoVisc, Provisc, Viscoat, and Cellugel, Alcon Laboratories, Inc. (Fort Worth, TX); Opegan Hi and Opegan (neither available in the United States), Seikagaku Corporation (Tokyo, Japan); Biolon Prime and Biolon, Biotechnology Technology General (Kiryat Malachi, Israel); Amvisc Plus, Amvisc, and Occucoat, Bausch & Lomb (Rochester, NY); Rayvisc (not available in the United States), Rayner Intraocular Lenses Limited (East Sussex, the United Kingdom); Opelead (not available in the United States), Shiseido Co., Ltd. (Tokyo, Japan).

but you generally do not need to reduce the flow rate below 25 mL/min, when the dilating test pupil is 6.5 mm or greater.

You may encounter some difficulty if, at the preoperative dilation test, the patient's pupils dilate only to about 6 mm. This can be overcome when performing the soft shell/ultimate soft shell technique for IFIS, in addition to using intracameral phenylephrine, by reducing the flow rate to 20 mL/min.

If the pupils dilate to less than 5.5 mm, and especially if the patient has blue irides, you should use intracameral phenylephrine and the soft shell/ultimate soft shell technique for IFIS with very low flow rates of around 15 mL/min. A Malyugin ring (MicroSurgical Technology, Redmond, WA) may also be needed.

IFIS soft shell/ultimate soft shell technique

Fill the anterior chamber through the phaco incision to approximately 40% with a dispersive viscoelastic such as Viscoat (Alcon Laboratories, Inc.). It is important to inject the OVD around the periphery to cover the peripheral iris. Then, inject Healon5 (Abbott Medical Optics Inc.) onto the surface of the anterior lens capsule in the center of the anterior chamber and push the dispersive viscoelastic upward and outward until dilation stops. It is important to ensure that the boundary of the Healon5/Viscoat is near the pupillary margin. It will later serve as a fracture boundary and help to keep the iris stable and the pupil dilated throughout surgery. At this point, the anterior chamber should be more than 90% full of OVD, and the eye should feel slightly firm. Next, slowly inject balanced salt solution or the nonpreserved lidocaine or phenylephrine under the layer of Healon5 on the surface of the lens capsule with the cannula's aperture placed at the very center of the lens' surface. This step elevates the OVD soft shell off the lens'

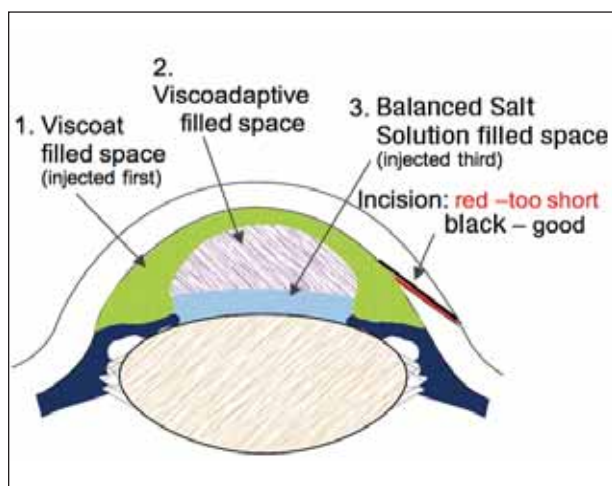


Figure 1. Modified soft shell/ultimate soft shell technique.

surface and creates an aqueous pocket on the lens' surface where the surgery will take place.⁹

Capsulorhexis with IFIS soft shell/ultimate soft shell technique

Performing a routine capsulorhexis using a bent needle will keep the anterior chamber OVD structure intact better than a forceps capsulorhexis. Begin at the center of the lens and keep the diameter of the capsulorhexis smaller than the pupil's diameter. This will confine fluid flow to an area smaller than the pupil and prevent turbulence from affecting the iris and the Viscoat layer, which would permit the pupil to flop and constrict.

Hydrodissection with IFIS soft shell/ultimate soft shell technique

I like to perform hydrodissection, in these cases, with balanced salt solution in a 10-mL syringe with a 27-gauge hockey stick cannula and to use small, short pulses of balanced salt solution. As long as you carefully execute the aforementioned steps and correctly place the balanced salt solution cannula, the balanced salt solution can circulate around the lens and flow out of the eye, beneath the OVD shell, without disturbing it. If the OVD shell is disrupted and some of the OVD is lost, you can reinject Healon5 followed by balanced salt solution below the shell again. The Viscoat placed peripherally is rarely washed out inadvertently, but the central Healon5 may be.

Low-flow, low-chatter phacoemulsification is needed for IFIS soft shell/ultimate soft shell technique

When using the Infiniti Vision System (Alcon Laboratories, Inc.) or a similar peristaltic pump, adjust the machine's settings to a flow rate of 20 mL/min or less,

vacuum of 300 mm Hg or less, and a bottle height that is 75 to 80 cm above the patient's eye, with continuous variable pulse or torsional mode. Perform the procedure using phaco slice-and-separate or a similar chopping technique. It is important to keep the phaco tip at or below the capsulorhexis and to confine fluid flow to the capsular bag.¹⁰ All work is done in the capsular bag, and phacoemulsification is only engaged when the phaco tip is in the bag and in contact with a piece of nucleus. Avoid unnecessary irrigation of the anterior chamber.

When you follow the steps described, measure the pupils preoperatively, and create tight incisions and a stable OVD environment, IFIS cases become relatively routine procedures.

SUMMARY

We ophthalmic surgeons use OVDs almost universally in cataract surgery to create and preserve surgical spaces and protect endothelial cells. The soft shell and ultimate soft shell techniques will enable you to vary your surgical environment in response to the unique physical problems you face. When the unexpected occurs, I find it helpful to pause for a few seconds, think, and then reach for whichever OVD, or OVDs will be of most help in creating a physical environment in which what I can easily achieve what I want to do. ■

Steve A. Arshinoff, MD, FRCSC, is a partner at York Finch Eye Associates, Humber River Regional Hospital, and is on the academic staffs of the University of Toronto and McMaster University, Hamilton, Ontario, Canada. He is a paid consultant to Alcon Laboratories, Inc. Dr. Arshinoff may be reached at (416) 745-6969; jfix2is@sympatico.ca.



- Balazs EA, inventor; Biotrics, Inc. assignee. Ultrapure hyaluronic acid and the use thereof. US patent 4 141 973 1973. October 17, 1979.
- Arshinoff SA. Dispersive and cohesive viscoelastic materials in phacoemulsification. *Ophthalmic Pract.* 1995;13:98-104.
- Arshinoff SA. Comparative physical properties of ophthalmic viscoelastic materials. *Ophthalmic Pract.* 1989;7(1):16-19, 36-37.
- Arshinoff S. Dispersive and cohesive viscoelastic materials in phacoemulsification. In: Solomon L, ed. *Ophthalmic Advisory Panel at the ASCRS*. Montreal: Medicopea International; 1995:28-40.
- Arshinoff Steve A. Healon5 entering selected countries in Europe. *Ocular Surgery News, International Ed.* September; 1998: 9:9:11-12.
- Arshinoff SA, Jafari M. A new classification of ophthalmic viscosurgical devices (OVDs) - 2005. *J Cataract Refract Surg.* 2005;31(11):2167-2171.
- Arshinoff SA. Dispersive-cohesive viscoelastic soft shell technique. *J Cataract Refract Surg.* 1999;25(2):167-173.
- Arshinoff SA. Using BSS with viscoadaptives in the ultimate soft-shell technique. *J Cataract Refract Surg.* 2002;28(9):1509-1514.
- Arshinoff SA. Modified SST-USST for tamsulosin-associated intraocular floppy-iris syndrome. *J Cataract Refract Surg.* 2006;32:559-561.
- Arshinoff SA. Phaco slice and separate. *J Cataract Refract Surg.* 1999;25(4):474-478.